



MAKING THE WORLD A HEALTHIER PLACE

THE SWISS BIOHEALTH CONCEPT

SWISS 
BIOHEALTH
ACADEMY

Table of contents

CHANGES IN OUR ENVIRONMENT	6	Cooling with HILOTHERM	33
Chronic diseases	6	Concomitant homeopathic medication	33
Multiple sclerosis, ALS, autoimmune diseases	6	Prophylactics given to patients before discharge	34
Beginning of a change in mindset	6	Continuing treatment	34
EMF as a cause of disease	7	Principles of detoxification	34
		The factor of diet	34
THE CORRELATION BETWEEN DENTAL STRESS AND CHRONIC DISEASES	10	The factor of EMF	34
The vegetative nervous system	10	The factor of sleep	34
Sympathetic and parasympathetic nervous system	10	The factor of bite height	35
Heart rate variability (HRV)	10	Further principles	35
The importance of regulation	11	Continuation of micronutrient therapy	35
Forms of stress	11	Orthopedics as a factor with gait patterns and shoe insoles	36
The importance of chronic inflammation	12	Intestinal rehabilitation and amino acids	36
		Specific detoxification therapies	37
MECHANISMS OF ORAL DISTURBANCES	14	IMPORTANCE OF MICRONUTRIENTS IN DENTISTRY	38
Silent inflammation	14	Vitamin D:	38
Autoimmune diseases	14	Occurrence and supply	38
Retrograde axonal transport	14	Physiological significance	38
		Pathophysiology	40
ALLERGIES AND INTOLERANCES	14	Preventive and therapeutic significance	40
ROOT CANAL TREATMENTS	14	Importance of vitamin D in sports medicine	40
The meridian system and its correlation with organs	16	Importance for dentistry	42
The concept of oral interference fields	16	Laboratory test status and recommended intake	42
Interference field diagnostics	17	Safety	42
		Cofactors	42
CLINICAL DIAGNOSTICS	19	Importance for the	43
Test injection with 1% procaine	19	THE SWISS BIOHEALTH CONCEPT	43
OroTox® test	19	Vitamin K2	44
		Occurrence	44
EFFECTS OF DIFFERENT MATERIALS ON THE BODY	22	Physiological significance	44
Amalgam	22	Pathophysiology	44
Dental metal alloys	23	Preventive and therapeutic significance	44
Titanium implants or screws	23	Importance for dentistry	44
		Recommended intake	44
BIOLOGICAL DENTISTRY	26	Safety and interactions	44
Biological dentistry versus holistic/natural dentistry	27	Cofactors	44
THE SWISS BIOHEALTH CONCEPT	27	Importance for the	44
The ALL IN ONE CONCEPT and MY BIOHEALTH WEEK	27	THE SWISS BIOHEALTH CONCEPT	44
Medical history and findings	29	Vitamin C	45
DVT	29	Occurrence	45
LDL and vitamin D3 analysis	29	Physiological significance	45
Additional lab tests	29	Pathophysiology	45
Titanium intolerance tests	29	Preventive and therapeutic significance	45
Neural therapy simulation	29	Importance for dentistry	45
Pre- and post-treatment principles	29	Recommended intake	45
The micronutrient protocol	32	Safety, side effects and contraindications	46
Importance of micronutrient balancing with periodontitis	32	Cofactors	46
Single shots	32	Importance for the	46
Infusion therapy	33	THE SWISS BIOHEALTH CONCEPT	46
		Magnesium	46
		Occurrence	46
		Physiological significance	46

Pathophysiology	46	Basic principles of wound healing	66
Preventive and therapeutic significance	46	Soft tissue management	66
Importance for dentistry	47	Bone metabolism and healing	66
Laboratory test status and recommended intake	47	Bone Growing Implants	66
Safety, side effects and contraindications	47	Bone management criteria	67
Cofactors	47	Systemic conditions	67
Importance for the	47	Local conditions	67
THE SWISS BIOHEALTH CONCEPT	47	Special techniques and aspects	69
Omega-3 fatty acids	47	Brushing technique	69
Occurrence	47	Apical mattress suture	70
Pathophysiology	47	Bone replacement	70
Preventive and therapeutic significance	47	The dome technique	71
Importance for dentistry	48	Open Healing Protocol according to Prof. Ghanaati	71
Laboratory status, recommended intake and safety	48	BISS – Bone Implant Stabilization System	71
Importance for THE SWISS BIOHEALTH CONCEPT	48	AIM (anatomical implantation method)	71
Vitamin A	48	RAP (rebuild aesthetics procedure)	72
Occurrence	48	Final prosthetic restoration	72
Physiological significance	48	Dental hygiene	73
Pathophysiology	48		
Preventive and therapeutic significance	48	SCIENTIFIC EVIDENCE SUBSTANTIATING THE THE	
Importance for dentistry	48	SWISS BIOHEALTH CONCEPT	74
Recommended intake	49		
Safety	49	REFERENCES AND SOURCES	78
Importance for the	49		
THE SWISS BIOHEALTH CONCEPT	49		
RESTORATION	50		
Restoration sequence	50		
Amalgam removal/metal restoration	51		
Detoxification protocol	51		
Amalgam removal using six-fold protection.	51		
Removal of metal inlays, metal crowns and metal bridges	52		
Explantation of titanium implants	52		
Wisdom teeth and FDOJ (formerly NICO)	52		
Empty jaw sections	55		
Ankylotic root-canal-treated teeth	55		
Extraction of root-treated teeth	56		
Extraction	56		
Root infraction	56		
Densotomy	56		
Separate removal of a cyst or a foreign body in the area of the tooth tip	57		
Ozone treatment	57		
Blood concentrates (A-PRF and I-PRF)	57		
PRF blood concentrates	58		
A-PRF = Advanced Platelet Rich Fibrin	58		
Injectable Platelet Rich Fibrin (I-PRF)	58		
Ceramic implantology	59		
Zirconia hi-tech ceramic	60		
Immediate implant placement	62		
Delayed immediate implant placement	64		
Late implant placement	64		
Bone augmentation measures	64		

Dr. Karl Ulrich Volz



- 1991 Youngest dentist in Germany to establish a purely private practice
- 1991 Dissertation on "Amalgam invasion in teeth"
- 1992 First fully ceramic inlays
- 1996 Certification as dentist specializing in naturopathy
- 1998 Certification as dentist specializing in implantology
- 1998 First fully ceramic zirconia crowns
- 1999 Establishment of Bodensee Zahnklinik AG and Bodensee Dentaltechnik AG
- 2000 Establishment of Medical Masters AG
- 2000 Development of the first zirconia implants
- 2001 Establishment of Tagesklinik Konstanz
- 2003 Establishment of Z-Systems GmbH
- 2004 First CE certification for a ceramic implant
- 2004 - 2012 Development of the first SDS2.0 two-part reversibly screw-retained ceramic implant
- 2006 Insertion of first implants with ultrasound using polylactide welding
- 2007 Establishment of SDS SWISS DENTAL SOLUTIONS AG
- 2008 Development of sonic weld membrane welding for GBR technology
- 2012 - 2014 Development of the SDS1.1 hybrid implant
- 2014 Chairman of the International Society of Metal-Free Implantology (ISMI)
- 2014 Development of the Dr. Karl Ulrich Volz SCC Short Cut Concept
- 2015 Formulation of the Dr. Volz Biological Dentistry concept
- 2016 Establishment of the SWISS BIOHEALTH CLINIC and development of the ALL IN ONE concept
- 2017 Establishment of the SWISS BIOHEALTH EDUCATION CENTER
- 2018 Establishment of SWISS BIOHEALTH VITAL and SDS SWISS DENTAL SOLUTIONS USA, Inc.
- 2019 Establishment of the SWISS BIOHEALTH ACADEMY
and the SOUL FOOD vegan café & take away
- 2020 Re-elected as Chairman of ISMI e.V.
- 2020 Launch of the SDS ceramic implants in
the US
- 2021 Foundation of the Scientific Academy for Blood Concentrates, Biological Dentistry and Ceramic
Implants (SABBC)

Changes in our environment

If we take a conscious look at the global changes occurring in our environment, we notice some trends running in parallel: On the one hand, an exponential increase in the loss of intact ecosystems and the species they harbor. On the other, an exponential increase in chronic diseases and a similarly exponential increase in the strain on our immune systems (Fig. 1). This is, however, being met by an exponential increase in organic nutritional and behavioral concepts.

CHRONIC DISEASES

Chronic diseases, such as cancer, Lyme disease, ALS, Alzheimer's disease, Parkinson's disease, MS, Crohn's disease, diabetes mellitus, bronchial asthma and chronic fatigue syndrome, are increasing at an explosive rate, and the extrapolation of the curves shows that within a few years, everyone living in the Western world will be affected by at least one of these diseases⁽¹⁾. Numbers among children are also on the rise, with one in every 59 eight-year-olds suffering from autism, for example⁽²⁾.

MULTIPLE SCLEROSIS, ALS, AUTOIMMUNE DISEASES

In Germany alone, for example, the number of MS cases increased from around 100,000 to approximately 150,000 per year between 2004 and 2009. The annual incidence rate (number of new cases) in Germany is eight cases for every 100,000 inhabitants. Women are three times more frequently affected than men⁽³⁾. In the United States, with the introduction of copper amalgam in 1976, its incidence escalated from one year to the next, from about 8,000 new cases per year to 123,123 new cases⁽⁴⁾. Subsequently, the incidence rate for every 100,000 US citizens rose from 34.8 in 2001 to 46.3 in 2014⁽⁵⁾. In Norway, the incidence of MS rose from 1.9 to 8.0 for every 100,000 inhabitants, while the prevalence (number of sufferers) increased tenfold. Vitamin D deficiency is considered a risk factor⁽⁶⁾.

Amyotrophic lateral sclerosis (ALS) was virtually unknown 20 years ago. Today, its incidence worldwide has already increased to 2.6 individuals, with a prevalence of six, for every 100,000 inhabitants⁽⁷⁾. Around 6,000 American citizens are diagnosed with ALS every year⁽⁸⁾. Northern countries are more severely affected, which could be indicative of the correlation with vitamin D3 deficiency. The number of deaths caused by ALS increases by 60 percent each decade. Most patients are given a life expectancy of two to five years⁽⁹⁾. Comparing the rise in the ALS death rate (Fig. 2) with the increase in root canal treatments reveals an alarming parallelism: Around one million root canal procedures were carried out in the US in 1975. It is estimated that the number of root canal procedures carried out in the US in 2006 was around 22.3 million and that more than 41,000 root canal treatments are

still performed each day^(10,11). In Germany, around 7 million teeth were endodontically treated under public health insurance in 2017⁽¹²⁾.

Widespread chronic diseases also include autoimmune diseases. At present, an estimated 23.5 million Americans suffer from these diseases. In Germany, they affect around five of the population. Autoimmune diseases compromise almost every system in our body. They can affect the nervous system and mind (autism, depression), our joints, muscles, skin, hormonal glands, heart and other organs. The increasing burden posed by germs, environmental toxins, allergens, stress and poor diet are considered to be the cause⁽¹³⁾.

BEGINNING OF A CHANGE IN MINDSET

Thankfully, with the prevalence of chronic diseases veritably exploding, people are forced to adjust their mindsets and strive for a healthier, "organic" way of life: In standard supermarkets, organic products are, proportionally speaking, the best-selling products, with specialist organic shops such as "Alnatura" in Germany or "Whole Foods" in the US sprouting up left, right and center. Ever more restaurants' menus feature gluten-free dishes or dishes recognized as being healthy and free from additives. The reduction of harmful substances in textiles, the conservation of natural resources and success stories of the likes of Tesla's electric cars and many other examples all send a clear message. Even for the cigarette, a product quite obviously detrimental to our health, there is now an "organic" version of each brand. What is interesting is that, nowadays, the profile of the "organic consumer" spans both the "esoteric environmentalist" and the social elite. Could it be that Darwin's principle of natural selection is once again at play? Unfortunately, with certain factors in our environment posing an increasingly acute threat to our health, this change in mindset is a matter of urgency.

IMPORTANT CAUSES OF DISEASE

The pathogenetic factors include increasing electromagnetic radiation in the form of high gigahertz frequencies used in mobile communications, Wi-Fi and DECT technology. The radioactive burden is also steadily increasing, surging exponentially in the aftermath of accidents like Fukushima. Furthermore, the addition of titanium dioxide (E171) to medicines, cosmetics, sunscreen, oral contraceptives, toothpaste, chewing gum and even food products, such as yoghurt, mozzarella, instant soup and sweets, is rendering titanium intolerance more widespread—a substance still widely used in implantology and traumatology^(15,16). Yet, even in its purest form, "grade 1 titanium", this chemical element still contains up to 0.20 iron⁽¹⁷⁾. It may also contain traces of nickel⁽¹⁸⁾. This is an alarming

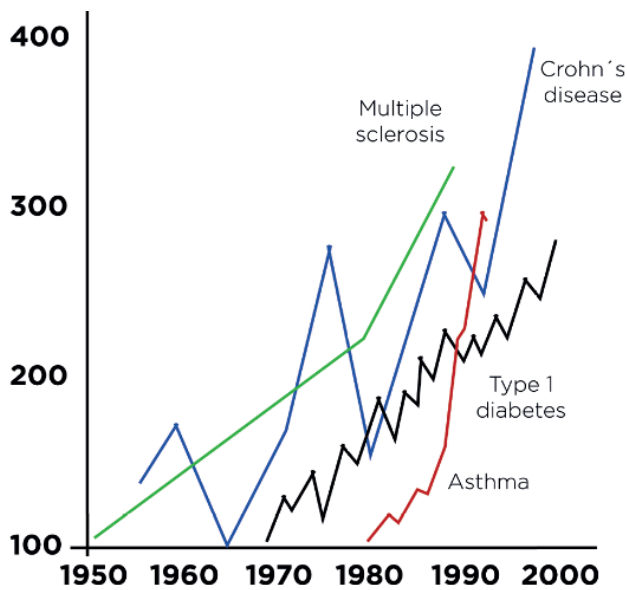


Figure 1: Increase in the incidence of a number of autoimmune diseases⁽¹⁾

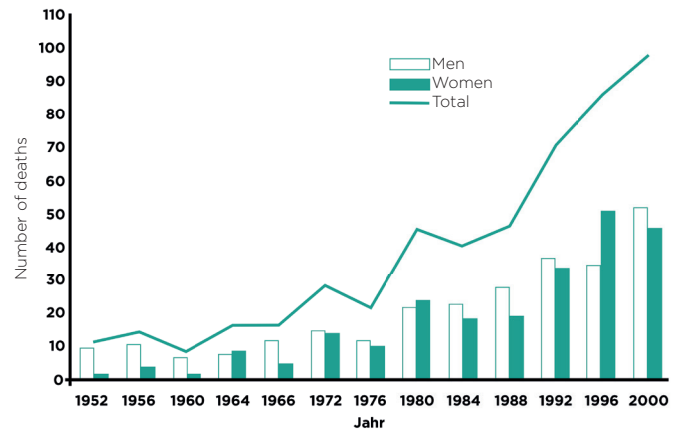


Figure 2: Number of deaths from ALS per year⁽¹⁴⁾

fact when you consider that, in Europe alone, around 65 million citizens are allergic to nickel⁽¹⁹⁾. Nickel causes the greatest number of contact allergies. The 2007 REACH regulation attempted to protect the European population from excessively high degrees of nickel exposure. Nonetheless, some 8-18 of citizens still incur allergic reactions to nickel. Women are more frequently affected than men⁽²⁰⁾.

Stress as a cause of disease

The alarming rise of chronic diseases is based on one common cause: the overwhelming increase in stress, which causes our immune system to shut down (imbalance between the sympathetic and the parasympathetic system^(21,22)). This also includes stress triggered by negative emotions in relationships and work environments and our increasingly hectic lives, in which technology is omnipresent and we are expected to be permanently available.

EMF as a cause of disease

The second major factor is the exponential rise of artificial electromagnetic fields (EMF). A study conducted in Swiss doctors' practices shows that the majority of chronic diseases were decreasing until the point of nationwide mobile network coverage, but have been increasing more and more ever since (Fig. 3): Children are especially vulnerable to mobile communications radiation and electromagnetic fields⁽²³⁻²⁹⁾. There have been reports of tumors of the brain and other organs, compromised sperm quality and oxidative stress in connection with electromag-

netic radiation⁽³⁰⁻⁴¹⁾. The WHO also classifies high-frequency electromagnetic fields as potentially carcinogenic among humans⁽⁴²⁾. The dangers of the 5G network, which is currently being introduced despite widespread criticism from scientists, are impossible to estimate. According to the current state of scientific knowledge, the German Federal Office for Radiation Protection (Bundesamt für Strahlenschutz, BFS) "does not anticipate negative health effects but does see some open questions"⁽⁴³⁾. The BFS bases its observations on just a few research results and highlights the need for additional research. On its website, the BFS warns against the possible effects on the skin and eyes of high-frequency electromagnetic fields in the mili- or centimeter-wave range, i.e. close to the body surface. It seems no negative repercussions for inner organs⁽⁴³⁾, although many studies have found evidence to suggest 5G⁽⁴⁴⁻⁴⁸⁾, which is 1000 times stronger than 4G, will cause damage.

Stress factors in the oral cavity as a cause of disease

The third stress factor—the major one for chronically ill patients—is the oral cavity and the teeth acting as a bio-reactor for viruses, bacteria and fungi, and a source of toxins and inflammation mediators. Heavy metals in amalgam fillings and other dental alloys as well as allergens from plastic and alloy components may also have a pathogenic effect. Their impact on the immune system is negative⁽⁴⁹⁾. This is exacerbated by the antenna effect of metal prosthetics, which can amplify the negative impact of electromagnetic fields—in immediate proximity to our

central nervous system! Cardiologist Dr. Thomas E. Levy, too, highlights the threat posed by dental nidi for the organism in its entirety. He sees increased intracellular oxidative stress as the cause of all illness. He considers chronic diseases to be most readily caused by chronic pathogenic bacterial colonizations (e.g. of the sinuses or the pharynx) or infections, with the oral cavity accounting for over 95% of infections. The sinuses, the nasopharynx and upper respiratory tract but also the bronchi, appendix and ulcers are further sites of infection. Additional causes include toxic burdens (e.g. heavy metals and pesticides), toxic iron levels, poor diet or digestion and hormonal imbalances. Germs from the oral cavity are a burden on the whole organism. Several studies have demonstrated the pathogenic effect of the parodontal marker germ *Porphyromonas gingivalis* in the event of gastrointestinal, oral cavity and pancreas carcinomas⁽⁵⁰⁻⁵⁵⁾. This and other oral pathogenic germs have also been connected to cardiovascular diseases. They have been found in the breast tissue of women suffering from malignant diseases as well as Alzheimer's patients' brains⁽⁵⁶⁻⁵⁹⁾.

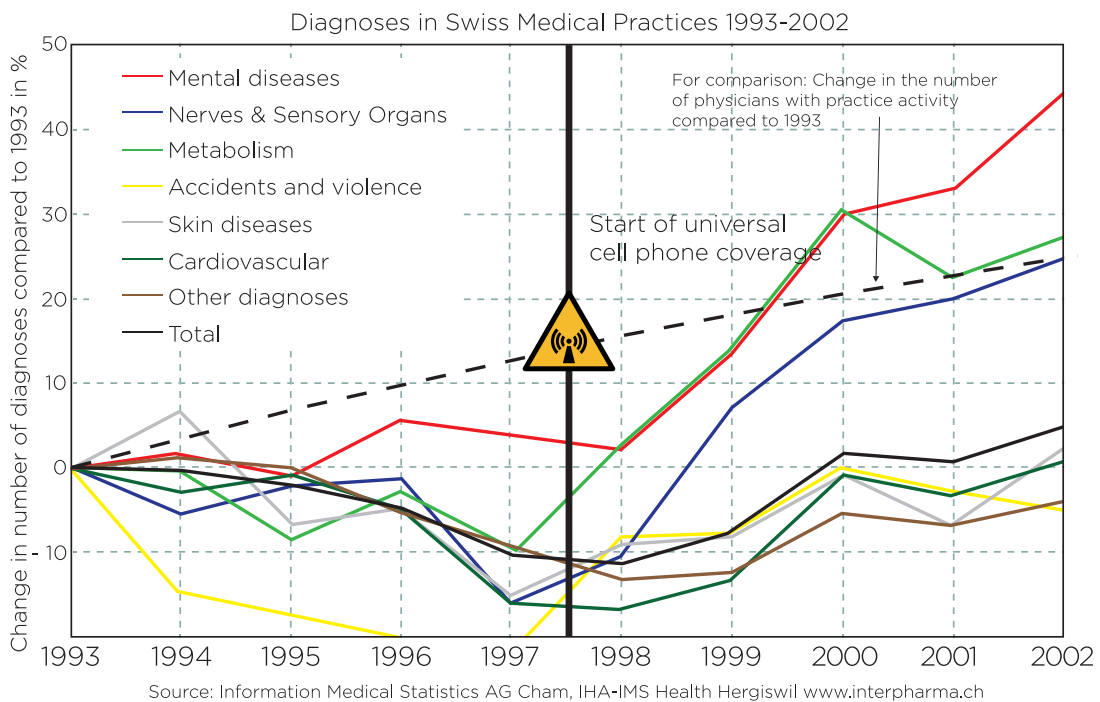


Figure 3: Diagnoses in Swiss doctors' practices⁽²⁵⁾

The correlation between dental stress and chronic diseases

The above insights demonstrate that our altered way of life calls for new concepts in dentistry and medicine. This includes reducing the surface area susceptible to interference from environmental factors by removing any dental metal and significantly relieving the burden on our body's ability to self-regulate through restoration and healing any chronic inflammation of the masticatory system. In the experience of the SWISS BIOHEALTH CLINIC, consistently abiding by these principles will improve the health of almost every patient. Patients very often feel the benefits whilst still in the dentist's chair at the end of a treatment session (see testimonials on www.swiss-biohealth.com). When the last bit of metal has been removed, patients very often say that they feel as if a "helmet has been taken off" or that a "thick piece of glass has been removed from in front of their face." After nidi of chronic inflammation, such as osteitis of the jaw, cysts, or root-canal-treated teeth have been removed, patients very often experience an immediate improvement in their musculoskeletal system. For example, they may suddenly be able to move their arm without pain.

THE VEGETATIVE NERVOUS SYSTEM

The central network for the body's own regulation processes is the vegetative or autonomous nervous system. All external and internal influences have a positive or negative impact on its ability to function. Its condition can be diagnosed very easily with the help of the heart rate variability (HRV).

Sympathetic and parasympathetic nervous system

The stress response controlled by the sympathetic nervous system is a vital physiological reaction of the autonomic nervous system (which we cannot consciously control) that serves to keep us alive. The release of adrenaline, noradrenaline and cortisol triggers our flight-fight-freeze response within fractions of a second, as the amount of oxygen and nutrients in our blood and tissue increase within the skeletal musculature. Our heart rate rises, blood vessels narrow and blood pressure increases. Breathing is intensified to gain more oxygen. Our body is supplied with energy thanks to the release of fatty acids from our fatty tissue and of glucose from our glycogen reserves. To compensate, the internal organs need to be inhibited. The intestinal muscles are relaxed and digestion repressed, and the thymus gland, the spleen and the lymph nodes decrease antibody production. Tissue inflammation is inhibited, benefiting pathogen distribution the longer the situation persists. Our core body temperature is increased and sweat production concomitantly stimulated in order to counteract overheating. Our pupils dilate as this expands the field of vision by around 10%, making it easier to perceive enemies or means of escape. Our kidneys retain water, while the salivary glands

(dry mouth) and sex organs are inhibited. Our entire metabolism and physiology are focused upon a single objective: To bring the acutely life-threatening situation to an end as quickly and successfully as possible⁽¹⁻³⁾. If these useful physiological mechanisms caused by the activation of the sympathetic nervous system are sustained for a longer period than evolution intended, this results in huge regularization disturbances, which, in turn, lead to functional disturbances and also, in the long term, to structural disorders. When cells are deprived of oxygen and become hyperacidic, we incur cellular and tissue damage and may even develop cancer. In 1931, Otto Warburg won the Nobel Prize for proving the cellular mechanisms underlying cancer development, which dictate that a cancer cell cannot survive in an alkaline, oxygen-rich environment⁴⁾. It is not until the period of stress is over, switching the vegetative nervous system into the parasympathetic nervous mode, that the immune and regeneration systems can resume their physiological activities and healing mechanisms can be reactivated (see Fig.1). Hence, the most important part of complication-free healing after surgery is that patients do everything they can to activate the parasympathetic nervous mode. This includes taking a "digital sabbatical" of at least five days after surgery.

Heart rate variability (HRV)

Heart rate variability (HRV) is a key marker of the vegetative nervous system. It describes the heart's ability to vary the interval between one heartbeat and another, adapting to continuously changing challenges. As early as 300 A.D., Wang Shuhe, a doctor, recognized the following: "If the heartbeat gets as regular as the knocking of the

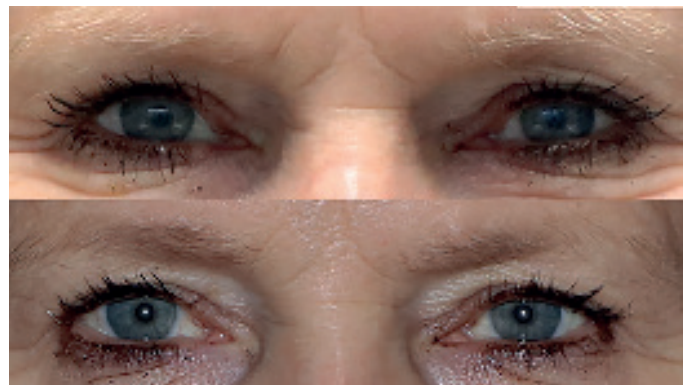

Figure 1: Eye area directly before and after eight-hour surgery: The eyes are much clearer and the pupils are smaller due to the impact on the parasympathetic nervous system.

woodpecker or the dripping of the rain on the roof patient will die within four days”⁽⁵⁾. A high HRV indicates good adaptability and health. A low HRV is correlated with various physical and psychological pathologies, such as cardiovascular diseases, carcinomas, stroke, diabetes, nephritis, neuropathy and chronic stress⁽⁵⁻⁷⁾. Patients at our clinic are routinely HRV tested before and after each treatment. We usually see improvement in HRV as soon as the interference fields have been eliminated (Fig. 2).

The importance of regulation

A manifest chronic disease presents itself as a structural disorder (growth of tumor tissue, changes in vessels, changes in tissue chronically susceptible to inflammation, bone or cartilage anomalies, muscular atrophy, etc.). This constitutes a pathological anatomical change. The structural disorder, however, is always preceded by a functional disturbance (impaired cell division, deficiency or surplus states within cells, poor/compensatory posture), which, in turn, is triggered by a regularization disturbance (due to hyperacidity, cellular stress, oxygen deficiency, vitamin and nutrient deficiency, inflammation, toxins, bacteria, allergens, etc.). Clearly, a treatment that tackles the end of this chain cannot promise a great deal of success, because the functional and preceding regularization disturbances are maintained and will even be put under additional strain if the structure is operated on (e.g. sup-

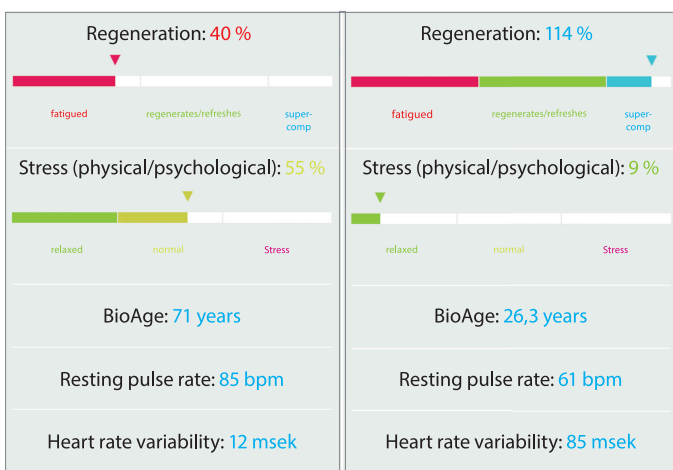


Figure 2: The heart rate variability (HRV) measurement taken prior to and after surgery removing multiple dental sources of disturbance shows an impressive reduction in stress and significant improvement in regeneration and the patient's biological age.

pression in the event of an operation). The exception to this is operations which eliminate the cause of the regulation disturbance. The main problem lies in the fact that our lifestyles and contemporary environmental burdens result in such multi-layered stress that our immune and regeneration systems are hugely compromised⁽⁸⁾. Not only does stress block these systems; it also consumes large additional quantities of nutrients and vital substances, triggering a vicious circle by further exacerbating the deficiencies we have. The underlying mechanism is a disturbance of the regulation of the vegetative, autonomic nervous system. The aforementioned stress factors lead to a dominance of the sympathetic nervous system to the detriment of healing processes, which may become blocked entirely.

FORMS OF STRESS

Unfortunately, in addition to the genuine stress evolution has accommodated for, which usually lasts for a very short time and can nowadays be triggered by an accident or an attack, we also experience longer lasting stress. This kind of stress was unknown to or at least very rarely encountered by the humans of the past, which is why our physiological system simply is not prepared for it. This includes physical (physiological/biochemical) stress: This can be caused by metals in the oral cavity, particularly heavy metals (e.g. mercury from amalgam fillings), toxins from root-canal-treated teeth and allergens from filling materials, but also by our diet (e.g. gluten)⁽¹⁰⁻¹³⁾. Being overweight or deficient in nutrients such as magnesium

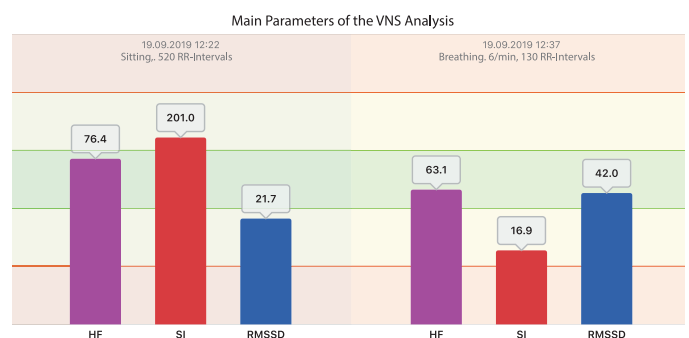


Figure 3: VNS analysis is ideal for scientific work, as it reflects the state of the vegetative nervous system very accurately. In many patients, a significant improvement occurs in the balance between the sympathetic nervous system (red bar) and the parasympathetic nervous system (blue bar) when they practice metronomic breathing (right-hand side) in comparison with the baseline of spontaneous breathing (left-hand side)⁽⁹⁾.

or vitamin D3, being unfit, having a generally poor diet, experiencing sleep deficiency and being exposed to electromagnetic fields (EMF) all increase such physical stress⁽¹⁴⁻¹⁶⁾. Then there is psychological stress, which we generate ourselves and which arises as a result of inappropriate fears and images in our brain: “I’ve lived through some terrible things in my life, some of which actually happened.” (Mark Twain). Emotional stress and health issues are triggered by stressful relationships at home or at work, as well as by places and situations (traffic jams, loud noise, air pollution, etc.)^(8,18,19).

THE IMPORTANCE OF CHRONIC INFLAMMATION

The immune system, along with its primary organs, the spleen and lymphatic systems, works locally and systemically with the help of immune cells and neurotransmitters that are dispersed via our blood and lymphatic vessels. Its functions are influenced and precisely regulated not least by the autonomic nervous system (sympathetic and parasympathetic nervous systems). The immune system is designed to react to pathological processes and pathogens like bacteria with acute inflammation, which overcomes these as quickly and effectively as possible. This also inhibits autoimmune processes. Energy is made available as glucose and fat, and a catabolic state is triggered in order to regulate the inflammation process down again as quickly as possible. The entire inflammation process is steered by the autonomic nervous system on the one hand, and hormonally via the hypothalamic-pituitary-adrenal axis (HPA axis) on the other. Acute inflammation is accompanied by increased systemic sympathetic nervous system and reduced parasympathetic nervous system⁽²⁰⁾. A “healthy” acute inflammation reaction occurs as follows: Immunological processes, triggered by neurotransmitters, and the activated sympathetic nervous system have a proinflammatory effect in order to combat pathogens to the greatest extent possible, overcoming them entirely⁽²¹⁾. If the inflammation reaction is successful in achieving this goal, the inflammation reaction is wound down locally and systemically and the catabolic process comes to an end. T helper cells also contribute to this thanks to their anti properties⁽²²⁾.

A vicious circle arises if the acute inflammation does not achieve its goal and therefore evolves into chronic, silent inflammation in which the inflammatory reaction and the sympathetic nervous system activity sustain each other. This may cause further illness, such as high blood pressure, insulin resistance, cardiovascular issues and diabetes. In cases of advanced cancer, it can lead to cachexia⁽²²⁾. At the same time, the parasympathetic nervous system’s activity with its anti-inflammatory effect is blocked. This was demonstrated in a study in which the peripheral pro-

duction of cytokines was inhibited by stimulating the vagus nerve. Significant inhibition of TNF- α and IL-6 production relieved symptoms in rheumatoid arthritis patients, even among some of those who had proven resistant to therapy⁽⁸³⁾.

Of the three most important causes of chronic diseases in today’s world—stress, EMF and stress factors in the oral cavity—the latter are described in further detail in the next chapter.

Mechanisms of oral disturbances

Bacteria or bacterial products in jaw inflammation or escaping from root-canal-treated teeth are released into the bloodstream (bacterial translocation) and are characterized by endotoxemia (increased endotoxin concentration in the blood)⁽¹⁾. This stress, sustained on a 24/7 basis, triggers low-level but chronic inflammatory processes in the body and is referred to as “silent inflammation”.

SILENT INFLAMMATION

In the long term, a silent inflammation can cause serious metabolic diseases, such as obesity or diabetes mellitus, as well as severe cardiovascular diseases (atherosclerosis, heart attacks, strokes) and cancer.⁽²⁻⁴⁾ Endotoxins, components of lipopolysaccharides (LPSs) in the outer wall of gram-negative bacteria, are released by bacteria directly or after their death. LPSs activate the cells of the innate immune system and initiate an inflammatory reaction. Macrophages are activated, causing intracellular NF- κ B formation and the production of proinflammatory cytokines. Increased NF- κ B-mediated gene activation leads to the formation of nitric oxide synthase, which initiates the formation of nitrogen monoxide (NO). This causes what is known as nitrosative stress and is a factor in the development of mitochondriopathies⁽¹⁾.

AUTOIMMUNE DISEASES

Each of our cells has a so-called “MHC code” (major histocompatibility complex)^(5,6) that tells our immune system that the cell belongs to us and is a “self-cell”. You could also describe this as a uniform people wear to identify themselves as members of a particular group, which prevents them from being attacked by the other group members. However, if this MHC code is changed, it is somewhat like the cell changing its uniform and coming under attack by its own group’s “police force”, i.e. its own immune system. The “self cell” becomes a “non-self cell”. Toxins from jaw inflammation or root-canal-treated teeth, in particular, along with heavy metals from dental materials, primarily amalgam (consisting of over 50% mercury), bind to our cells and change the MHC code. If the cell in question is a muscle cell, this can result in fibromyalgia or MS. If it is a nerve cell, it can trigger MS, ALS or Alzheimer’s disease. Various studies have proven the correlation between amalgam and MS, ALS and Alzheimer’s disease⁽⁷⁻⁹⁾.

RETROGRADE AXONAL TRANSPORT

Endotoxins, which originate from bacteria or are released when bacteria die, can— similar to tetanus and botulinum toxins—be transported through axons (nerve fibers) and quickly reach the ganglia or the CNS⁽¹⁰⁾. There, they can lead to blockages and failures of the trigeminal nerve, the abducens nerve or the facial nerve, for instance. Consequently, removing the lesion or the interference field and

eliminating the endotoxin supply source can result in a sudden improvement in the innervation area of the respective nerve in what could be termed an “instantaneous effect”. This effect can be simulated, e.g. by injecting a local anesthetic⁽¹¹⁾.

ALLERGIES AND INTOLERANCES

Plastics, especially methacrylate⁽¹²⁾, very frequently cause genuine type I allergies. Type IV allergies occur in response to dental alloys⁽¹³⁾. Titanium, on the other hand, triggers “particle-induced inflammation”, because the titanium particles in the tissue surrounding the implant are phagocytized by macrophages, which respond to this stimulus by releasing osteoresorptive, pro-inflammatory cytokines (TNF- α , IL-1 β)^(14,15). Titanium tolerance should therefore be verified by way of the “titanium stimulation test” prior to the use of titanium (www.imd-berlin.de). The above figure clearly shows how the “titanium particle > activation of tissue macrophage > release of TNF- α and IL-1 β > osteoclast activation axis” causes bone degradation around the implant^(16,17). The latest studies have now proven our long-time assumption, namely, that that so-called “peri-implantitis”, i.e. inflammatory bone loss around titanium implants, is nothing other than a sign of titanium intolerance^(17,18). This explains why the widespread method of treating peri-implantitis by grinding and polishing the implant surface or cleaning it with titanium brushes does not work. It releases massive amounts of titanium particles into the bone and tissue, adding fuel to the fire and leading to further loss. As a possible titanium peri-implantitis therapy, we recommend raising the amounts of bone building factors by supplementing with vitamins C and D3, vitamin K2/mk7, magnesium, zinc, omega-3 as well as inhibiting the bone-damaging osteoclasts by giving the patient vitamin C or D3 or acetylsalicylic acid^(28,29). Disturbances and stress on the immune system play a role in all of the above-mentioned pathogenetic mechanisms, whether directly or indirectly. This should be seen in connection with the finding of one of the world’s leading immunologists, Prof. Yehuda Shoenfeld, who observed that every second American suffers from a disease of the immune system⁽³⁰⁾. This underscores the need to look for disturbances in the oral cavity in the event of a chronic disease.

ROOT CANAL TREATMENTS

Endodontically treated teeth are dead teeth (Fig. 2). A dead tooth—once an organ with its own nerve and blood supply—remains in the oral cavity as a dead pillar. Even the best micro-surgical endodontic treatment will never manage to clean out all bacteria and seal the root canal in a bacteria-tight manner. A cross-section of dentin shows that, owing to technical limitations, it is simply not possible to sufficiently clean and fill the 14,000– 32,000 den-

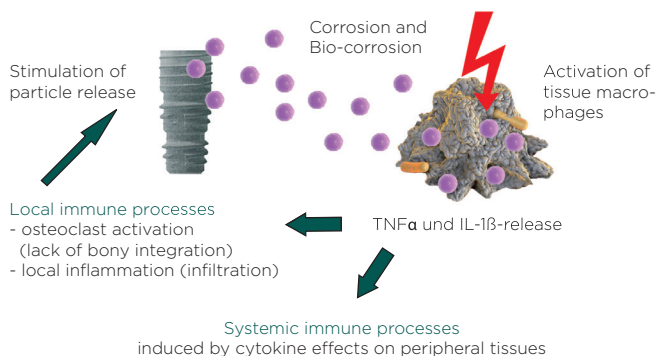


Figure 1: Titanium-particle-induced inflammatory response⁽¹⁸⁾

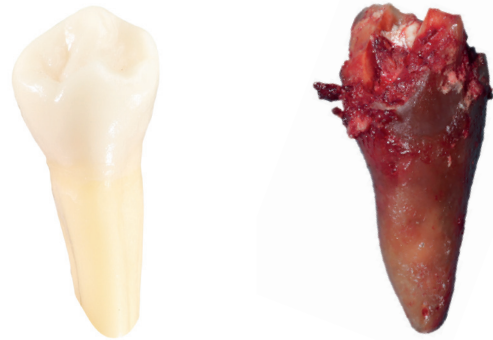

Figure 2: Comparison of a healthy tooth with an endodontically treated tooth

tinal tubules per mm² of root dentin⁽³¹⁾ (technical limitation). Accessory and side canals as well as the perio-endo connection via the dentinal tubules remain in place. They are colonized by different, partly unknown species of anaerobic, pathogenic bacteria, which decompose the remaining organic tissue and secrete harmful metabolic products (toxins)⁽³²⁾. Here, another, immunological limitation becomes apparent. It results from the fact that pathogens such as bacteria, which are 0.6 to 1 µm in diameter, can easily penetrate the dentinal tubules, which are up to 3 µm in width (Fig. 3 and 4). Once they are inside the dentinal tubules, the macrophages, which measure approx. 25–50 µm, cannot reach and eliminate them^(33–35). This situation is best illustrated by comparing it to a cat (macrophage) sitting in front of a mouse hole (dentinal tubule) that cannot reach the mice (bacteria). These pathogenic bacteria produce highly toxic and potentially carcinogenic hydrogen sulphide compounds (thioethers/mercaptans) from the amino acids cysteine and methionine as by-products of anaerobic metabolism⁽³⁶⁾.

By means of irreversible inhibition at the active center of many vital endogenous enzymes, these toxins can cause a wide range of systemic and organic diseases^(37–39). The inhibition of important enzymes in the respiratory chain of mitochondria has been proven⁽⁴⁰⁾ and is also demonstrated in lab tests in clinical practice⁽⁴¹⁾. Whenever we chew, these bacteria, and especially their toxins, are released into the lymphatic system of the surrounding tissue, from where they enter the bloodstream (focal infection) and then the entire body. A study conducted by Siqueira et al. found microorganisms in 19 out of 20 endodontically treated teeth with apical inflammation, which suggests chronic infection⁽⁴²⁾. Another study examined the microflora on teeth with apical periodontitis And

demonstrated the presence of rods, cocci, filaments and spirochetes⁽⁴³⁾.

If an inflammation of the tip is visible on the X-ray, root canal treatment is significantly more likely to fail due to chronic infection. In principle, it can be said that, since the introduction of the use of three-dimensional radiographs (DVT) as standard, it has become apparent that virtually no root-treated tooth is free of apical inflammation. An intact immune system plays a decisive role in fighting off these germs activated after root canal treatment. It is however often impossible to control them, and chronic infection caused by colonization with germs develops into chronic inflammation of the surrounding bone, permanently activating the immune system. The macrophages activated over the course of this unspecific immune reaction release so-called “inflammation mediators” (TNFα, IL-1β, growth factors, prostaglandins PGE2 and leukotrienes), which circulate in the bloodstream. These inflammatory mediators favor the onset or advancement of systemic chronic inflammation and autoimmune diseases⁽⁴⁴⁾. TNF-α has been shown to increase the risk of developing postmenopausal breast cancer^(45,46). Dr. Thomas Rau from the Paracelsus Clinic in Switzerland has been able to demonstrate a significant correlation between breast cancer and root-treated teeth. He found root canal treatments on one or more teeth on the stomach meridian that runs across the breast in more than 96% of breast cancer patients, compared to only 35% in healthy patients⁽⁴⁷⁾. Many studies increasingly indicate a correlation between root-canal-treated teeth and general diseases^(37,48,49). They show that root-canal-treated teeth can be associated with cardiovascular disease, diabetes, depression, oxidative and nitrosative stress^(2-4,39,50,51). A healthy organism's perfect defense against such an




Figure 3: Dentinal tubule with a diameter of approx. 2-3 μm .

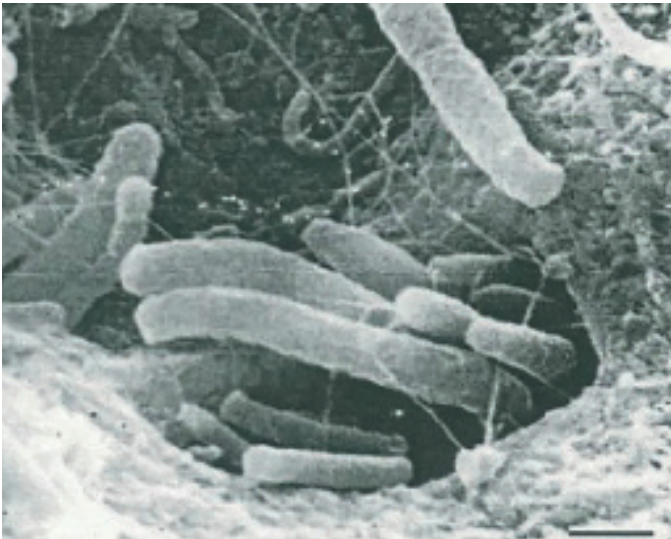

Figure 4: This illustration shows that bacteria, viruses, fungi, spirochetes and other germs can effortlessly penetrate the dentinal tubules in several rows.

inflammation would be an abscess with a swollen cheek. Today, however, we only know this type of reaction from textbooks. We have not seen it in any of our patients for about 20 years, as immunological performance among the population of western industrial nations has declined massively. Over the past 50 years, immunoglobulin A levels, a yardstick for measuring the strength of the immune system, have decreased by more than 30% in these countries! Even a cyst with or without a fistula is evidence of a

halfway intact immune system, but this too is becoming increasingly rare. In most cases, the only manifestation still present in the area of the root-treated teeth is an undefined diffuse osteonecrosis (IO/NICO/FDOJ)—a sign of the immune system’s complete surrender! In addition to silent inflammation and autoimmune reactions that occur in root-treated teeth, allergic reactions to various highly allergenic substances, such as gutta-percha, silver, Peru balsam or paraformaldehyde, contained in root canal fillings are very common⁽⁵⁴⁾.

THE MERIDIAN SYSTEM AND ITS CORRELATION WITH ORGANS

The entire surface of the body is covered with a network of energy channels (meridians), which appear through the muscle fascia at certain switching points (acupuncture points) as small, anatomically proven neurovascular bundles. The transmission of information along the meridians has also been demonstrated by injecting radioactively labeled substances at the acupuncture points. Each of these meridians traverses a specific tooth or tooth group and is associated with certain anatomical structures and organ zones (see scheme on p. 24 and 25)⁽⁵³⁾. Consequently, inflammation or a disorder in a specific dental zone almost always results in disturbance in the zone governed by this meridian, and, conversely, in an improvement once the disturbance is eliminated. Biological dentists familiar with the relationship between teeth, dental zones and particular organs or organ zones can have a targeted consultation with the patient based on disturbances along the meridian in question. In turn, dentists may stimulate improvement along the meridian by means of neural therapy in the corresponding tooth zone. This is a very convincing diagnosis and therapy simulation method for patients, because temporary improvement is experienced within a few seconds or within a few hours. Improvement may be felt in the arm, for example, despite the injection having been made into the dental area⁽⁵⁴⁾. In addition to the narrowly defined and precise remote effect of the meridians, there is the so-called “myotome”, which is influenced by disturbances in the oral cavity: C1-C7. As a rule of thumb, all oral cavity disturbances manifest as neck pain, usually associated with limited head mobility.

THE CONCEPT OF ORAL INTERFERENCE FIELDS

The concept of “interference fields” in the human body is based on the assumption that an inflammatory process in one part in the body can cause a reaction in another part and lead to therapeutic resistance and chronic disorders. In order to identify the interference field, a dentist will usually evaluate x-rays and clinical findings and compare them to the specialist physician’s medical findings.

Interference field diagnostics

The teeth constitute one of the most important subsystems within a network of parts of the organism that perform a regulative function. Teeth and the respective periodontium (odonton) are related to other physical structures and organs. Reinhold Voll coined the term "odonton" and identified the direct and close interrelationships between the individual odontons and the different areas of the body. Interactions as well as both positive and negative influences can cause remote effects in both directions: A disturbed organ may have a pathological effect on the associated odonton, conversely, a diseased tooth or its periodontium may disturb the organ to which it correlates (see p. 24 and 25)^(55,56).

Clinical diagnostics

TEST INJECTION WITH 1% PROCAINE

Before the introduction of procaine, cocaine was the most commonly used analgesic substance and was, among other uses, contained in the very early formula of Coca-Cola®. Procaine is an anesthetic with few side effects (Novocaine®) which blocks stimulus conduction. In addition, it has an antiphlogistic effect (IL-6 and CRP inhibitor), stabilizes the nerve cell membranes by normalizing their action potential, stimulates the parasympathetic nervous system (vagus reaction, vasodilation), promotes the formation of new blood vessels and tissue blood flow (antidote to adrenaline) and is considered a radical scavenger⁽⁵⁷⁻⁶⁰⁾. It also exerts an attractant effect (chemotaxis) on defense cells. Up to 200 mg of procaine, i.e. up to 20 ml of the 1% solution, can be injected in a single application. Once inside the tissue, procaine breaks down into its components diethylaminoethanol, which is closely related to the neurotransmitter and parasympathetic activator acetylcholine, and para-aminobenzoic acid, a building block of folic acid⁽⁶¹⁾. It was the Romanian physician Prof. Ana Aslan (1897-1988) who primarily demonstrated the anti-aging effect of procaine.

In principle, the injection represents a temporary reboot of sorts for the respective region. The resulting viscerocutaneous results in induces the brain to focus on this part of the body and the potential interference field (root-treated teeth, titanium implants, FDOJs, etc.) is decoupled from the corresponding organ for a certain time. 1% procaine is injected into the vestibular fold of the suspected region and, additionally, orally (in the wisdom tooth region, the retromolar trigone is also injected). The injection is not to be made too tentatively. Instead, a deliberate movement should result in a noticeable puncture for the injection of approx. 0.1 to 0.2 ml of the liquid. This puncture pain triggers the viscerocutaneous reflex, which will wake up the system, so to speak. According to a German entry in Wikipedia, "The visceral reflex is a reflex that causes pain originating in internal organs to be perceived as pain on the skin. The damaged organ and the painful spot on the body's surface can sometimes be far apart"⁽⁶²⁾. Patients should keep their eyes open so that a potential constriction of the pupils can be observed. A constriction of the pupils means that the neural therapeutic injection has temporarily moved the patient from the sympathetic to the parasympathetic tone—i.e. a state of relaxation and healing—by triggering vagus reaction. Patients suffering from chronic inflammation will always be in the sympathetic tone (flight, resistance and defense with release of adrenaline). However, healing can only occur in the parasympathetic tone. If there is a connection between the neural therapeutic injection in the tooth area and a general medical disease or disorder, the patient will show an improvement in the connected body area

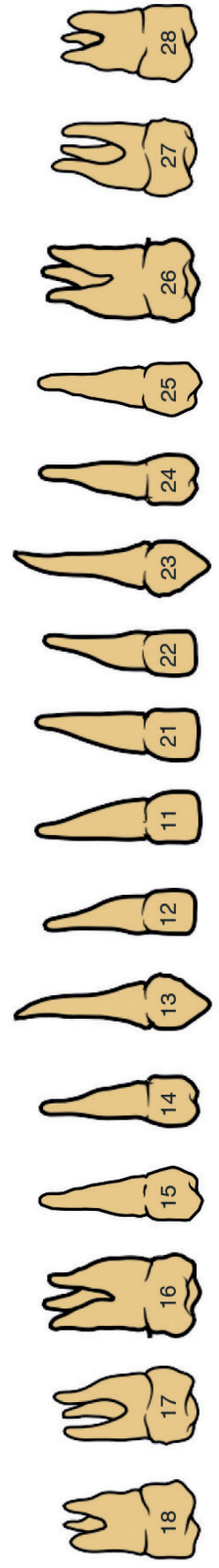
within a few seconds, within eight hours at the latest. To give an example, almost all shoulder, arm and elbow pain correlates with root-treated teeth on the colon meridian (upper first and second premolars and lower first and second molars). Following neural therapy, the discomfort almost always disappears immediately for a period of a few hours. Patients are asked to observe any subtle changes in their condition over a period of around 24 hours after the injection. Frequently, the so-called "Huneke Seconds Phenomenon" occurs immediately after the injection, resulting in spontaneous improvement in patients suffering from shoulder-arm syndrome. The suspected tooth can be diagnosed as a definite interference field if the effect lasts for around eight hours. The effect of the anesthesia itself is short-lived and usually wears off after around 30 minutes.

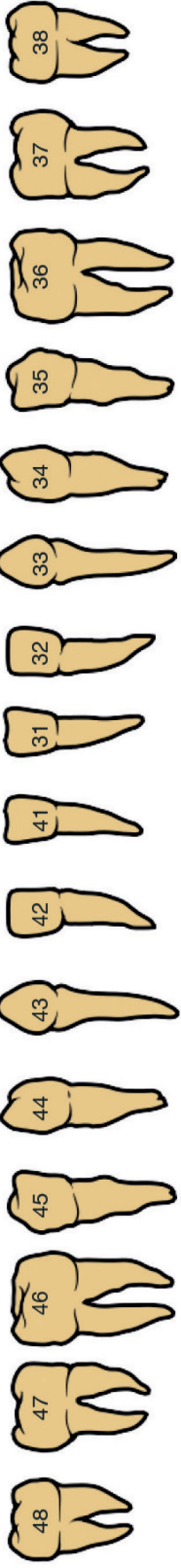
OROTOX® TEST

The OroTox® is a simple method of detecting toxin load. A sulcus fluid sample is placed in a reagent mixture whose color will change to yellow if there are any sulfur-containing compounds. As opposed to a microbiological analysis, the OroTox® test will detect the bacterial products thioether and mercaptan. OroTox® is not a diagnostic agent per se, but provides clear qualitative and quantitative information about the presence of mercaptan/thioether. High OroTox® values on a root-filled tooth are a clear indication of a toxin load that can lead to a disturbance of the cell's energy production⁽⁶³⁾.

Meridian system for self-analysis

SENSORY ORGANS	inner ear	tongue/taste	nose/olfactory sense	eye	nose/olfactory sense/frontal sinus	nose/olfactory sense/frontal sinus	eye	nose/olfactory sense	tongue/taste	inner ear
JOINTS	shoulder elbow	jaw	shoulder elbow	rear knee	rear knee	rear knee	hip	shoulder elbow	jaw	shoulder elbow
	hand ulnar foot plantar toes	anterior knee	hand radial foot big toe	hip	sacrum-coccyx	sacrum-coccyx	hip	hand radial foot big toe	anterior knee	hand ulnar foot plantar toes
SPINAL CORD SEGMENTS	Th 1 C8 Th 7 Th 6 Th 5 S 3 S 2 S 1	Th 12 Th 11 L 1	C 7 C 6 C 5 Th 4 Th 3 Th 2 L 5 L 4	Th 8 Th 9 Th 10	L 3 L 2 S 4 S 5 Co	L 3 L 2 S 4 S 5 Co	Th 8 Th 9 Th 10	Th 8 Th 9 Th 10 L 5 L 4	Th 12 Th 11 L 1	Th 1 C8 Th 7 Th 6 Th 5 S 3 S 2 S 1
VERTEBRAE	B 1 C 7 B 6 B 5 S 2 S 1	B 12 B 11 L 1	C 7 C 6 C 5 B 4 B 3 L 5 L 4	B 9 B 10	L 3 L 2 Co S 5 S 4 S 3	L 3 L 2 Co S 5 S 4 S 3	B 9 B 10	C 7 C 6 C 5 B 4 B 3 L 5 L 4	B 12 B 11 L 1	B 1 C 7 B 6 B 5 S 2 S 1
ORGANS	right heart	pancreas	lung	right liver	left kidney	right kidney	left liver	lung	spleen	left heart
YIN	11-13 h	9-11 h	3-5 h	1-3 h	17-19 h	17-19 h	1-3 h	3-5 h	9-11 h	11-13 h
	duodenum allergies	right stomach	colon	gall-bladder	left bladder urogenital region	right bladder urogenital region	left bile ducts	colon	left stomach	jejunum ileum allergies
YANG	13-15 h	7-9 h	5-7 h	23-1 h	15-17 h	15-17 h	23-1 h	5-7 h	7-9 h	13-15 h
ENDOCRINE GLANDS	anterior pituitary	parathyroid	thymus	posterior pituitary	epiphysis	epiphysis	posterior pituitary	thymus	thyroid	posterior pituitary
OTHER	CNS psyche	right mammary gland			back pain headache	back pain headache			left mammary gland	CNS psyche





OTHER	energy balance	peripheral nerves	arteries	veins	right mammary gland	gonads	adrenal gland	adrenal gland	adrenal gland	gonads	adrenal gland	gonads	left mammary gland	veins	arteries	energy balance
ENDOCRINE GLANDS VASCULAR SYSTEM					lym-phatic vessels								lym-phatic vessels			peripheral nerves
YANG	11-13 h	3-5 h	right lung	right lung	9-11 h	1-3 h	17-19 h	17-19 h	1-3 h	9-11 h	3-5 h	11-13 h	9-11 h	3-5 h	arteries	11-13 h
YIN	13-15 h	5-7 h	right heart cardiovascular system	right lung	7-9 h	23-1 h	15-17 h	15-17 h	23-1 h	7-9 h	5-7 h	13-15 h	7-9 h	5-7 h	veins	13-15 h
ORGANS	right ileum allergies	right colon ileosacral area	right stomach pylorus	right bladder urogenital area	pancreas	gall-bladder	right bladder urogenital area	right bladder urogenital area	right liver	right stomach	right bladder urogenital area	right bladder urogenital area	left stomach	left lung	left heart cardiovascular system	jejunum ileum allergies
VERTEBRAE	C7 B1 B5 B6 S1 S2 hip	C7 C6 C5 B4 B3 L5 L4	B12 B11 L1	B9 B10	B12 B11 L1	B9 B10	L3 L2 Co S5 S4 S3	L3 L2 Co S5 S4 S3	B9 B10	B12 B11 L1	B9 B10	L3 L2 Co S5 S4 S3	B12 B11 L1	C7 C6 C5 B4 B3 L5 L4	C7 B1 B5 B6 S1 S2 hip	C7 B1 B5 B6 S1 S2 hip
SPINAL CORD SEGMENTS	Th1 C8 Th7 Th6 Th5 S3 S2 S1	C7 C6 C5 Th4 Th3 Th2 L5 L4	Th12 Th11 L1	Th8 Th9 Th10	Th12 Th11 L1	Th8 Th9 Th10	L3 L2 Co S5 S4	L3 L2 Co S5 S4	Th8 Th9 Th10	Th12 Th11 L1	Th8 Th9 Th10	L3 L2 Co S5 S4	Th12 Th11 L1	C7 C6 C5 Th4 Th3 Th2 L5 L4	Th1 C8 Th7 Th6 Th5 S3 S2 S1	Th1 C8 Th7 Th6 Th5 S3 S2 S1
JOINTS	shoulder - elbow	hand ulnar foot plantar toes	anterior knee	posterior knee	anterior knee	hip	posterior knee	posterior knee	posterior knee	anterior knee	hip	posterior knee	anterior knee	shoulder - elbow	hand ulnar foot plantar toes	hand ulnar foot plantar toes
SENSORY ORGANS	ear/retina	ethmoidal cells/nose/olfactory sense	sinus maxillaris/tongue/sense of taste	sinus maxillaris/tongue/sense of taste	sinus maxillaris/tongue/sense of taste	eye/visual sense	frontal sinus/nose/olfactory sense	frontal sinus/nose/olfactory sense	eye/visual sense	sinus maxillaris/tongue/sense of taste	eye/visual sense	frontal sinus/nose/olfactory sense	sinus maxillaris/tongue/sense of taste	ethmoidal cells/nose/olfactory sense	ear/retina	ear/retina

Dental correspondences after taking into account the references according to Bahr-Schmid, Voll-Kramer and the findings of TCM.

Effects of different materials on the body

The cytotoxic well as the negative effects on the metabolism of various metals such as mercury (Hg), gold (Au), platinum (Pt), copper (Cu), cobalt (Co), aluminium (Al), iron (Fe) and chromium (Cr) have been well documented in scientific research⁽¹⁻¹²⁾. Metal components can generally be detected anywhere in the body within a few days of being placed in the mouth. Dr. Karl Ulrich Volz was able to prove this as early as 1992 in his Ulm University dissertation on the “Detection of amalgam invasion into the pulp tissue by means of neutron activation analysis and energy loss spectroscopy”⁽¹³⁾. These metals—in particular the highly toxic amalgam—are so toxic to our bodies because they bind to proteins, enzymes and cell membranes in ionized form (sulfhydryl groups) and can impair their function. This covalent bonding can completely block an enzyme’s function. In addition, metal ions from all dental alloys lyse in an aqueous medium (saliva) and thus corrode. They “rust”, so to speak, which results in the flow of a current that can be measured with simple instruments. Their immunological effect is particularly dangerous, since these different forms of allergies (e.g. type IV) can trigger foreign-body-induced inflammation in the case of titanium, and autoimmune diseases as they delete the MHC code⁽¹⁴⁾. The immune system considers practically every metal to be a foreign body. It forms antibodies against the metal or the combination of metal and surface features of the cell (hapten effect) in a process which plays an important role in the development of autoimmune diseases and neurodegenerative diseases such as MS, rheumatoid arthritis, ALS or Parkinson’s disease⁽¹⁶⁾. For this reason, a key step of the “THE SWISS BIOHEALTH CONCEPT” treatment protocol consists of removing all metal from the oral cavity. It goes without saying that appropriate protection are taken during the removal.

AMALGAM

Amalgam is an alloy which, apart from silver and various other metals, contains more than 50% mercury—the most toxic non-radioactive element on our planet (Fig. 1). Amalgam is not a stable and homogenous alloy, but rather an “intermetallic compound” and assumes a gaseous state at room temperature. Mercury is stored in the liver, kidneys, the CNS, large intestine, the thyroid gland and fatty tissue. The half-life of mercury in the brain is 16 to 30 years⁽³⁾. Amalgam is still routinely used in most dental practices today. Firstly, because it is a material that is easy to handle and has a long service life, and secondly, because it is subsidized by health insurance companies, i.e. it is free of charge for the patient. In practice, amalgam has to be disposed of as highly toxic hazardous waste after its removal—this fact alone should give food for thought. Also, since July 1, 2018, dental amalgam may only be used in exceptional medical cases for children under 15 years of age, pregnant women and nursing mothers throughout

the EU⁽¹⁵⁾. Contrary to common belief, the mercury content, which amounts to more than 50%, is not firmly bound to the alloy once it has been mixed⁽¹⁶⁾. A certain amount of mercury vapor is released daily through chewing, grinding, brushing teeth and hot or cold drinks^(17,18). Although this amount of mercury is in the microgram range, it should not be underestimated, considering that a single mercury molecule can destroy nerve cells⁽⁷⁾. In terms of its toxicity, mercury exceeds all other known elements such as lead, cadmium and arsenic, in some cases many times over⁽¹⁹⁻²¹⁾. Animal studies have detected pathological changes in the brain as early as 14 days after filling insertion^(22,23). Approximately 1- 3 µg of mercury vapor is released daily per filling, and this is done over the entire wearing period of an average of 20 years⁽²⁴⁾. In effect, this constitutes low-dose, chronic poisoning. In numerous studies, a two- to five-fold increase in mercury levels in blood and urine was observed in living amalgam wearers. In studies on deceased patients, Hg levels were found to have increased by as much as two to twelve times in various body tissues. According to these studies, amalgam is the main source of mercury exposure in the human body^(9,1,25-43). Mercury is known to be able to mimic any symptom and is not tolerated by the body for this very reason. The human body is extremely smart and stores fat-soluble toxins in metabolically inactive connective or fatty tissue whenever possible. In athletic people or people with a low percentage of body fat, however, toxins are often deposited in the nerve tissue or brain. Unborn babies and infants being breastfed are at particular risk as mercury crosses the placenta^(44,45). The amount of mercury in breast milk and amniotic fluid clearly correlates with the number of maternal amalgam filling^(29,44-54). As amalgam fillings are the main source of poisoning with

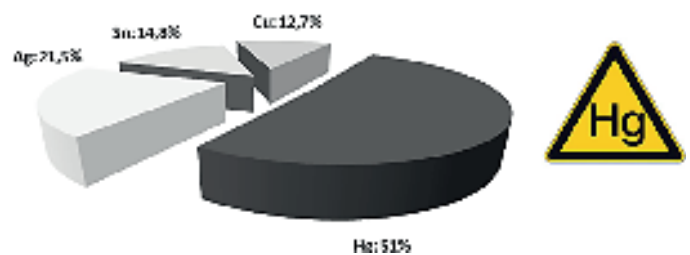


Figure 1: Typical composition of an amalgam filling: 51% mercury (Hg), 21% copper (Cu), 15% tin (Sn) and 13% silver (Ag)⁽¹⁷⁾.

mercury and other heavy metals, they should be removed for preventive reasons, regardless of whether or not the patient is already chronically ill.

DENTAL METAL ALLOYS

Neither gold, nickel, palladium, silver, platinum nor titanium are biologically present in the human organism. However, they are routinely used in dental alloys. This is aggravated by the fact that, according to the German Medical Devices Act (MPG), any components that account for less than 1% of a material do not have to be declared. In contrast to the toxicity of the highly toxic mercury found in amalgam, tolerance of the above-mentioned metals mainly depends on an individual's immune system. Inevitably, these metals are perceived as foreign bodies by the immune system and are tolerated or attacked depending on an individual's defenses. This can lead to mild inflammation, which may, at times, manifest only locally as bleeding gums. Equally, however, it may cause severe allergies or even autoimmune diseases⁽⁵⁵⁻⁵⁷⁾. Unfortunately, the cause of these diseases generally remains unrecognized, and they are treated with symptomatic therapies. This chronic, low-dose activation of the immune system consumes at least 30% of a patient's physical energy every day. Chronic fatigue is therefore not uncommon. In some patients, the immune response manifests itself every morning as limb pain, sluggishness and even as a slightly elevated temperature. They constantly feel "slightly ill", as it were. This situation is exacerbated by the so-called battery effect (different metals acting as galvanic elements (Fig. 2), resulting in an increased corrosion of metal ions and attachment to the body's own proteins, cell membranes and enzymes, as well as the antenna effect of all metals). A typical example is a gold crown next to an amalgam filling or a gold abutment on a titanium implant. The resulting comparatively high dental oral currents cause the metals to corrode during the wearing time, further intensifying the negative effect of these metals. Another problem area is increasing electro-sensitivity due to the exponential propagation of electromagnetic fields generated by Wi-Fis and mobile communications. Nowadays, it is virtually impossible to avoid electrosmog. Metals inside the body act like small antennas⁽⁵⁸⁻⁶²⁾. Voltage fields are created, which considerably disturb the cell's action potential and thus the functioning of the very sensitive central nervous system⁽⁶³⁾. The standard absorption rate of electromagnetic fields can be 400 to 700 times higher when a person with metal in their mouth is using a cell phone (if their phone is ringing or they are receiving a text message)⁽⁶⁴⁾. Metals can scatter, reflect, modulate and amplify electromagnetic radiation in an uncontrolled manner, thus heating up the surrounding tissue. Titanium implants, in particular, which, due to their shape, are especially suited to act as anten-

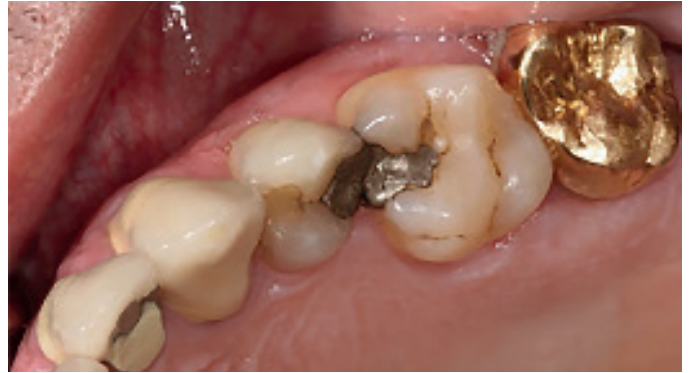

Figure 2: A battery is created when two different metals are placed in a conductive solution. In accordance with the electrochemical voltage series, the less noble metal ions lyse and flow towards the more noble metal. Electrons are released and a current begins to flow. Due to its high mineral content, saliva is an ideal electrolytic solution.

nas, heat up the surrounding bone tissue by several degrees Celsius within 3G or 4G network range. Microwave radiation always causes metals to heat up (think of a metal spoon inside a microwave oven). Electro-galvanism and the resulting electrosensitivity can frequently cause lack of concentration, memory loss, insomnia, unspecific symptoms such as sharp pain or a feeling of pressure in the chest, unexplained palpitations, tinnitus and hearing loss⁽⁶⁵⁾.

TITANIUM IMPLANTS OR SCREWS

According to Dr. Volker von Baehr (www.imd-berlin.de), 15% of the German population suffers from titanium intolerance⁽⁶⁶⁾, which is mainly caused by the extensive use of titanium dioxide as food additive E171. Prof. Vera Stejskal from the Karolinska Institute in Stockholm believes that intolerance levels are even higher. So does Dr. Bernd Bremer, Senior Physician at the Hanover University Medical Materials Science Institute. He estimates that the intolerance level may be as high as 50% and is currently conducting a study on this topic (personal message to Dr. Volz). This correlates with the mucositis/peri-implantitis ratio of 80%, or 28 to 56%, respectively, which resulted from a consensus conference in 2008⁽⁶⁷⁾. Based on his many years of experience, Dr. Volz sees these inflammatory processes as nothing else than the clinical expression of an intolerance. A paper published in Düsseldorf on the occasion of the 2014 annual meeting of the German Soci-

ety for Implantology (DGI) by Freiburg University successfully demonstrated the presence of titanium particles in the surrounding soft and hard tissue in just under 80% of peri-implantitis cases. Recent studies and lectures by well-known authors and speakers such as Prof. Therheyden, former DGI chairman, have also confirmed this and described what they called titanium “rusting”.

This corrosion of titanium surfaces causes titanium oxide particles to detach and infiltrate the surrounding tissue, and may be associated with the development of peri-implantitis and implant loss⁽⁶⁸⁻⁷²⁾. Moreover, particle release may also be a result of mechanical friction during implant insertion and/or micromovements of the loaded implant^(69,73). Macrophages react to titanium oxide particles in tissue with an inflammatory response and release pro-inflammatory cytokines such as TNF- α , IL-1 β ⁽⁷⁴⁾, and RANTES. Osteoclasts are activated and bone and tissue resorption may occur⁽⁷⁵⁻⁷⁷⁾. In addition to the local effects mentioned above, the cytokines released in conjunction with this chronic immune reaction also have systemic effects on many types of tissue such as muscles, the vascular endothelium and the nervous system⁽⁷⁸⁾. Systemic diseases such as rheumatoid arthritis, multiple sclerosis, tumors, breast carcinomas and cardiovascular diseases can be triggered by titanium implants, since pro-inflammatory cytokines are overexpressed⁽⁷⁹⁾. Conversely, zirconia particles of equal size do not induce a significant inflammatory immune response (TNF- α)⁽⁷⁶⁾. A connection with the development of autoimmune reactions is also being examined⁽¹⁾. Furthermore, titanium dioxide nanoparticles are cytotoxic and genotoxic and can cause oxidative stress^(5,80,81). Some studies associate neoplasia such as osteosarcomas, plasmacytomas or metastatic breast carcinomas with dental titanium implants⁽⁸²⁻⁸⁴⁾. Another study detected titanium dioxide particles in regional lymph nodes⁽⁸⁵⁾. As described above, titanium implants—like all other dental metals—act as small antennas for electromagnetic fields. In a clinical study, patients with titanium implants experienced balance disorders caused by the titanium implants’ amplification of electromagnetic waves⁽⁸⁶⁾.

The titanium stimulation test (a blood test) can be used to examine whether there is a pre-existing intolerance to titanium dioxide⁽¹⁴⁾. Inflamed tissue around an implant may already suggest a propensity for inflammation. If this is the case, these implants should be removed during treatment and replaced with fully ceramic implants.

Biological dentistry

“Biological dentistry” refers to dentistry which looks at the human organism from a “bio-logical” perspective. We recognize that the masticatory apparatus is very closely connected to the entire body and is located in the immediate vicinity of eminently important organs. After all, almost all the sensory organs are arranged around our mouths, and the brain is very close by. The importance of the masticatory system is also reflected in the fact that the fifth cranial nerve (trigeminal nerve), which supplies the masticatory system, is the largest cranial nerve⁽¹⁾, occupying 50% of the space of all the cranial nerves.

Another important consideration is the fact that the masticatory system is linked with the entire organism through the system of meridians. These not only run through the dental system but are also constantly activated by the approximately 15,000 tooth contacts we make every day. Toothlessness therefore results in atrophy of the associated meridian, which can only be partially compensated for by treatments such as acupuncture or reflexology. It is therefore vital that gaps between teeth be closed as quickly as possible using neutral ceramic implants so that the affected meridians can be adequately activated once again.

The condition of the temporomandibular joint also plays a major role. It governs the statics of the spinal column as well as blood supply to the brain and venous outflow from the brain. Loss of bite height results in a compression of the region of the large blood vessels in the neck, and can thereby restrict blood flow to the brain⁽²⁾. A loss of just 1 mm in bite height reduces the blood supply to the brain by around 50%! A correlation between loss of bite height and neurodegenerative diseases such as dementia and cognitive disorders has also been found⁽³⁻⁶⁾. Moreover, effective drainage of toxins and waste products from the brain requires the jugular vein to be sufficiently wide. This is all the more important because the brain does not have a lymphatic system with which to remove these substances, instead relying on the glymphatic system to accomplish this task. During the night, our brain cells shrink by up to 60% and thus generate a cavity between the cells through which toxins can drain off^(7,8). This system can only function effectively, however, if all sources of stress are deactivated at night. This includes all EMF sources such as mobile phones, Wi-Fi, etc.

Compared to the oral system, there is no other organ or part of the body that is loaded to such an extent with heavy metals, alloys, toxic materials, dead organs and inflammation. Indeed, dentistry is the only medical discipline which tolerates leaving a dead organ in the body. There is a further serious element causing disturbances that has gained importance in the last decades, as it

affects most people: It lies in the fact that the gum is part of the ectoderm (= outside of the body), whereas the bone is part of the mesoderm (= inside of the body). If we eat something toxic, it remains outside the ectoderm, i.e. on the outside of our body—in the oral cavity, stomach and intestines. Only when it has been absorbed is it located in the mesoderm or endoderm. If the bond between gum (= ectoderm) and bone (= mesoderm) is destroyed, as is the case with periodontitis in the majority of the population, then pathogens and toxins can penetrate the body directly like a Trojan horse. This is a shock to the immune system and is the reason why gum disease considerably increases the risk of heart disease⁽⁹⁻¹³⁾. Ceramic implants boast an outstanding benefit here because gum attaches to the ceramic surface⁽¹⁴⁾, closing the “immunological door” door once again. Conversely, gum never attaches to titanium, which means that titanium implants leave the immunological door open for life.

Taking all of these factors together, it is not surprising that experts estimate that more than 60% of all chronic diseases involve disruptive issues associated with the teeth. At the center of this knowledge about the relationship between disorders in the masticatory system and the rest of the organism lies the concept of “focal infection”. Put simply, this means that there is a nidus/focus of infection or interference field somewhere in the body which can cause a disturbance in a completely different part of the body.

The term “focal infection” was coined by probably the most famous dentist of all time, Dr. Weston Price, who was Head of Research and Education at the American Dental Association (ADA) for over 30 years, and who had long been aware of the need to eliminate these foci⁽¹⁵⁾. His work has been continued by eminent biological dentists and physicians such as Thomas Levy, Johann Lechner, Boyd Haley, Dietrich Klinghardt, Joachim Mutter and many others. Until recently, however, the dilemma was that the necessary “clean-up work” in the mouth often left behind a “field of destruction” with gaps which required further treatment with prostheses and bone augmentation. Patients were often left unable to socialize for weeks, suffered from severe pain and massive swelling, and in some cases spent years trying to regain a reasonable anatomical and esthetic result. This was the handicap of holistic dentistry in the past. Patients understood the need for radical therapy along the road to recovery, but could not be given an optimum result using the solutions available. Biological dentistry provides the answer to this problem, and involves comprehensively recognizing the logical relationships at play, incorporating them into every step in the process, and deriving from them a treatment. As described above concept that is both simple and



Figure 1: Firmly attached gingiva on the zirconia implant in a zirconia-epithelial connection.

highly effective. In the first step, all non-biological or non-neutral materials as well as all dead organ parts and foci of inflammation are removed under maximum protective conditions. During this process, the immune system is activated and not further weakened by the use of chemical drugs. In the second step, the masticatory system is preserved and reconstructed using metal-free and neutral materials, always with the aim of preserving or restoring the anatomy, bone and soft tissue, and thus the esthetics. Implants made of zirconium dioxide (more commonly known as zirconium oxide, or zirconia) play a central role here (Fig. 1).

BIOLOGICAL DENTISTRY VERSUS HOLISTIC/NATURAL DENTISTRY

Prior to the era of biological dentistry with the possibilities which it offers today, a less radical but also less effective discipline was established. Known as holistic or naturopathic dentistry, it attempted to diagnose and alleviate disorders using assessment methods and therapies which were mostly subjective—in other words, they were not reproducible or scientifically proven. For example, metals which had previously been tested continued to be used in the form of “bio-alloys”, and attempts were made to positively influence dental nidi with neural therapy instead of removing them. Successes were certainly achieved, but they could not compensate for the extent to which the masticatory system is involved in chronic disease. Biological dentistry requires excellent, highly-experienced surgeons who are capable of carefully removing complicatedly displaced wisdom teeth, inflammation or foreign bodies near nerves or maxillary sinuses or extremely ankylotic root-treated teeth while preserving the bone. In the past, surgeons trained and working at a high level were not particularly fond of “holistic dentistry” and usu-

ally dismissed it as an esoteric trend. Then again, holistic dentists had not undergone the surgical training that would have enabled them to radically eliminate the aforementioned disorders surgically instead of merely trying to alleviate them. Fortunately, some major changes have taken place since. An ever increasing number of experienced oral surgeons and maxillofacial surgeons are implementing the SWISS BIOHEALTH CONCEPT—first formulated and tested in detail by Dr. Volz—in their practices and clinics and offer not only ceramic implantology, but also wisdom tooth removal according to this concept, to give one example.

THE SWISS BIOHEALTH CONCEPT

Thanks to Dr. Volz’s biological dentistry concept, we have since 2001 been able to restore the gaps left behind by radical reconstructive surgery in a completely neutral and metal-free manner using the ceramic implants developed by Dr. Volz himself. Since the introduction of the SCC SHORT CUT CONCEPT according to Dr. Volz in 2014, we have for the first time in dental history been able to fill these gaps with of ceramic implants and fixed restorations (Fig. 2) in a single course of treatment—sometimes even in a single session—without the patient having to endure significant pain or swelling but instead being fit and feeling presentable again in just a few days. At the same time, the anatomy, bone and gum are preserved, thus respecting the principle of physical integrity. Our best “proof of concept” lies in the fact that Dr. Volz’s largest group of patients are dentists themselves, particularly implantologists, closely followed by alternative practitioners, doctors of biological medicine and therapists. What these professionals recognize is the fact that our immediate implant protocol offers a solution to a problem which has been central to dentistry for over 100 years, namely how to thoroughly eliminate interference fields and treat the inevitable gaps in a biocompatible way that patients approve of and gladly accept.

Countless patients who knew that they needed therapy but were not prepared to accept the solutions on offer or who did not get adequate care are now receiving help in practices and clinics that offer the SCC Short Cut Concept according to Dr. Karl Ulrich Volz, and the ALL IN ONE CONCEPT which is part of SWISS BIOHEALTH CONCEPT.

THE ALL IN ONE CONCEPT AND MY BIOHEALTH WEEK

In 2016, the SWISS BIOHEALTH CLINIC was established as a logical continuation of Dr. Volz’s concept and based on his 30 years of experience. The ALL IN ONE CONCEPT introduced there makes it possible to eliminate all of a patient’s dental problems in just a single session or series

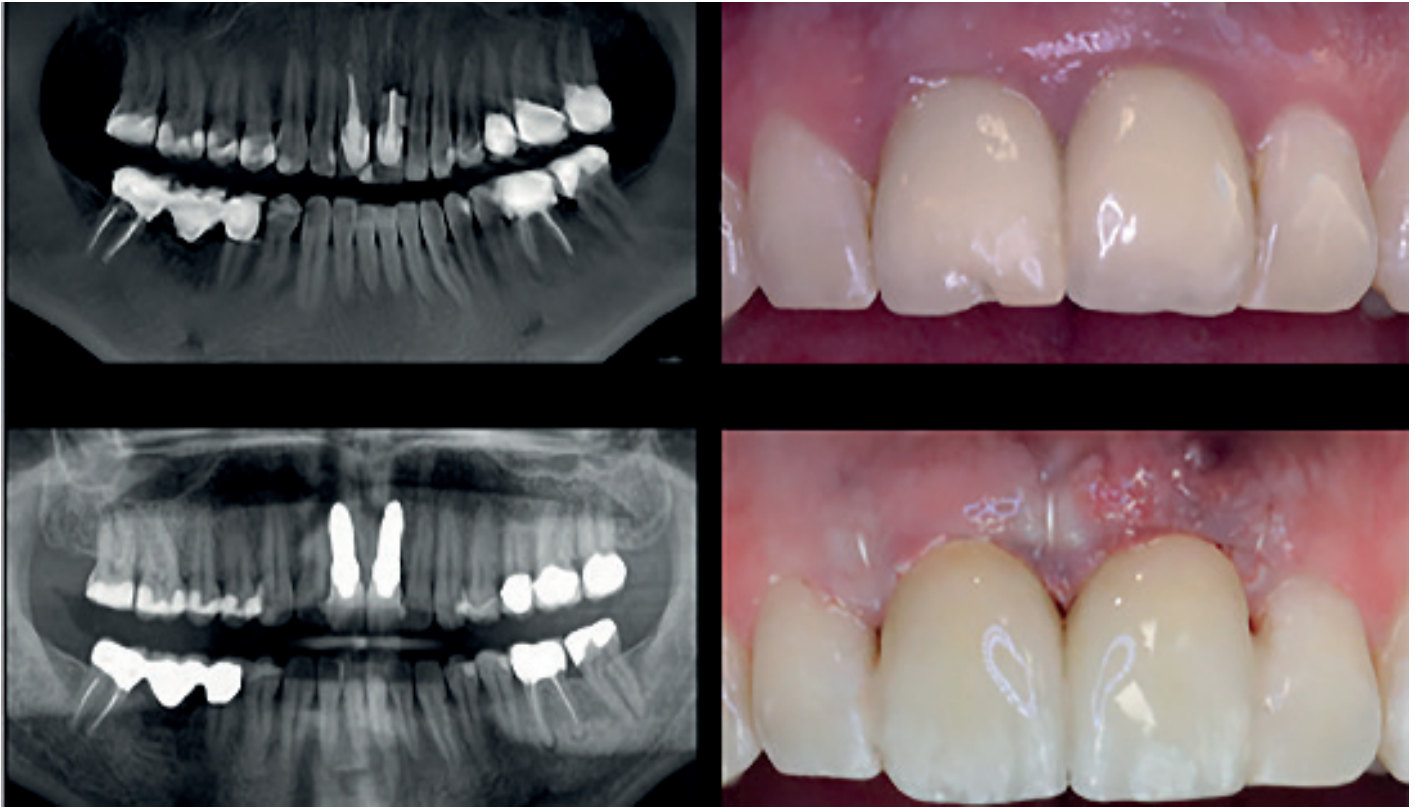


Figure 2: Removal of the two central incisors (top) with immediate implant placement and immediate temporaries (bottom). The patient's disc symptoms disappeared immediately after surgery. Moreover, the temporary restoration (bottom right) was more visually appealing than the previous ceramic crowns (top right).

of sessions as part of the My BIOHEALTH Week. This is key because the immune system can only function in an optimum manner once all potential problematic factors like metals, osteonecrosis, root-treated teeth and other fields of interference have been completely removed, thus eliminating systemic stress. It is all the more important because ceramic implants are completely neutral and will only be assimilated into healthy bones by a functioning immune system. By contrast, titanium implants heal by releasing inflammation mediators in the sense of chronic inflammation and thus also in compromised bone (as described on page 32).

Peri-implantitis does not occur with zirconia ceramic implants, which justifies the greater effort and expenditure required prior to implant placement. Our highly consistent ALL IN ONE CONCEPT delivers success rates of around 98% at the SWISS BIOHEALTH CLINIC, a positive side-effect being that patients complete the entire treatment in one session or series of sessions. This concept makes it possible to lay the foundation for a major

improvement in health as quickly as possible, enabling patients to leave the clinic with fixed and esthetic temporary restorations. The following figures (see Fig. 3 and 4 on the following pages) illustrate the typical scheme of treatment in accordance with THE SWISS BIOHEALTH CONCEPT, and explain how patients have to prepare for surgery and what they need to do in the weeks after surgery. The underlying protocol has been developed over many years by internationally recognized specialists in biological medicine and dentistry. In very simple terms, the objectives of THE SWISS BIOHEALTH CONCEPT can be defined as partnering with immunology; working in a radical but stress-free (atraumatic), preventive and minimally invasive manner from an early stage, thus avoiding swelling and pain; reaching the goal in as few sessions as possible to minimize the time the patient is out of action; using as few foreign materials as possible and—if any are required—keeping them as biologically compatible as possible, as well as keeping the patient in a parasympathetic tone throughout the therapy to the greatest extent possible.

Medical history and findings

It goes without saying that all standard aspects of a dental examination and diagnosis are respected. This includes medical history, findings, X-ray, functional examination, impression-taking, etc.

DVT

A three-dimensional X-ray image (digital volume tomography, DVT) must be carried out to detect and localize inflammation ischemic osteonecrosis (FDOJ and foreign bodies, e.g. metal splinters).

LDL and vitamin D3 analysis

A high LDL level (low density lipoprotein, the “bad” cholesterol) above 1.2 g/L indicates a high susceptibility to inflammation. Reducing elevated LDL levels therefore constitutes a further important measure. Within the general population, LDL increases are mainly due to our bodies reacting to increasing levels of electrosmog. LDL has a counterproductive effect because it increases the risk of inflammation and impairs bone healing⁽²⁰⁾. We recommend using the following protocol—agreed with Dr. Klinghardt—to reduce LDL levels:

- Chlorella (20 pellets three times a day)
- Niacin (500 mg one to three times per day)
- Acetyl-L-Carnitine (1,500 mg morning and evening)
- A high-dose micronutrient supply for at least three months with BASELINE and BOOST (Fig. 9)

A low vitamin D3 level below 70 ng/ml (25(OH)D3 being measured) reduces the body’s ability to form healthy bone and correlates with a weakened immune system⁽¹⁶⁻¹⁹⁾.

Additional lab tests

Further tests can be carried out. They do however branch out far into the medical field and should, if they are needed, be carried out with the support of a physician/naturopath: They include tests for micronutrients, IgG4 food intolerances, porphyrins, nitrosative stress, HPU/KPU analysis, genetic tests, stool analysis, etc.

Titanium intolerance tests

As regards the general EMF exposure, which will increase yet again as a result of the introduction of the mobile 5G network, we recommend removing all titanium implants, especially with preexisting chronic diseases. Cell phone use within a 3G/4G network results in the temperature of the bone in the vicinity of a titanium implant increasing by up to 4°C! A study also showed that excessive cell phone use can impair bone maturation around implants and delay osseointegration⁽²⁰⁾. As a rule, testing for titanium intolerance (Melisa test, titanium stimulation test) within the framework of THE SWISS BIOHEALTH CONCEPT is therefore not necessary.

Meridian analysis

Once sources of inflammation and foci have been identified on a 3D image, they are “matched”, i.e. associated with the patient’s general symptoms with the help of the meridian system (see p. 20 and 21). We always—and in all patients—find an accumulation of general medical symptoms on the meridians which run through areas of inflammation or other interference fields.

Neural therapy simulation

The correlations identified can now be simulated, so that they become tangible and comprehensible for the patient. The injection of procaine around the suspected tooth is an instrument perfectly suited to convince the patient of the necessity of rehabilitation and to determine in advance whether the biological-dental therapy will result in a general physical improvement. As a rough guide, the actual improvement will be about twice as strong as the improvement that can be achieved through simulation (for further information see p. 23).

Pre- and post-treatment principles

Given the standard that modern medicine has reached in the 21st century, it seems anachronistic to automatically prescribe oral antibiotics after dental surgery, to prescribe a chlorhexidine mouthwash and to tolerate massive swelling over many days. This approach stems from a mechanistic approach, according to which bacteria must be fought and killed, without any consideration of side effects.

Oral antibiotics (anti bios = against life) lead in various ways to lysis (dissolution) of the bacteria’s cell membrane, with the result that enormous amounts of endotoxins (i.e. the intestinal contents of the lead so to speak) are released into the body, which can lead to side effects as severe as septic shock⁽²¹⁾. Furthermore, patients feel weakened when taking oral antibiotics and often suffer from diarrhea and vomiting as valuable intestinal bacteria can get destroyed. They may also suffer fungal infections of the intestines or genitals as the bacteria which normally keep fungi in check are eliminated. We have also observed an increase in levels of fungi in the oral cavity after the use of chlorhexidine. Furthermore, the ill-considered and routine use of oral antibiotics promotes the development of resistance and reduces their life-saving value in the event of truly serious diseases⁽²²⁾. This is why biological dentistry focuses on strengthening the immune system, local sterilization and activation of bone healing with natural or intravenously administered substances in order to avoid the aforementioned problems. When administered intravenously, antibiotics do not have the above mentioned negative side effects and concomitant symptoms.

The My BIOHEALTH Week scheme

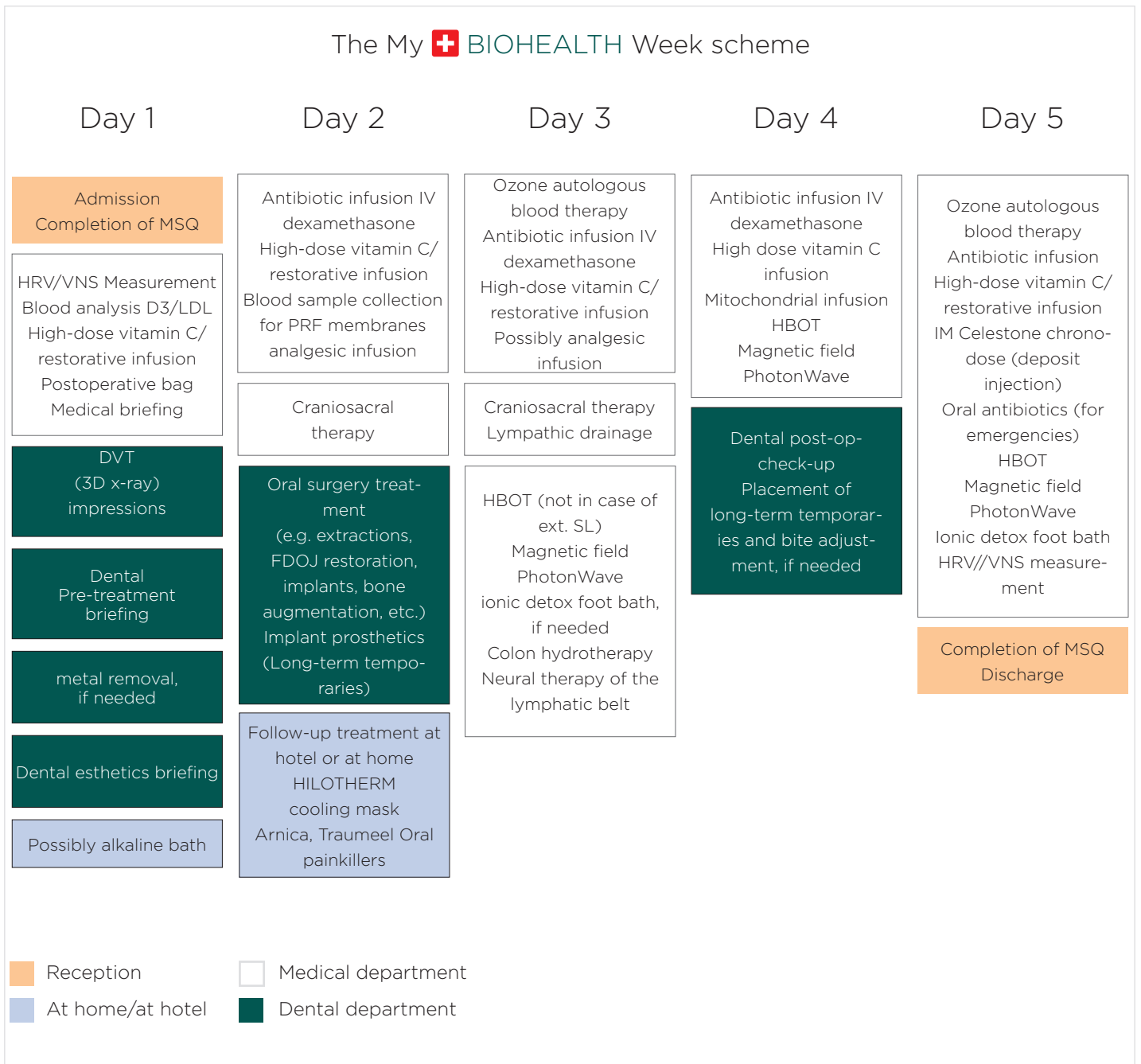


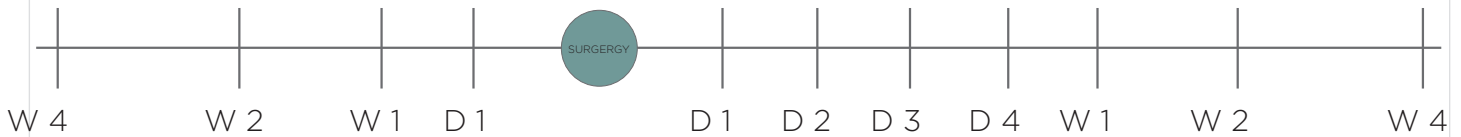Figure 3: The My BIOHEALTH Week scheme according to the THE SWISS BIOHEALTH CONCEPT system

Complementary recommendations regarding My  BIOHEALTH Week

MICRONUTRIENT BALANCING: high dose vitamin D3, K2, C, magnesium, etc.

DIET: vegetables (raw, cooked), nuts (no peanuts) avocado, coconut oil, smoothies, broth

AVOID: dairy and animal products, sugar, starch, alcohol, smoking, W-Fi, cell phone



My  BIOHEALTH Week

Plenty of sun exposure, exercise, sleep

No sun exposure, no sports, no sauna

Sun exposure, sports, sauna

Complete rest, no work

Continue resting

Drainage

Figure 4: Complementary recommendations regarding My BIOHEALTH Week

We must also be aware that although our bodies are naturally designed to thrive, they sometimes no longer function properly because we have strayed too far from nature. In evolutionary terms, we were intended to live unclothed in the equatorial region of our planet, thus receiving a sufficient supply of vitamin D3 from the sun, leading a physically active life, roaming in the wild and feeding on fresh natural products which would provide us with sufficient amounts of all the vitamins (especially vitamin C), minerals and other micronutrients we need. An explanation of the most important micronutrients can be found in the section starting on page 54.

The micronutrient protocol

The micronutrient protocol according to Dr. Klinghardt and Dr. Volz ensures an optimal supply of minerals and vitamins prior to surgery. This is achieved by taking one sachet each of our BASELINE and BOOST preparations per day (Fig. 5-7). Patients are required to start taking the preparations two to four weeks prior to surgery and to continue taking them for another two to four weeks afterwards, thereby enabling the body's stores to be filled to the maximum without any risk of overdosing due to the relatively short treatment period of one to two months. The simple dosage form in blister packs containing the exact dosage makes it quick and easy to take the supplement correctly, and is convenient for people who travel regularly. Setting in no later than two to three days after taking them, patients have more energy and their bodies are better able to regenerate thanks to deep, restful sleep.

Importance of micronutrient balancing with periodontitis

Our consistent application of the protocol described above in the SWISS BIOHEALTH CLINIC has enabled us to observe that not only do the implants of almost all

patients who follow this protocol and take the BASIC IMMUNE mixture heal without complication, but preexisting manifestations of gum inflammation have completely disappeared by the time patients arrive at our clinic for surgery. This clearly disproves the official thesis that gum inflammation (periodontitis) is due to poor dental hygiene and shows that these patients are being unjustifiably stigmatized. We postulate that periodontitis is the "scurvy of the 21st century" and is caused by micronutrient deficiency (especially vitamin D and vitamin C), which leads to gum inflammation⁽²³⁻²⁸⁾. The resulting pain and sensitivity to touch causes the patient to stop brushing adequately. Plaque buildup is therefore the consequence rather than the cause of periodontitis and not the other way around!

Single shots

To manage the inflammatory response related to surgery, single shots should be given intravenously prior to surgery and on the three days following surgery. They consist of 1.2 g (for women) or 2.4 g (for men), respectively, of co- amoxicillin in 50-100 ml NaCl as an infusion (600 mg of clindamycin in case of penicillin allergy) and a separate single shot of 8 mg of IV dexamethasone. These drugs are administered to prevent the "bad inflammation caused by giant cells, which is associated with tissue destruction. "Good inflammation" based on macrophages, leucocytes, lymphocytes and monocytes, which leads to the formation of new and healthy tissue, will not be affected. It is important to ensure that all intravenous administrations are carried out prior to surgery so that the PRF (see section starting on p. 86) and blood clot, which is stored in void spaces (extraction sockets, FDOJ cavities or maxillary sinuses) but has no contact with the bloodstream until vascularization, is already "loaded" with the valuable substances. The administration of cortisol (dexamethasone) has become increasingly important in recent years, since more than 50 percent of people living in Western industrialized nations now suffer from adrenal fatigue, which means that they can no longer produce sufficient amounts of the body's own cortisol and are particularly at risk of wound-healing disorders and other complications⁽²⁹⁾. This adrenal weakness is triggered by years of stress-related overproduction of cortisol⁽³⁰⁾, which eventually leads to a loss of the ability to produce cortisol at all (the tank is empty). This also alters the production of other hormones in the adrenal cortex - with serious consequences for the health and performance of the affected individuals. We suspect that some 95 percent of our patients now suffer from this weakness. You can request the Adrenal Fatigue Questionnaire in the SWISS BIOHEALTH CLINIC to determine your risk easily and free of charge.



Figure 5: BASELINE and BOOST

Infusion therapy

Throughout the treatment week, patients receive various infusions on a daily basis. In addition to infusions containing 15 g of vitamin C (which should always be done separately), there will be restorative infusions containing procaine, magnesium sulfate, sodium bicarbonate and vitamin B12. It is important not to use isotonic saline solution as a basis, as it retains water in the kidneys, but to use isotonic Ringer’s solution instead. Towards the end of the procedure, the infusion therapy is ended with an analgesic infusion. The patient should not feel severe pain at any stage, as this would activate the sympathetic nervous system and undermine the immune and healing mechanisms⁽³¹⁾. For minor procedures, 1 g of Paracetamol is sufficient, for major or prolonged procedures, infusions of 2.5 g of Novalgin® over a period of 20 to 30 minutes are recommended. A so-called mitochondrial infusion is administered on the postoperative days.

SUPPLEMENT FACTS		
Serving Size: 1 Sachet		
Serving per Container: 30		
	Amount per Serving	% DV
Calories	6	
Total Fat	0.6 g	<1% [^]
Vitamin A (as retinol)	850 mcg	94%
Vitamin C (as calciumascorbate)	450 mg	500%
Vitamin E (as d-alpha-tocopherol)	120 mg	800%
Vitamin D3 (as cholecalciferol) (1,000 IU)	25 mcg	125%
Magnesium (as magnesium citrate)	250 mg	60%
Zinc (as zinc bisglycinate)	5 mg	45%
Vitamin K2 (as menaquinone-7)	12 mcg	*
Omega-3 Fatty Acids (from fish oil)	580 mg	*
EPA (eicosapentaenoic acid)	150 mg	*
DHA (docosahexaenoic acid)	65 mg	*

[^] Percent daily values based on a 2,000 calorie diet
 * Daily Values (DV) not established

Figure 6: BASELINE ingredients (amount per sachet)

Cooling with HILOTHERM

The most important postoperative measures include hilotherapy by means of a device which the patient should apply continuously over a period of 72 hours postoperatively (Fig. 8). If used consistently, this device can prevent postoperative pain and swelling to a large extent. The success of this measure is based on the principle that after surgery, the oxygen and nutrient demand increases considerably, which leads to an increase in the metabolic rate with subsequent overheating of the tissue due to inflammation. This in turn increases the overall oxygen requirement, and the amount of oxygen available is no longer sufficient for regeneration, resulting in reduced blood circulation (ischemia) and lack of oxygen supply.

SUPPLEMENT FACTS		
Serving Size: 1 Sachet		
Serving per Container: 30		
	Amount per Serving	%DV
Calories	6	
Total Fat	0.6 g	<1% [^]
Vitamin B6 (as pyridoxal-5-phosphate)	14 mg	824%
Vitamin B12 (as methylcobalamin)	80 mcg	3333%
Vitamin C (as calciumascorbate)	450 mg	500%
Vitamin D3 (as cholecalciferol) (1,000 IU)	25 mcg	125%
Folic Acid (as methylfolate)	700 mcg DFE	175%
Magnesium (as magnesium citrate)	250 mg	60%
Vitamin K2 (as menaquinone-7)	12 mcg	*
Coenzyme Q10 (as ubiquinol)	100 mg	*
Omega-3 Fatty Acids (from fish oil)	580 mg	*
EPA (eicosapentaenoic acid)	150 mg	*
DHA (docosahexaenoic acid)	65 mg	*

[^] Percent daily values based on a 2,000 calorie diet
 * Daily Values (DV) not established

Figure 7: BOOST (amount per sachet)



Figure 8: Practical application of the HILO THERM mask

The consequence is cell death and formation of edema—a vicious circle. The damaged tissue's oxygen demand therefore needs to be reduced. This can be achieved by cooling the tissue using the HILO THERM cooling mask. Cooling of the tissue by 10°C will reduce the metabolic rate by 50%; cooling by 20°C (from 37°C down to 17°C) reduces it by 75%. As a result, the available oxygen will be more than sufficient. However, the temperature must not fall below 15°C, as this would cause lymph congestion, preventing the removal of toxins⁽³²⁾.

Concomitant homeopathic medication

Homeopathic medicines can be administered in the following postoperative situations:

- Arnica C30 in all cases before and after every surgical intervention
- Belladonna C30 to relieve swelling
- Bellis Perennis D6 and C30 to reduce hematomas
- Hypericum C30 in the event of nerve injuries and paraesthesia
- Apis C30 in the event of an allergy, irrespective of its severity, in addition to the prescribed general medical measures

Prophylactics given to patients before discharge

Before being discharged from the clinic, patients should be given the following prophylactics to take away with them. These should however only be taken in the event of complications and only after prior consultation with the treating dentist:

- Augmentin: 625 mg for oral administration twice daily
- Prednisolone: four 20 mg tablets for a tapered therapy according to the following daily dose pattern: 20-20-10-10-10-5-5

Complications occur—if at all—almost exclusively on weekends! This is not due to Murphy's Law, but rather to the increased parasympathetic activation as people relax at weekends. The provision of prophylactics eliminates the need for the patient to obtain a prescription and then

search for an emergency pharmacy, thus preventing unnecessary stress and wasted time all round.

CONTINUING TREATMENT

Principles of detoxification

A highly effective detoxification procedure is key in ensuring lasting outstanding and delivering the greatest health improvements for the patient, especially after the removal of amalgam or other metals or after surgical interventions in general. It is important to distinguish between non-specific detoxification therapies and specific therapies that can only be carried out after a medical examination and diagnosis and under medical supervision.

Non-specific general detoxification therapies are initiated during My BIOHEALTH Week, and any patient can and must undergo them after a surgical procedure. This includes the intake of sufficient fluid—at least two to three liters of purified water per day. Ionic foot baths according to Dr. Klinghardt as well as intestinal cleansing (colon hydrotherapy), ideally in combination with special intestinal massages, are also very beneficial in promoting detoxification.

The factor of diet

It is also very important to maintain a healthy diet, avoiding a renewed intake of harmful substances, and to eat vegetables (raw or cooked), nuts (but not peanuts because of the aflatoxin they contain), avocados, coconut oil, smoothies and broths. Dairy products and other animal proteins need to be avoided for several weeks, as well as sugar, starch, alcohol and smoking.

The factor of EMF

The influence of EMF on detoxification efficiency has been vastly underestimated in the past. The influence of EMF on detoxification efficiency has also been vastly underestimated in the past, as Dr. Volz showed in a DETOX EXPERIMENT in 2010. He brought together 20 patients, some of them severely ill (with conditions including ALS, cancer, Alzheimer's, Parkinson's and MS), and 20 well-known biological doctors including Dr. Dietrich Klinghardt, Dr. Christfried Preußler, Dr. Joachim Mutter, Dr. Christof Plothe, HPU specialist Dr. Tina Ritter, Prof. John Ionescu and others in a completely EMF-radiation-free area in Brazil. Thus, a "digital sabbatical" of at least 5 days postoperatively is an absolute must to avoid hampering the detoxification and healing process.

The factor of sleep

Since detoxification takes place during sleep, primarily at night, due to liver activity and the shrinking of brain cells^(7,82), it is of particular importance to protect the bed-

room as much as possible. This is achieved by switching off all EMF sources (smartphones, Wi-Fi, etc.), using protective plugs such as VIVOBASE, or placing radiation protection canopies over the bed. Deep, restful sleep is a prerequisite for good regeneration and detoxification, because it is during the deep sleep phase that cells repair and molt, the energy supply is replenished, the immune system is activated, human growth hormones (HGH) are formed and new muscles develop. Bite height plays an extremely important role in the detoxification of the central nervous system via the glymphatic system (see p. 38) and the drainage of toxins through the large neck veins (jugular vein) at night⁽⁷⁾. A reduced bite height leads to a constriction of neck veins and impaired drainage of the lymph. The sleep hormone melatonin is a key factor in good sleep. As soon as dusk sets in, molecules formed in the eye send out signals to the diencephalon, prompting it to produce melatonin from the feel-good hormone serotonin. Melatonin is mainly produced by the pineal gland and is only released into the bloodstream at night as part of our circadian rhythm⁽³³⁾. Cortisol and insulin have a particularly negative effect on deep sleep because they antagonize melatonin production^(84, 85), a prerequisite for the deep sleep phase. Thus, stress severely impairs nocturnal sleep as it releases cortisol⁽³⁶⁾. Any screen activities in the evening, especially those involving blue light, should be avoided, as this type of light stimulates cortisol production and largely destroys the sleep-promoting melatonin^(37, 38). Sports activities which increase body temperature shortly before bedtime are not recommended. The same goes for late suppers with heavy consumption of short-chain carbohydrates, coffee, green tea or chocolate, as these increase the release of cortisol, adrenaline and insulin and interfere with sleep. A healthy intestine is important for sleep because the microbiome produces neurotransmitters such as dopamine, serotonin and GABA, which improve deep sleep. A healthy and balanced diet is very important a stable and diversified intestinal flora (intake of pre- and probiotics). Micronutrients that favor good sleep include vitamin D3⁽³⁹⁾, Omega-3 fatty acids⁽⁴⁰⁾, vitamins E, B3, B6 and magnesium⁽⁴¹⁾. The consumption of nuts (with the exception of peanuts) is particularly recommended because they contain tryptophan, the precursor of serotonin. Furthermore valerian, lavender, passiflora, ginkgo biloba, St. John's wort and ashwagandha (*Withania somnifera*) have a calming effect on our organism and promote deep sleep. Also worth mentioning is Swiss stone pine wood, as its essential oil can have a calming and sleep-promoting effect.

The factor of bite height

Bite elevation is another important and extremely effective detoxification measure. Ideally, it is tested with the Autonomous Response Test (ART) according to Dr. Kling-

hardt before any surgical intervention. This test makes it possible to identify the bite height that not only opens the jugular veins, as described above, thus increasing detoxification efficiency, but also places the patient in a deep Yin state, i.e. the parasympathetic tone. The correct bite height will already be built into the long-term temporary in the event of a complete restoration, or alternatively achieved by wearing a detox splint on the lower jaw at night. In addition to opening the lateral jugular vein, the bite correction also improves the blood supply to the brain⁽²⁾.

Further principles

In addition to the widely-known detoxifying agents MSM and zeolite, chlorella is an important detoxifying tool. The recommended dose is 20 tablets three times per day (Fig. 9). Also advised is sweating from the third postoperative day onwards by means of regular sauna sessions, preferably using an infrared sauna, to promote detoxification.



Figure 9: Chlorella Vulgaris

Continuation of micronutrient therapy

It is important to complement the intensive micronutrient balancing in the weeks before and after surgery by taking lower doses on a permanent basis. Since a sufficient supply of micronutrients is no longer available from our food due to the leaching of our soils and because our stressful lives increase our nutrient requirements, people in industrialized Western countries need to supplement daily and routinely with the most important substances such as minerals and vitamins. This is achieved by a continued intake of BASELINE and BOOST at lower dosages, depending on individual needs (clinical situation, stress levels, etc.). It is however important to understand that prior to this maintenance dose, the body's stores must always be replenished based on the above protocol. Nobody will deny that our stress levels have increased significantly in recent years due to adverse factors such

as environmental pollution, electrosmog, consequences of nuclear accidents, digital overload and the pressure resulting from being expected to be permanently available. Unfortunately, increasing stress means that we require an ever increasing amount of nutrients.

Orthopedics as a factor with gait patterns and shoe insoles

Since the start of this year, working under the stewardship of Tom Platzer, we have had the possibility to integrate gait patterns and shoe insoles in our concept, allowing us to also take account of ascending chains, starting at the foot. This work is performed under the *Walk in Balance* brand, an outstanding concept for providing people with orthopedic insoles according to their foot and gait analysis. It deliberately differs from common therapy concepts found at traditional medical suppliers and sets standards in terms of analysis and production for a health-conscious target group. The basic idea is to use a foot and gait analysis to identify the causes of physical imbalances, poor posture and discomfort with the objective of restoring mobility, alleviating pain and making movement pleasurable once more with an individual insole fitting. This optimizes what the affected individuals are capable of and also prevents long-term damage. Two main factors contribute significantly to making *Walk in Balance* one of the leading concepts for the provision of insoles following a foot and gait analysis: Firstly, a large number of dedicated, highly qualified specialists work together hand in hand under the brand umbrella. And secondly, specialist knowledge is exchanged between experts, doctors, therapists and professional athletes from a wide range of disciplines. This grouping and networking of specialists is unique. The analysis procedure is underpinned by scientific knowledge gleaned from the field of biomechanics, an orthopedic diagnostic process and experience spanning decades. Movement and sports scientists examine walking/running and gait patterns using state-of-the-art technical aids.

This involves a targeted search for the causes of discomfort and pain as part of a kinesiological walking/running analysis. The insoles are produced with computer-milled perfection and are finished with loving handwork, providing all the quality you would expect from a product "handmade in Switzerland". The insoles can be made for anyone in line with their specific needs. The everyday insoles are specifically designed for elegant footwear, with a comfortable fit being of particular importance. The insoles can be made extra thin and light to ensure they also fit in fine footwear. With this in mind, *Walk in Balance* has developed a special business line that also meets specific requirements encountered in everyday life. The sports insoles use specially developed materials in the

base and cover of the insoles. Individually appropriate measures are taken depending on the sport in question, the load and the specific complaint. The aim is to find an individual solution for each patient. The insole fitting should actively assist the foot in performing its function rather than only offering static support. The management attaches the utmost importance to ensuring that all materials used are of an outstanding quality and to providing a custom-made product. The custom insoles have been specially developed and are produced using high-quality materials with milling machines, grinding machines and by hand. Both orthopedic requirements and individual wishes are satisfied by the choice of materials for the insoles. The production process is rounded off by finishing touches performed by hand and the specific insole surface. The foot profiles are then stored in a database and form the basis for any further insoles produced in the future.

Intestinal rehabilitation and amino acids

The rehabilitation of the intestinal flora and the synthesis of amino acids can be restored. Supplementation with amino acids (fig. 10), probiotic and prebiotic substances strengthen about 80% of our immune system that is related to the gut. The basis of the therapy should involve for example probiotic substances such as selected bacteria cultures (concentration of 2 billion bacteria per serving), as well as amino acids like glutamine in a daily dose. A regular intake of amino acids is especially important after surgical interventions, for all patients, especially those who practice intense sports. Prebiotic substances can also be used, for example psyllium husks, fructooligosaccharides and solar fiber.

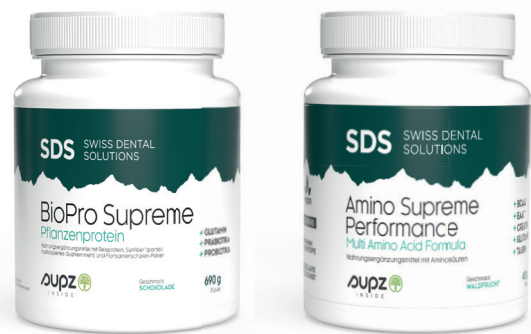

Figure 10: BioPro Supreme and Amino Supreme Performance

An amino acid supplementation is preferable when it is sugar free and contains BCAAs (branched chain amino acids) as well as all EAAs (essential amino acids), taurine, glutamine, creatine, beta-alanine, tyrosine and ornithine-L-aspartate. In addition, it is important that to have additional magnesium in the form of magnesium malate. Particularly after surgery, the body has an increased need for amino acids since these are needed to rebuild tissue and for the functioning of cells and enzymes. An increased supply of amino acids also accelerates detoxification. In phase II metabolism that takes place in the liver, amino acids are added to toxins, such as heavy metals, allowing them to be eliminated more easily from the body. Amino acids are also necessary for the formation of neurotransmitters, and thus improve the chemical communication between cells throughout the body, improving brain function, endocrine system balance, and overall health.

Specific detoxification therapies

Depending on the individual situation (clinical picture, toxic stress situation), a specific detoxification therapy can be performed. It includes the specific prescription of drugs, minerals and vitamins, usually after a blood test, a mercury/heavy metal mobilization test and an ART (Autonomous Response Test) according to Dr. Klinghardt. Likewise, mercury drainage using DMPS (di-mercapto-propane-sulfonic acid) may only be carried out under medical supervision. Neural therapies with a mixture of DMPS and procaine in ganglia and other areas must be carried out in a targeted manner.

Importance of micronutrients in dentistry

An increasing loss of minerals and vitamins in all types of fruit and vegetables has been observed. Leached soils, air pollution, modern processing methods and storage as well as long transport routes and storage have resulted in a drastic loss of valuable substances in our food over the past 50 years⁽¹⁾. Nowadays, you would have to eat ten times as much fruit and vegetables to get the same level of nutrients as 50 years ago.

Vitamin D3, vitamin K2, vitamin C and magnesium are probably the most important micronutrients—which is why we call them the “fantastic four.” They play a prominent role in dental health and bone metabolism. We also present the most important information about vitamin A. Together with vitamins D3 and K2, it is one of the three micronutrients which Dr. Weston Price found to be of extraordinary importance for both general and dental health.

VITAMIN D

Strictly speaking, vitamin D is not a vitamin, but a hormone in its active form. It is only in recent years that people have started to recognize how important vitamin D is for the human body, with its significance stretching far beyond bone health.

Occurrence and supply

Our food contains only small amounts of vitamin D3 (cholecalciferol) as the most important precursor of vitamin D. Only cod liver oil has a significant value of 12'12 I.U. per 100 g⁽²⁾. This is why only 20% of vitamin D3 comes from the intake of food⁽³⁾, as its content in fatrich fish species, such as salmon and herring, milk⁽⁴⁾, porcini, shiitake mushrooms and avocados is much lower⁽²⁾. The skin produces 80% of our vitamin D3 by converting its own 7-dehydrocholesterol. UV radiation is required to convert this substance into the previtamin D3 by photolysis⁽⁵⁾. Our skin's 7-dehydrocholesterol content decreases ever more with age. Older people's ability to form D3 in the skin is also reduced by more than half compared to 20-year-olds⁽⁶⁾. On a sunny day, humans produce about 10,000–20,000 I.U. (International Units) of vitamin D3 per hour⁽⁷⁾

Unfortunately, in reality, we usually spend the entire day fully clothed in closed rooms far away from the equator with its intense vitamin-D-forming sunlight, without any exercise, and therefore have a reduced metabolism. When we do go out into the sun, we “protect” our body from absorbing vitamin D3 with sunscreen.

When using a cream with a sun protection factor, SPF 8 is sufficient to reduce vitamin D3 production by more than 97%⁽⁸⁾. Unfortunately, widespread obesity is another factor contributing to reduced vitamin D3 absorption, as it is

then formed in the skin but cannot be released into the blood. Consequently, obese people more frequently have vitamin D deficiency^(9–11). Our vitamin D levels are also dependent on the latitude where we live. For example, the vitamin D levels of people who live in equatorial regions are the highest (40 ng/ml) and much higher than those who live further north or south of the equator⁽¹²⁾. It is important to note that the population of countries north of the 40th parallel (in Europe: north of Rome) cannot produce sufficient vitamin D from October to March⁽¹³⁾. Cloudiness and the angle of incidence of the sun both impact the absorption of UVB radiation^(7,14). If the angle is less than 45°, the path for the sun's rays through the ozone layer is too long for vitamin D to be produced, since the ozone layer absorbs part of the UV radiation.

The website www.timeanddate.com enables you track the hours of sunshine along with the angle of incidence for any place in the world. For example, on January 11, 2018, in Oslo (40th latitude), there was no time of day when the sun was at an angle of incidence greater than 45°. In Tel Aviv (32nd degree of latitude), on the other hand, optimal vitamin D production was achieved between 9:28 a.m. and 4:03 p.m. on January 11. An app is available for mobile phones (Dminder by Prof. Holick), which shows precisely how many I.U. of vitamin D3 can be produced at what time of day and within what time frame. There is a simple rule of thumb to remember: If your shadow is longer than your height, no vitamin D3 can be produced⁽⁷⁾.

As a result of today's predominantly indoor lifestyle, the majority of the population now suffers from vitamin D deficiency^(15,16). Unfortunately, 60% of the German population has levels under the lower limit of 30ng/ml⁽¹⁷⁾, which means that they are in a state of “immunological hibernation” and are not capable of healing bones and wounds completely and without complications. In a recent pilot study conducted with medical staff at a university hospital, the situation was even more dramatic. Of 24 participating individuals, 85.7% had vitamin D deficiency with a level below 30 ng/ml had as low as below 10 ng/ml⁽¹⁸⁾.

Physiological significance

The precursor substance 7-dehydrocholesterol is converted into vitamin D3 (cholecalciferol) by thermal isomerization. It takes the skin eight hours to convert 80% of the provitamin. As soon as the vitamin D3 enters the bloodstream, it is transported to the liver with the help of the vitamin D binding protein (DBP), where it is hydroxylated to 25-OH-vitamin D3 (calcidiol). Calcidiol is a storage form of vitamin D3. The conversion into the active steroid hormone 1.25-(OH)2-D3 calcitriol then continues in the kidneys⁽¹⁹⁾ (Fig.1).

Together with the parathyroid hormone (PTH), vitamin D is one of the most important hormonal elements in controlling the calcium and phosphate balance⁽²⁰⁾. The parathyroid hormone is secreted by the parathyroid gland and released when the calcium level drops. It leads indirectly to the activation of osteoclasts (“bone-eating cells”) and the mobilization of calcium and phosphate from the bone tissue. The result is increased calcium in the blood and decreased mineral content in the bones (osteopenia, osteoporosis). The synthesis and release of PTH is inhibited by calcitriol. Calcitriol thus reduces the excretion of calcium from the kidneys and increases the calcium available by means of intestinal absorption. This is associated with increased osteoblast activity, i.e. the ability to form healthy new bone⁽²¹⁾. Calcitriol is essential for undisturbed bone healing, as it inhibits osteoclasts while activating osteoblasts⁽²²⁻²⁴⁾. One of vitamin D3’s key functions is to promote the absorption of minerals in the intestine and their reabsorption through the renal end tubules. To ensure this takes place on an ongoing basis, the level of the D3 hormone calcitriol in our cells is regulated via a cybernetic feedback loop, independent of actual D3 formation with the help of the sun or D3 intake from food.

If blood calcium levels increase, calcitriol is decreased, thereby reducing calcium reabsorption. The parathyroid hormone is also lowered in order to mobilize less calcium from the bones. This is a very useful feedback loop that counteracts hypercalcemia, i.e. excessive calcium levels in the blood, which carries a risk of arteriosclerosis. If this feedback loop functions properly, the exact amount of calcitriol will always be produced to balance out the calcium level in the blood (Fig. 2). If there is a lack of vitamin D3 due to insufficient formation with the help of sunlight (which was never intended by nature, since mankind originated in Africa⁽²⁵⁾), and the intake through food is insufficient, then additional stress is added to a preexisting stress load. As a result, the body falls into the acidic pH range. However, since the blood pH value must always be regulated at just under 7.4 in order to maintain vital functions, calcium is increasingly absorbed or mobilized from the bones via the parathyroid hormone to buffer and neutralize the blood. This overrides the feedback loop described above. A normalization of the blood pH is achieved, but the increased calcium level leads to a further fatal drop in calcitriol—a vicious circle. In addition to its importance for calcium metabolism and, consequently, for bone formation, vitamin D3 has immunological and metabolic effects on our body. Furthermore, vitamin D3 controls more than 2,000 different genes and the immune system⁽¹⁹⁾ by decreasing our acquired immune response (especially overactive in the case of autoimmune diseases) and increasing our innate non-specific immune response. Vitamin D receptors are found in some cell

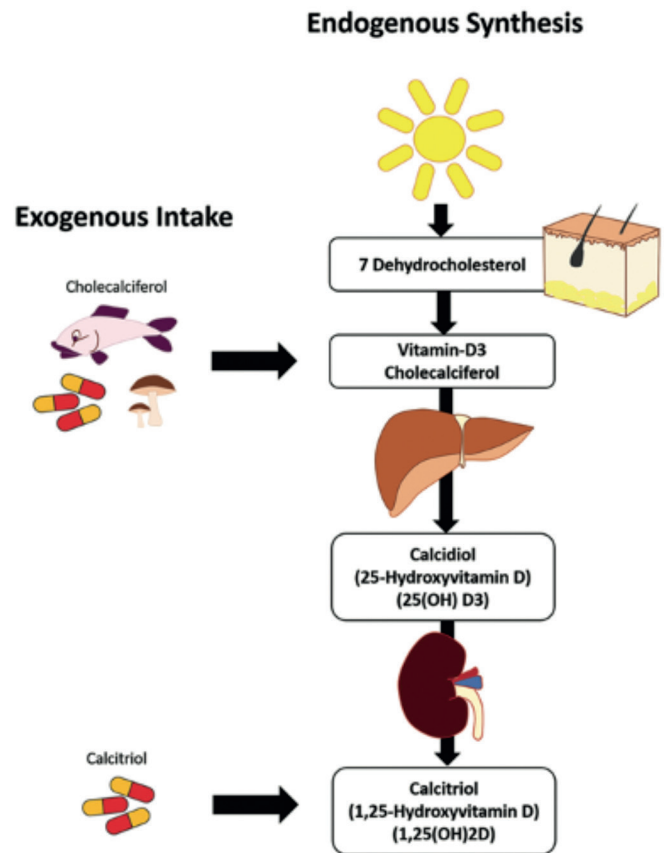


Figure 1: Schematic illustration of the endogenous synthesis and activation of vitamin D⁽¹⁸⁾

types in our immune system, e.g. in lymphocytes, especially T helper cells⁽²⁷⁾. Activated vitamin D3 stimulates the formation of antimicrobial peptides (AMPs) on the skin and mucous membrane, which has an anti-inflammatory effect⁽²⁸⁾. These often kill microorganisms, i.e. bacteria and viruses, faster and more effectively than our acquired immune system does by activating specialized defense cells. The resistance to influenza that results from a sufficient vitamin D3 supply is owed to the inhibition of the transcription factor NF- κ B^(29,30). NF- κ B is a protein that is activated by cell stress and causes both an inflammatory cascade and the formation of free radicals. Vitamin D3 thus plays a regulating role in cell stress reactions, subject to the availability of a sufficient supply of 25(OH)D 3, the storage form of vitamin D3 (calcidiol).

Vitamin D helps us achieve a parasympathetic tone—the opposite of the stress response. It promotes restful relaxation and healthy sleep⁽³¹⁻³³⁾.

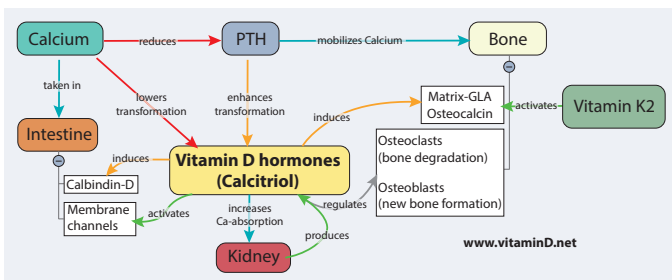


Figure 2: Feedback loop for adequate blood calcium levels

Pathophysiology

The prevalence of chronic diseases such as diabetes mellitus and multiple sclerosis has shown to increase with the distance from the equator and thus less sunlight and less time spent outdoors. Due to stressful living conditions, which lead to systemic acidosis and thus to the resorption of calcium from the bones in order to buffer the blood pH to 7.4, the body simulates a sufficiently high D3 level, which further exacerbates the lack of D3. Since vitamin D3 supports the immune system, a deficiency can have many different repercussions⁽³⁴⁾. Autoimmune diseases such as multiple sclerosis or rheumatoid arthritis occur more frequently when we have low D3 levels⁽²⁶⁾. In experiments, the elimination of these receptors led to outbreaks of inflammatory bowel disease. Vitamin D deficiency can lead to dysbiosis of the intestinal microbiome and trigger colitis⁽³⁵⁾. The microbiome, our largest immune organ, is dependent on vitamin D⁽³⁶⁾. Studies show an increased predisposition to respiratory infections in children and adolescents^(37,38). In addition to susceptibility to infections, other typical deficiency symptoms are rickets, osteoporosis, gingivitis and many others⁽³⁹⁻⁴³⁾. Besides concentration and cardiovascular disorders, it can lead to reduced muscle strength, growth disorders, increased susceptibility to fractures, sleep and concentration disorders and depression^(34,39,42,44-50). Neurological diseases, such as schizophrenia or autism, are also vitamin D dependent⁽³⁶⁾. A study from 2015 indicated that avoiding sunlight as a risk factor for premature death was on a par with smoking⁽⁵¹⁾.

Preventive and therapeutic significance

Vitamin D has been shown to have a preventive effect on cardiovascular diseases, including myocardial infarction, cancer, MS, and chronic fatigue triggered by permanent NF-κB activation^(39,44,52-57). The importance of vitamin D in the prevention and therapy of infectious and chronic diseases could be owed to its anti-inflammatory and immu-

nomodulatory effects. Some studies have shown its antiviral effect in connection with influenza infections^(58,59). The benefits of vitamin D in COVID-19 patients are also increasingly being demonstrated^(60,61). As part of its important functions in both the innate and the acquired immune defense, it stimulates, among other things, the production of the aforementioned AMPs such as defensin and cathelicidin, which act as endogenous antibiotics and kill off Influenza and coronaviruses^(62,63), to give two examples. It also acts as a modulator of B and T cells and reduces inflammatory processes. In one study, vitamin D supplementation prevented high levels of eosinophils and an inflammatory response in the lungs in mice after the initial phase of sensitization to an allergen⁽⁶⁴⁾. Moreover, vitamin D protects the lungs by positively affecting the blood pressure-regulating renin-angiotensin-aldosterone system (RAAS) and alleviating bacteria-induced lung damage⁽⁶⁵⁾. Consequently, high-dose D3 therapy invariably not only increases performance but also reduces susceptibility to stress and improves mood. There is hardly a more effective anti-depressant than vitamin D3^(66,67).

In oncology, the positive effects of vitamin D are increasingly being highlighted. Many studies have shown that low vitamin D levels in patients with colon cancer, breast cancer, chronic lymphatic leukemia and acute myeloid leukemia can be associated with a poorer clinical outcome and a worse prognosis⁽⁶⁸⁻⁷⁰⁾. One study also indicated that patients with B-cell lymphoma benefit from additional vitamin D administration in antibody therapy with rituximab⁽⁷¹⁾. In patients with metastatic colon cancer, one study shows that high vitamin D levels prolong progression-free survival⁽⁷²⁾. Another study examined 351 patients with Hodgkin's lymphoma over an observation period of 13 years. It was shown that the patients with vitamin D deficiency had decreased progression-free survival and overall survival⁽⁷³⁾. Vitamin D is even believed to have an anticarcinogenic effect and is recommended as a novel and economical cancer drug⁽⁷⁴⁾. A review (see Fig. 3 p. 58) showed that patients with serum levels of 40- 60 ng/ml of the storage form 25-OH-D3 are protected from most chronic diseases⁽⁷⁵⁾!

Importance of vitamin D in sports medicine

The aspects presented above are also important for sports medicine. The skeleton itself is just as important for a stable musculoskeletal system that can withstand extreme loads as it is for rapid and full fracture healing after injuries. The anti-inflammatory aspect combined with a reduced degree of inflammation of the musculature correlates with rapid healing in the context of micro-injuries during high training and competition-related exertion.⁽⁷⁶⁾ Immunomodulation should also not be

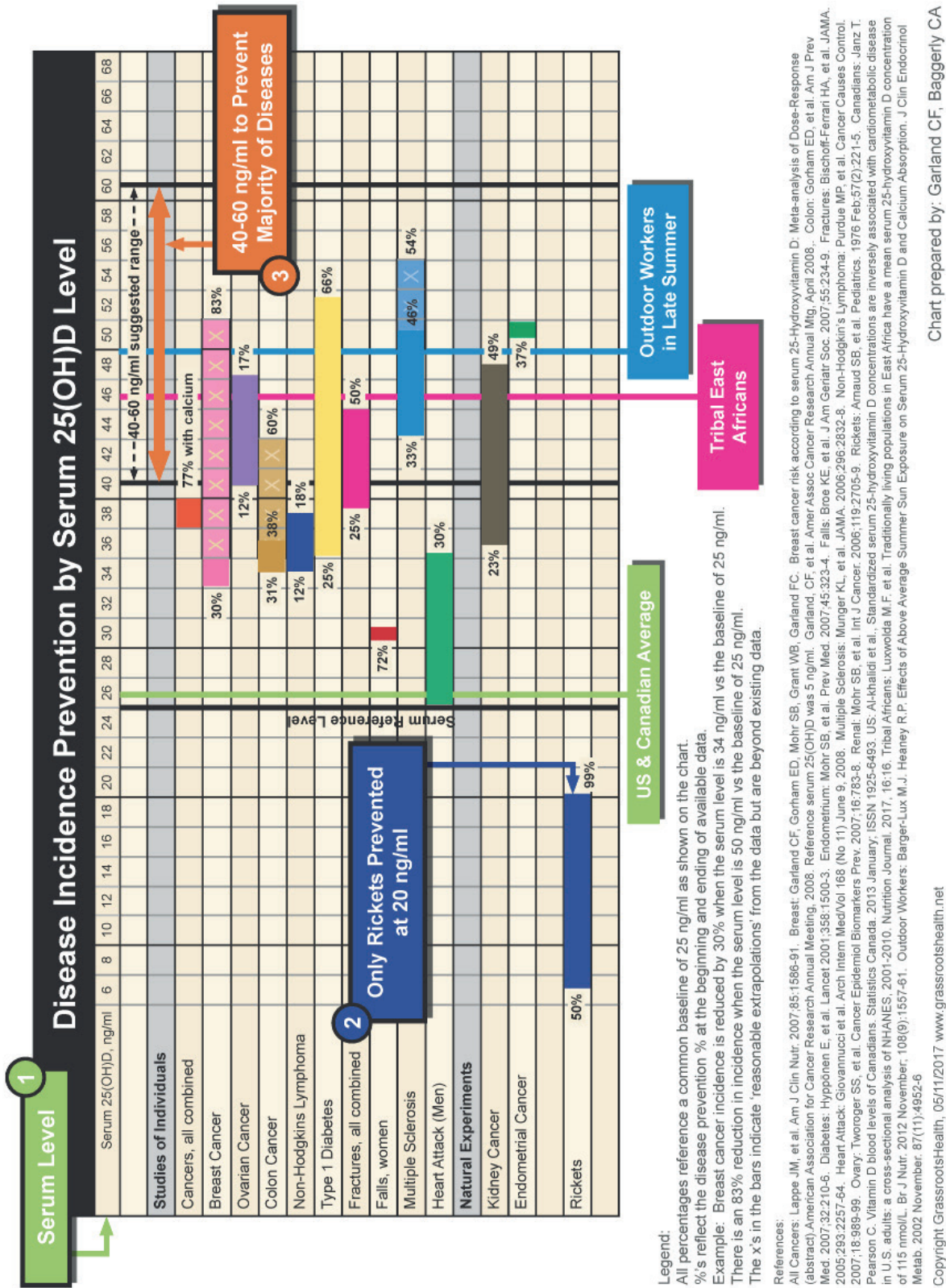


Figure 3: Disease incidence in relation to 25-OH-D3-levels⁽¹⁶⁶⁾

underestimated, as a competitive athlete's immune system tends to be under a great deal of strain, especially with regard to viral diseases. Increased maximum oxygen uptake⁽⁷⁷⁾ and improved resilience of the cardiopulmonary system⁽⁷⁸⁾ are especially important in sports medicine. As regards muscular structure and performance, type II muscle fibers are of particular importance, e.g. for soccer players⁽⁷⁹⁾. Overall, there is sufficient evidence to suggest that vitamin D promotes performance and regeneration and reduces susceptibility to injury. Recent studies have however shown inconsistent results, and much research is still needed. There is a lack of clarity, especially with regard to the individual optimum vitamin D status.⁽⁸⁰⁾

Importance for dentistry

The importance of vitamin D in dentistry has also been described on many occasions. One study showed that a low-carbohydrate diet with adequate coverage of the need for omega-3 fatty acids, fiber, vitamins C and D3 and antioxidants can generally prevent inflammation of the gum and periodontium⁽⁸¹⁾. Consequently, advanced periodontitis no longer requires surgery, but can be prevented and treated through a supply of the above-mentioned vitamins and minerals. A study showed that patients with high vitamin D levels had significantly less gum bleeding, shallower pocket depths and less tooth loss⁽⁸²⁾. In addition to links with gingivitis/periodontitis and tooth loss, the correlation between vitamin D deficiency and caries, molar incisor hypomineralization has also been demonstrated⁽⁸³⁻⁸⁹⁾. Vitamin D inhibits the growth and expression of virulence factors of the periodontal marker germ *Porphyromonas gingivalis*⁽⁹⁰⁾; vitamin D also increases the antibacterial activity of oral epithelial cells against the periodontal germ *Aggregatibacter actinomycetemcomitans*⁽⁹¹⁾. Vitamin D levels have a positive effect on local bone remodeling⁽⁹²⁾. A study by Choukroun et al. confirms the importance of vitamin D3 for bone formation, which is essential for the healing of implants⁽⁹³⁾. 1,25-(OH)₂-vitamin 2-D3 (calcitriol) is the most important hormone involved in bone formation, while also reducing the propensity to inflammation. Vitamin D3 deficiency inhibits the healing of implants and raises the risk of infection⁽⁹³⁻⁹⁵⁾. Dental X-rays can also provide information about vitamin D3 deficiency: In patients with severe vitamin D3 deficiency, the pulp horns are asymmetrical and narrowed and look like a hard-back chair. Healthy pulp resembles a round arch with wider pulp horns⁽⁹⁶⁾.

Laboratory test status and recommended intake

The evidence presented demonstrates the importance of adequate vitamin D levels. Serum 25-(OH)-D3 concentration is recognized as a reliable marker for its determination⁽⁹⁷⁾. Depending on the testing laboratory, vitamin D

concentration is expressed in nanograms per milliliter (ng/ml) or nanomoles per liter (nmol/l), where 1 nmol/l is equivalent to 0.4 ng/ml. Given our current highly stressful lifestyle, especially when living far from the equator, it is not possible to achieve the vitamin D levels necessary to remain healthy by spending sufficient time in the sun. Even if there was enough natural sunlight, we need to take vitamin D3 to protect ourselves from acute and chronic diseases and to guarantee optimal long-term prognosis for ceramic implants. The recommended daily dose was not increased in Germany from 400 units to 800 units daily until 2012⁽⁹⁸⁾. Furthermore, in 2018 it became public knowledge that the current recommendations for daily doses of vitamin D3 had been set too low⁽⁹⁹⁻¹⁰¹⁾—namely by a factor of 10 due to a calculation error^{(102)!} Pregnant women are recommended to have vitamin D levels above 40 ng/ml (25-OH-D3) to protect both mother and fetus⁽¹⁰³⁾.

A current publication⁽¹⁸⁾ recommends to aim for a serum vitamin D level between 40 and 80 ng/ml. Dosing should be carried out individually and checked by means of laboratory tests every three months. In case of vitamin D deficiency with respect to the above threshold (less than 40 ng/ml), a daily dose of 10'000 IU should be administered over three months to compensate for the deficiency. A daily dose of 5000 IU is considered an appropriate maintenance dose for vitamin D 80 ng/ml the range of 40 to 80 ng/ml. If this range is exceeded (> 80 ng/ml), the dose should be reduced to 1000 IU (see Fig. 4). In case of impaired organ function or metabolic disease, the dose should be individualized accordingly. A protective dose of more than 10,000 I.U. per day will optimally prepare patients for surgical intervention.

Safety

A review of safety data in randomized controlled clinical trials with daily doses of 5000 to 10,000 IU/d revealed no vitamin D intoxication. It is only studies from the 1930s and 1940s involving extremely high daily doses of vitamin D between 60,000 and 600,000 IU/d that reported hypercalcemia as a consequence of the unphysiologically high doses⁽¹⁸⁾.

Cofactors

It is important to combine vitamin D3 with vitamin K2/mk7 when taking it over long periods in order to prevent potential hypercalcemia in the blood⁽¹⁰⁴⁾. The ratio of vitamin D3 to K2/mk7 should be 10,000 I.U. to 100µg K2/mk7. The conversion into the active vitamin D hormone and further transport within the body rely particularly heavily upon magnesium⁽¹⁰⁵⁻¹⁰⁷⁾. Magnesium deficiency would block the entire supply of PTH, calcium and vitamin D⁽¹⁰⁸⁾. It is very important to give enough magnesium when

administering high doses of vitamin D3 to prevent magnesium deficiency.⁽¹⁰⁹⁾ This has been taken into account in the composition of BASELINE and BOOST. Protein synthesis and the activation of some genes also require vitamin A in a balanced concentration to vitamin D⁽¹¹⁰⁾. If the ratio is unbalanced, the vitamins act as antagonists, and vitamin D's action is impaired⁽¹¹¹⁾. Vitamins A and D have very closely related effects. "During gene transcription, the receptors for vitamin D hormone (VDR) and vitamin A hormone (RXR) merge, which is why the intrinsic effects of the sun hormone 1,25-(OH)2-D are often shared with the vitamin A hormone (retinoic acid)"⁽¹¹²⁾. After entering the cell nucleus, this complex can bind to the "vitamin D responsive element "(VDRE) in the DNA and control the transcription of many genes. This enables the synthesis of the aforementioned antimicrobial, in particular antiviral AMPs, which in turn can reduce the infectivity of common cold viruses⁽¹¹²⁾. A zinc deficiency also limits the function of vitamin D. Zinc is needed to form vitamin D receptors, which are found on almost all cells⁽¹¹³⁾.

Side note: The usefulness of sunscreens

When it comes to sunscreen, it is important to know that the production of vitamin D is exclusively reliant upon long-wave UVB radiation, which accounts for the lower proportion of UV radiation. It is not dangerous for our skin. The shorter UVA rays, on the other hand, penetrate deeper into the skin and are responsible for cell damage and skin aging. Therefore, it is better to go out briefly in the midday sun, which is rich in UV, than to follow the widespread assumption that the less intense morning and evening sun is preferable⁽⁷⁾. Practically all sunscreens only have a UV filter built in. On the one hand, this fatally prevents the formation of vitamin D3 in the skin. On the other hand, people may spend more time in the sun, and thus damage their skin through greater UV exposure. Scientific findings from the Karolinska Institute in Stockholm, gathered over 20 years and involving more than 30,000 subjects, suggest that sunscreens have been proven to be responsible for the development of skin cancer⁽¹¹⁴⁾, a result seconded by another study⁽¹¹⁵⁾.

Creeping poisoning with toxins contained in sunscreens certainly contributes to this situation, as these toxins are particularly easily absorbed by the skin—which after all is one of the most effective absorption organs and has a surface area of 1.5 to 2 m². Titanium dioxide nanoparticles (E171), contained in almost all sunscreens, damage the DNA and contribute to the development of Alzheimer's, epilepsy and autism. Zinc oxide nanoparticles⁽¹¹⁶⁾, also contained in these products, are suspected of killing intestinal and brain stem cells⁽¹¹⁷⁾. Moreover, almost all sunscreens contain the two "super poisons" oxybenzone and octinoxate^(118,119). For this reason, Hawaii was the first

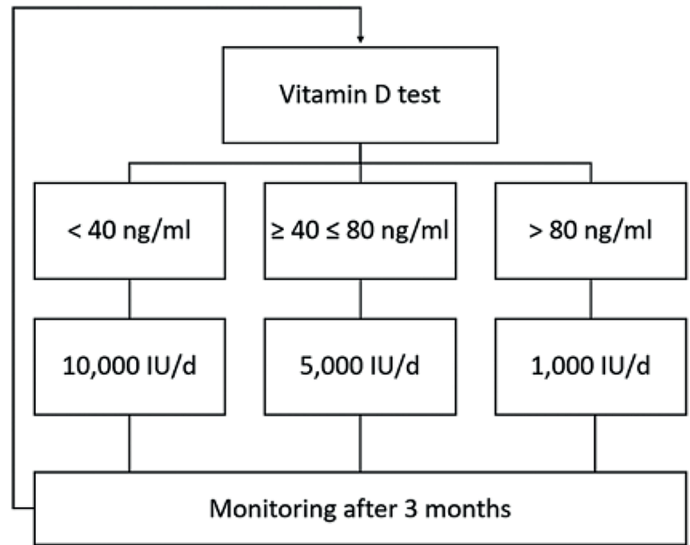


Figure 4: Vitamin D supplementation protocol in healthy adults for the maintenance of adequate vitamin D status⁽¹⁸⁾

American state to ban the sale and use of sunscreens, as these toxins destroy the coral reefs⁽¹²⁰⁻¹²²⁾. Interestingly, press articles mention the fatal effect of the two super toxins on corals but completely fail to mention their effect on humans.

Importance for the THE SWISS BIOHEALTH CONCEPT

Blood levels of at least 70 ng/ml of 25-hydroxy-D3 (calcidiol) are commonly achieved when taking the dosage prescribed as part of the preoperative micronutrient therapy (see p. 46) in the two to four weeks prior to a surgical procedure. We believe that this dose optimally prepares patients for surgery. The phenomenon of vitamin D3 receptor blockage has been the subject of growing debate in recent years and is associated with an activation of retroviruses embedded in the DNA by environmental and dental toxins. This explains why, surprisingly, significantly lower amounts of vitamin D3 are sufficient to maintain a value of 70 ng/ml after a successful restoration in accordance with the ALL-IN-ONE concept has been carried out. In the event of a receptor blockage, the system must be flooded with high doses of vitamin D3 prior to restoration in order to achieve the required value of > 70 ng/ml. This can be achieved in virtually all cases through supplementation with our micronutrient formulation. In rare cases it may be necessary to increase D3 to daily doses of up to 100,000 I.U.

VITAMIN K2

As far back as 1945, Dr. Weston Price discovered a “vitamin-like activator” which, according to his research, plays a central role in the storage of minerals, child growth and development, tooth positioning and physique, reproduction, aging, heart disease and brain function. He named this factor “activator X”. It was not until 2008 that Christopher Masterjohn combined the studies of Weston Price with those of the United States Department of Agriculture and Tufts University⁽¹²³⁾. Masterjohn was able to demonstrate that the activator X is identical to vitamin K2.

Occurrence

There are two naturally occurring forms of vitamin K: Vitamin K1 and vitamin K2. Vitamin K1 is also known as phylloquinone, and vitamin K2 as menaquinone. Vitamin K1 is a component of plant-based food. It is found especially in the leafy greens of herbs and green vegetables, as it plays an important role in photosynthesis. Vitamin K2 can be of animal or bacterial origin. It is found in fermented plant-based foods. Nattō, a popular Japanese food made from fermented soybeans, is particularly rich in K2. Vitamin K2 can be produced to a small extent by a healthy intestinal flora. The best-known types of menaquinones are MK-4 and MK-7. Compared to vitamin K1, vitamin K2 is the more active form and can be better absorbed and distributed by the body. Western diets however contain about 90% vitamin K1⁽¹²⁴⁾.

Physiological significance

Vitamin K is required for the synthesis and activity of GLA (gamma-carboxylglutamic acid) proteins, which are activated by a vitamin K-dependent carboxylation reaction⁽¹²⁵⁾ and have a variety of functions. Vitamin K2 appears to have the strongest gamma carboxylation activity⁽⁸⁾. Osteocalcin is probably the most important GLA protein. It plays an important role in calcium metabolism in tissues such as vessels, connective tissue and bone. It is effective only in its carboxylated form (activated osteocalcin) and should be present in sufficient quantity, requiring an appropriate amount of vitamin K. Osteocalcin synthesis is initiated by calcitriol (the active form of vitamin D3). The matrix GLA protein (MGP), which has a high affinity for calcium ions, also supports bone mineralization and inhibits calcium deposition in blood vessels. In general, vitamin K2/mk7 is responsible for transporting the minerals absorbed by D3 in the intestine and reabsorbed in the renal end tubules from the blood to the bones. Other GLA proteins activate clotting factors in the liver, namely factors II, VII, IX, X, and the proteins C, S and Z. In addition, they can activate the MGP. Vitamin K also plays a role in cartilage mineralization, lipid metabolism and the mitochondrial respiratory chain⁽⁸⁾.

Pathophysiology

A deficiency in vitamin K causes a reduction of bone density and disrupts bone formation. It can also manifest itself in the form of cardiovascular diseases⁽¹²⁶⁾. Due to its major role in blood clotting, a vitamin K deficiency can result in bleeding and prolonged clotting times, e.g. in the context of surgery.

Preventive and therapeutic significance

Vitamin K optimizes bone density and can be used to prevent and treat osteoporosis^(121,127,128). It inhibits vascular calcification by means of the above mechanisms. It prevents the widespread disease of arteriosclerosis and protects against cardiovascular disorders⁽¹²⁹⁻¹³¹⁾, reducing the risk of heart disease, including myocardial infarction. There is also evidence that vitamin K improves brain function by influencing sphingolipid synthesis⁽¹³²⁾, has an anti-tumor effect⁽¹³³⁾, prevents type II diabetes⁽¹³⁴⁾ and can increase fertility in men⁽¹³⁵⁾. Dr. Weston Price's findings regarding the paramount importance of the “activator X” have thus been largely confirmed by modern research.

Importance for dentistry

Due to its positive effect on bone metabolism, it plays an important role in surgical procedures on the jaw such as tooth extractions, or in implantology. Vitamin K can also protect against caries⁽¹³⁶⁾.

Recommended intake

The German Nutrition Society (DGE) suggests 60–65 µg for women and 70–80 µg for men⁽¹³⁷⁾ as an adequate intake, not distinguishing between vitamin K1 and K2. This amount is based on the need for the control of blood coagulation. An optimum bone metabolism probably requires much higher doses in the order of 100 to over 1000 µg per day⁽⁸⁾.

Safety and interactions

Vitamin K2 cannot be overdosed even when taken in high doses. Patients who are dependent on anticoagulant medications should however limit the intake⁽¹³⁸⁾ and consult their physician. Taken in a dose of 25 µg per day, it does not interfere with the action of anticoagulants such as Marcumar®.

Cofactors

100 µg of vitamin K2/mk7 are required for every 10,000 I.U. of vitamin D3. For more information on the interaction with vitamin D, see Vitamin D cofactors (p. 60).

Importance for the THE SWISS BIOHEALTH CONCEPT

We attach great importance to an adequate vitamin K2 supply because of its outstanding importance for bone

metabolism. This is ensured by the intake of specific micronutrients prior to surgery (see p. 46) and of the preparation D3 + MK-7 COMPLETE.

VITAMIN C

Vitamin C is a water-soluble antioxidant that plays a significant role in a variety of vital functions.

Occurrence

Humans have been described as “defective mutants”. Unlike most other mammals, they lack the enzyme which would enable them to synthesize vitamin C from glucose in the small intestine and must instead absorb it through their diet. Unfortunately, contrary to popular belief, orange juice contains only very small amounts of vitamin C (52 mg per 100 ml). By way of comparison, the acerola cherry contains up to 1700 mg per 100 g⁽¹³⁹⁾! The cheapest option is to buy ascorbic acid and dissolve it with a natural lime (e.g. dolomite) and water. This results in buffered magnesium and calcium ascorbate. Natural vitamin C with bioflavonoids works even better.

Physiological significance

Vitamin C gives off electrons very easily in a chemical reaction in the body. It is a potent reducing agent and the scavenger of radicals (antioxidant) par excellence, reducing oxidative stress in cells and tissues. Vitamin C supports the synthesis of carnitin—a compound which is important for the provision of energy through fatty acid utilization. Vitamin C also activates the cytochrome P450 system, thus boosting detoxification. Like vitamin D3, it has an osteoblast-activating and osteoclast-inhibiting effect, supporting bone formation and inhibiting bone resorption⁽¹⁴⁰⁻¹⁴⁴⁾. Together with the amino acids lysine and proline it promotes the formation of collagen and connective tissue^(145,146), and is therefore very important for the elasticity of bones and tissues as well as for wound healing. In addition to its wound healing function, vitamin C is as important as vitamin D3 when it comes to protecting the body against infections^(8,147-149). This immunological protection results from the promotion of the synthesis of interferones, immunoglobulins and complement factors, phagocytosis and chemotaxis, as well the increase of natural killer cell activity. It also influences the migration of macrophages and can enhance the proliferation of T and NK cells and boost the formation of antibodies. Moreover, it has an anti-inflammatory effect by protecting against excessive pro-inflammatory signals such as cytokines or histamine, thus preventing tissue destruction. Vitamin C has another positive effect on the body: It boosts stress tolerance in connection with the neurotransmission mediated by glutamate and dopamine (neuroprotective and neuromodulative effect). In addition, it is involved in the synthesis of neuropeptides and neurotransmitters, e.g. of

norepinephrine from dopamine as well as serotonin. Vitamin C also prevents the formation of cancer-causing nitrosamines and inhibits DNA, protein and lipid peroxidase. It has a selective cytotoxic effect on tumors by forming H₂O₂.

Pathophysiology

Scurvy is the clinical picture of a severe vitamin C deficiency. Typical symptoms are periodontitis, wound healing disorders and susceptibility to infections^(144,147,148,150-152). Since vitamin C is very important for the tissue elasticity, the lack of it can result in bleeding due to capillary fragility. Carnitine deficiency, which occurs with vitamin C deficiency, causes exhaustion, fatigue and muscle weakness.

Preventive and therapeutic significance

Vitamin C supplementation reduces the likelihood of a common cold⁽¹⁵³⁾. Vitamin C prevents and relieves the symptoms of virus-related respiratory infections⁽¹⁵⁴⁾. Vitamin C can effectively reduce the duration of a cold even in extreme cases, for example in those involving athletes⁽¹⁵⁵⁾. The helpful effect of vitamin C on pneumonia was reported as early as in the 1930s^(156,157). In case of sepsis and a significant increase in cytokine concentration, neutrophils accumulate in the lungs, destroying alveolar capillaries and causing an accumulation of alveolar fluid. Vitamin C can effectively prevent this process by inhibiting the activation and accumulation of neutrophils. These findings are of particular importance in the context of SARS-CoV-2 infections. Dr. Richard Cheng, who treated patients with severe courses of COVID-19 with vitamin C in Shanghai in the winter of 2019/ 2020, stresses that when it comes to COVID-19 infections: “It is decisive to give sufficient amounts of high-dose intravenous vitamin C as early as possible. Vitamin C is not only a prototypical antioxidant, but also involved in killing viruses and preventing virus replication. High-dose intravenous vitamin C is not only effective on an antiviral level. During coronavirus pandemics (SARS, MERS, and now NCP), most people die of an acute respiratory distress syndrome (ARDS). ARDS is a common end pathway leading to death.” NCP stands for Novel Coronavirus Pneumonia“.

Importance for dentistry

Vitamin C is of great importance both in terms of prevention and treatment, as it can help prevent inflammatory processes such as periodontitis and ensure adequate healing of wounds and bones after dental procedures.

Recommended intake

The recommended daily intake for adults in Germany is officially 95-110 mg per day⁽¹⁵⁸⁾—a level that can just about prevent scurvy! Two-time Nobel Prize winner Prof. Linus Pauling recommended intravenous vitamin C infusions of

10 to 20 g. He justified this by arguing that almost all mammals, with the exception of humans, apes and guinea pigs, can metabolize ascorbate from glucose, with an average daily production of 10 g based on a human body weight of 70 kg⁽¹⁵⁹⁾. Goats can produce 200 mg of vitamin C per kilogram of body weight daily⁽¹⁶⁰⁾. In stressful situations, animals even produce significantly higher amounts. In situations of acute stress, rats can produce up to 10 g of vitamin C in a fraction of a second. In a study involving cancer patients who had run out of treatment options, Pauling and his colleague Cameron demonstrated that with the administration of 10 g of vitamin C per day, the average survival time for the ascorbate group was more than 4.2 times longer than for the control group⁽¹⁶¹⁾. In view of these correlations, a reasonable daily dose is 1 to 3 g. Monkeys, who share more than 98% of DNA with us, eat a daily ration of 4.5 g of vitamin C, which would be equivalent to a dose of almost 10 g for humans. Oral absorption being limited, doses in the higher gram range must be given intravenously. Only via the Esther-C form can a bigger daily dose of 2 to 10 g be taken orally (SWISS BIOHEALTH VITAL Ester-C supz inside), enabling the body to get habituated to higher amounts. Hydrocortisone facilitates and increases the absorption of vitamin C by the body's cells. It is suspected that this is a major reason for its strong anti-inflammatory properties. Combining hydrocortisone with vitamin C should be considered with a view to optimizing vitamin C therapy⁽¹⁶²⁾.

Safety, side effects and contraindications

Vitamin C is very well tolerated. Due to microbial degradation in the intestine, oral intake in the gram range may however cause flatulence and diarrhea. Caution should be exercised by people suffering from iron storage disease and kidney stones. High-dose intake is contraindicated in case of glucose-6-phosphate dehydrogenase deficiency and renal insufficiency⁽⁸⁾.

Cofactors

In patients with sulfur deficiency (deficiency of cysteine, glutathione), vitamin C can have a pro-oxidant effect. In such cases, it should therefore be combined with acetylcysteine.

Importance for the

THE SWISS BIOHEALTH CONCEPT

For a single administration before, during and after a jaw operation, 15 g of vitamin C per day is recommended to reach a total dose of 45 g 45 g vitamin C perioperatively. Within THE SWISS BIOHEALTH CONCEPT, this infusion is administered over a total of 5 days, starting the day before surgery.

MAGNESIUM

Magnesium is one of the most important minerals for the human body.

Occurrence

Foods with the highest magnesium content include seaweed with 760 mg, pumpkin seeds with 532 mg, wheat bran with 490 mg and nuts, e.g. almonds with 270 mg or cashew nuts with 267 mg per 100 g.

Physiological significance

Magnesium is a component or coenzyme of more than 300 enzymes. It plays a major role in mitochondrial function and is involved in all ATP-dependent processes as well as in the conversion of glucose, and is therefore indispensable for the provision of energy in every cell. It interacts with phospholipids, thus stabilizing cell walls. Magnesium is a cofactor of the sodium-potassium pump, which moves two potassium ions into the interior of the cell, exchanging them for three sodium ions.

Ultimately, this leads to a negative charge in the interior of the cell. The resulting resting membrane potential forms the basis for stimulus conduction, especially in nerve and muscle cells. Magnesium is a natural calcium antagonist and can also control calcium influx across cell membranes. In bone, magnesium is involved in building the bone matrix and in mineralization. It is also essential for the activation of vitamin D in the kidney. Magnesium has a cardioprotective effect and is involved in the regulation of the immune system⁽⁸⁾.

Pathophysiology

Magnesium deficiency results in cell aging, manifested in a premature shortening of telomere length and a consequent increase in biological age. A deficiency typically shows as nervousness, increased excitability and spasms of muscles, vessels, the intestine and other internal organs, resulting in constipation. It also affects the cardiovascular system, resulting in arrhythmias, high blood pressure and even heart failure. Blood lipids increase, glucose tolerance decreases. The body's ability to compensate for stress is reduced.

Preventive and therapeutic significance

Magnesium relieves tension and pain and plays an essential role in osteoporosis and ADHD. It can prevent exercise-related muscle cramps and has a relaxing effect on the muscles, and is effective against high blood pressure and cardiac arrhythmias. Like vanadium, manganese and chromium, it reduces cravings for sweets. Moreover, it reduces the risk of developing diabetes and kidney stones. It is a factor to bear in mind when it comes to sleep disorders.

Importance for dentistry

Magnesium, as a component of the tooth, is very important for dental health, along with calcium and phosphorus. Magnesium deficiency can result in tooth loosening, premature tooth loss, bone loss and an increased susceptibility to bleeding.⁽¹⁶³⁾

Laboratory test status and recommended intake

Approximately 99% of total body magnesium is stored in the cells, 95% of which is found in the mitochondria. This is why its levels should be determined not in serum, but rather in whole blood. An intake of 300–400 mg per day is recommended—preferably as an organic compound, e.g. Magnesium citrate. Athletes, pregnant women and nursing mothers have an increased need for magnesium.

Safety, side effects and contraindications

The oral intake of magnesium in higher doses may cause soft stools or diarrhea. Magnesium is contraindicated in severe renal insufficiency.

Cofactors

The interaction of magnesium and vitamin D is described in the chapter on vitamin D cofactors (p. 60). Vitamin C intake should ideally be combined with magnesium. It can be administered intravenously together with vitamin C⁽⁶⁾.

Importance for the

THE SWISS BIOHEALTH CONCEPT

Because of its multiple functions—especially with regard to stress reduction and bone formation—which are key aspects of THE SWISS BIOHEALTH CONCEPT, magnesium is part both of our pre- and postoperative micronutrient supplementation and of the infusions administered during My BIOHEALTH Week.

OMEGA-3 FATTY ACIDS

Fatty acids are found in both fats and oils. They can be divided into saturated, monounsaturated and polyunsaturated fatty acids. Animal-based foods (e.g. meat, sausage, butter), in particular, comprise saturated fatty acids. Monounsaturated fatty acids are found especially in plant oils such as olive oil and rapeseed oil. Omega-3 and omega-6 fatty acids are polyunsaturated fatty acids. As the body is unable to produce these fatty acids itself, they are referred to as essential fatty acids. As building blocks of cell membranes, starting substances for the synthesis of eicosanoids (hormone-like tissue mediators) and important factors in the development of the brain and nervous system as well as is in blood clotting and the regulation of inflammatory processes, they have many important tasks to perform within the body (Gröber OM book, ISBN 978-3-8047-1927-98⁽¹⁶⁴⁾).

Occurrence

Important omega-6 fatty acids include linoleic acid, α -linolenic acid and arachidonic acid. The most important omega-3 fatty acids are α -linolenic acid (ALA), eicosapentaenoic acid (EPA) and docosahexaenoic acid (DHA). α -linolenic acid is the starting fatty acid in the metabolism of omega-3 fatty acids. A balance between omega-6 and omega-3 fatty acids is essential for the human body. While omega-3 fatty acids have an anti-inflammatory effect, omega-6 fatty acids promote inflammation. Today's average diet exhibits a ratio of 15:1 in terms of omega-6 to omega-3 and is thus pro-inflammatory in nature. In the case of good plant-based foods, this ratio stands at approximately 1.5:1, meaning that they are not only preferable for ethical reasons. One of the causes of this imbalance is the change in dietary habits and the use of "cheap" omega-6-rich plant oils in the food industry. Soy flour is used especially frequently in animal husbandry, with the concentrated feed provided to livestock comprising more than 50% soy oil. This, together with the use of industrially produced foods high in omega-6 such as sunflower oil, corn kernel oil and soy oil, is leading to a high intake of omega-6 in our diets. Omega-3 is found in high amounts in fatty fish, including herring, mackerel, salmon and sardines, as well as in game meat and algae. In plant oils, linseed oil, hemp oil and gold of pleasure oil have particularly high levels of α -linolenic acid. EPA and DHA are only found in fish and algae and corresponding oils. Our body can only produce a small amount of these particularly important fatty acids itself from α -linolenic acid, which is why it is recommended that we consume it via fish and algae products in order to cover our requirements⁽¹⁶⁵⁾.

Pathophysiology

A deficiency in omega-3 fatty acids can have many effects on the body. In the cardiovascular system, it may increase cardiovascular morbidity and mortality. It increases our predisposition to inflammation, leads to immune disorders and promotes skin diseases. A deficiency in omega-3 fatty acids (DHA) during pregnancy and breastfeeding can negatively impact the baby's mental development, vision and growth. It can also give rise to concentration, learning and growth disorders in children and young people (Gröber OM book⁽¹⁶⁴⁾).

Preventive and therapeutic significance

Many positive effects of omega-3 fatty acids on the body are known. In the cardiovascular system, among other benefits, omega-3 fatty acids have endothelium-protective abilities, serve to lower blood pressure, have an anti-arrhythmic effect, reduce pro-inflammatory cytokines (such as TNF- α), can increase heart rate variability (HRV) and inhibit platelet aggregation. They also contribute to

maintaining normal blood triglyceride levels by lowering triglyceride-rich VLDL and boosting HDL levels and promote the formation of vasodilating nitric oxide (NO). Omega-3 is especially important for supplying our brain, which comprises 60% fat. DHA also contributes to improving vision. During pregnancy and breastfeeding, in particular, taking EPA and DHA is highly recommended. DHA, an important building block in brain and nerve cells, can make a considerable contribution to the development of an embryo's intelligence and visual ability (Gröber OM book, Gröber COVID-19 book, ISBN 978-3-8047-4229-1, Norsan⁽¹⁶⁴⁾). The anti-inflammatory and immunomodulatory properties of DHA and EPA are also of great importance in the context of SARS-CoV2 diseases.

Importance for dentistry

Due to their anti-inflammatory properties, omega-3 fatty acids play both an important preventive and therapeutic role in averting inflammatory processes such as periodontitis and in ensuring the optimal healing of wounds after dental procedures (PMID: 31404604⁽¹⁶⁶⁾, PMID: 33022782⁽¹⁶⁷⁾, PMID: 28646265⁽¹⁶⁸⁾, PMID: 34760614⁽¹⁶⁹⁾).

Laboratory status, recommended intake and safety

The omega-3 index determines the proportion of the omega-3 fatty acids EPA and DHA in the fatty acids found overall in the erythrocyte membrane. If the index is in the range of 8% to 11%, it is considered to be neuroprotective, vasculoprotective and cardioprotective. A ratio of omega-6 to omega-3 (arachidonic acid to EPA) of less than 2.5:1 should be strived for. A daily intake of 0.5 g to 1 g of EPA and DPA is recommended, and perhaps even more in the short term if there is an acute need (Gröber COVID-19 book, ISBN 978-3-8047-4229-1⁽¹⁷⁰⁾, and Gröber micronutrients book, ISBN 978-3-8047-2615-4⁽¹⁷¹⁾).

Importance for THE SWISS BIOHEALTH CONCEPT

Due to their multiple functions and, in particular, anti-inflammatory effect, omega-3 fatty acids are an important element in THE SWISS BIOHEALTH CONCEPT and part of our pre- and postoperative micronutrient supplementation (see composition of BASELINE and BOOST).

VITAMIN A

Vitamin A (retinol) is a vitamin that is often neglected and has enormous influence on the entire metabolism. Vitamin A deficiency has become a health problem on a global scale, affecting many children.

Occurrence

Vitamin A is found in animal foods such as cod liver oil, liver, butter and eggs.

Physiological significance

Vitamin A contributes to cell growth and differentiation and promotes the functioning and structure of skin, mucous membranes and bone tissue. It plays a major role in vision and hormone metabolism, and is important for the functioning of the mitochondrial respiratory chain (complex I and II). It is also key when it comes to the mucosal immunity of the respiratory tract, the digestive tract including the oral cavity, and the urogenital tract, — the first line of defense against bacteria, viruses and parasites⁽⁶⁾. Vitamin A actively recruits immune cells back into the intestinal mucosa ("after they have proved their mettle throughout the body")⁽¹¹²⁾.

Pathophysiology

Vitamin A deficiency manifests as loss of appetite, fatigue and susceptibility to infections, e.g. frequent respiratory tract infections and even bronchitis and pneumonia. It can result in a variety of symptoms involving the eye, ranging from dry eyes and sensitivity to glare to corneal melting (keratomalacia) and blindness. Moreover, it can cause dryness of the skin and mucous membranes, graying and loss of hair. Moreover, vitamin A deficiency increases the risk of developing various types of cancers.

Preventive and therapeutic significance

The wide-ranging deficiency symptoms mentioned above show just how important vitamin A is both in terms of prevention and treatment. By playing a major role in the build-up and immunological efficiency of mucosal surfaces, it helps the body protect itself against respiratory tract diseases. This holds particularly true for viral infections and is therefore especially important given the COVID-19 pandemic. One of the most noticeable symptoms of this infection is a loss of the sense of taste and smell⁽¹⁷²⁾, which could indicate a special need for this vitamin, although there is disagreement among experts on this point⁽¹⁷³⁾. One study found that individuals with higher vitamin A levels also had higher levels of immunoglobulins (e.g. IgA, IgM, IgG1, and IgG4) and virus-specific neutralizing antibodies, as well as lower levels of cytokines, which are signs of healthy mucous membrane⁽¹⁷⁴⁾.

Importance for dentistry

The role of vitamin A in the formation of tissues, including bone, is also very important in dentistry, intact mucous membranes with a good immune function being essential for oral health. Also relevant to dentistry are bone growth and dentition disorders in children and adolescents, as well as gingivitis, stomatitis, and a loss of the sense of taste and smell⁽⁶⁾.

Recommended intake

Adolescents and adults should take 0.8 to 1.1 ml per day (the 1.1 ml 2666–3666 I.U.)⁽⁸⁾, pregnant women and nursing mothers up to 5000 I.E. There is an increased need during infections, stress and in the event of surgery. A recent COVID-19-related study recommends the intake of 40-60 I.U. vitamin D and 30-50 I.U. retinol per kg per day to prevent respiratory tract infections in adolescents and adults⁽¹²⁾. The human body itself can produce vitamin A from beta-carotene. Since only a small proportion of the beta-carotene ingested with food can be absorbed and converted, an additional intake of vitamin A is necessary. Depending on an individual's situations, this rate can be significantly reduced.

Safety

Levels of up to 10,000 I.U. per day are considered safe. This corresponds to the “no-observed adverse-effect level” (NOAEL), which denotes the highest dose at which no adverse effect was observed in studies. Higher doses should not be used for self-medication, as is exemplified in its use during pregnancy, where both insufficient and excessive supply of vitamin A can lead to fetal malformations⁽⁸⁾.

Cofactors

Zinc is essential to vitamin A metabolism⁽⁸⁾. Vitamin E protects the sensitive vitamin A from oxidation and regulates its metabolism. The interaction of vitamin A and vitamin D is described in detail under the paragraph on vitamin D cofactors (see section starting on p. 60).

Importance for the THE SWISS BIOHEALTH CONCEPT

Because of its key role in mucosal immunity, which is particularly important during surgery, and its major contribution to bone regeneration, vitamin A is an important component of the pre- and post-operative micronutrient balance within THE SWISS BIOHEALTH CONCEPT (see p. 46).

Restoration

Within the context of “THE SWISS BIOHEALTH CONCEPT”, the term “restoration” refers to a defined, systematic algorithm of treatment sequences that aim to:

- reduce the strain on the immune system as quickly as possible
- ensure the greatest possible safety, especially as regards infection and intoxication
- provide rapid, standardized treatment in a time-efficient and cost-effective manner. This point is often neglected by dentists and oral surgeons in that they consider only the primary costs their patients incur (dentist’s fees, material, dental lab work). It is often the case, however, that secondary costs prove far greater for patients: travel, accommodation, absences from work, inability to work due to swelling, etc.

RESTORATION SEQUENCE

The ALL IN ONE CONCEPT follows the below steps in the order presented in one appointment wherever possible, or over two to three appointments on subsequent days if necessary. This is the “treatment sequence”. Crucially, no further invasive or detoxifying measures are taken during the day to three days after the surgery, because it is during this period that patients go through the so-called “catabolic phase”. During the development of this concept, Dr. Dietrich Klinghardt’s four-phase concept was borne in mind. It encompasses a treatment period of up to two years (Fig. 1), within which the few days of biological dental therapy account for around 60% of the improvement in health. The dental treatment comprises a total of five steps.

1. First step: Gentle, stress-free metal removal using pro-

TECTIVE measures to relieve the strain on the immune system without burdening the body, preferably the day before surgery.

- Amalgam removal using six-fold protection and insertion of CEREC ceramic inlays or long-term temporaries.
- Removal of crowns/bridges using cofferdam protection and replacement with long-term temporaries.
- Removal of crowns using cofferdam protection and of any titanium implant abutments.

2. Second step: Removal of all root-canal-treated and infected teeth, root residues, wisdom teeth, FDOJs and foreign bodies, quadrant by quadrant, followed by immediate implant placement. The following sequence should ideally be followed during the operation: Women: bottom right, top right, bottom left, top left Men: bottom left, top left, bottom right, top right This sequence is derived from the YIN-YANG system, ensuring the immune system is relieved of strain in the quickest, most far-reaching manner possible (according to this principle, women should sleep on men’s “heart side”, namely to their left).

Third step: Production of fixed, metal-free long-term temporaries to stay in the mouth for three to a maximum of 12 months. These temporaries should look very similar to the final crowns, protect the teeth and implants, restore the bite height and promote detoxification. Patients are instructed not to chew any hard foods on the implants for the first six weeks after the procedure, so as not to impair complication-free healing. Temporary restorations must not come loose during the healing phase. In order to improve their hold, a light relining of the temporary restoration using thin-flowing plastic (flow) has always proven effective. This results in a better hold by ensuring a more

The four treatment stages:

Phase 1: 3–4 m: establishment of normal physiology

Dental therapy: 1–2 d Removal of metal and dead teeth/
Titanium implants/osteonecroses (FDOJs, etc.)

Phase 2: 2–6 m: detoxification of all systems (DMPS, chlorella, etc.)

Phase 3: 2 m: immune modulation (90% of all symptoms are caused by
immune responses to toxins and germs)

Phase 4: 6–12 m: reduction of pathogenic germs and normalization of the
microbiome

3–4 m 1–2 d 2–6 m 2 m 6–12 m 18–24 m





Figure 1: This overview illustrates how dental therapy according to Dr. Karl Ulrich Volz (picture on the right) is embedded into Dr. Klinghardt’s four-phase (picture on the left) concept.

precise fit. As another option, small hemispheres can be placed on the implant abutment and also on the opposite provisional restoration. The provisional restoration can also be roughened again at the proximal contact to an adjacent tooth and a small hole can be drilled in it. A bond can then be formed with the neighboring tooth using a small drop of flow. Fourth step: After three to four months, an examination is carried out, checking how the implants have healed using the Anycheck test, and, if necessary, commencing further treatment in this temporary restoration phase. The long-term temporaries are also used to perfectly adjust the bite height during this phase. Fifth step: As soon as a stable, healthy state has been achieved thanks to the long-term temporaries, these are replaced with the final ceramic crowns.

AMALGAM REMOVAL/METAL RESTORATION

With mercury being so dangerous, its removal requires special protective measures, and the body should be optimally prepared beforehand. Our detoxification protocol described below starts as early as 14 days before the planned appointment and is carried out following the instructions from the environmental physician or naturopath referred the patient. This promotes the body's extremely important detoxification capacity, as, even under the most stringent of protective measures, a certain amount of mercury vapor entering the body during amalgam removal is unavoidable. Stepping up the supplement regime provides the body with the preconditions under which to optimally capture and excrete these toxins. In conjunction with the special protective measures, this minimizes, if not eliminates, the risk of the removal causing acute poisoning. The detoxification protocol supports the body in its detoxifying function with the aim of ensuring the amalgam removal phase can be completed without further complications. By no means does it constitute complete heavy metal drainage. Complete detoxification cannot be carried out correctly until all of the interference fields in the oral cavity have been thoroughly removed (metal and interference field restoration).

Detoxification protocol

In the days before the amalgam is removed, all instructions regarding diet and lifestyle (see fig. 4, p. 43) should be followed with particular care. The following dietary supplements and medicines should be taken 14 days before amalgam removal and continued to be taken for 14 days afterwards:

- A good general micronutrient supply as provided by BASELINE and BOOST.
- *Chlorella vulgaris* 8-10 pellets three times per day (30 min. before meals, last dose just before bed)
- Omega-3 fish oil: 2 capsules with breakfast, 4 capsules before bed

There continue to be discussions as to whether amalgam should be removed as quickly as possible in a single appointment or over a series of appointments with plenty of time in between. These discussions are futile and misdirected: Suggesting staggered removal over several appointments clearly implies that those in favor of this method do not feel equipped to remove the amalgam with absolute safety and without subjecting the patient to any sort of contamination or stress. If this is the case, the dentist should not be removing any amalgam at all, because it consists of over 50% mercury—the most poisonous non-radioactive element, which can cause the most severe of illnesses even in the smallest doses^(1,2). Instead, the correct approach is to follow an amalgam removal protocol as described below, which ensures the patient is not contaminated with any mercury. Provided this is done, the amalgam fillings ought to be removed as quickly as possible in as few appointments as possible.

Amalgam removal using six-fold protection.

It is easy to make mistakes during amalgam removal that can have fatal consequences for the patient. It still happens that dentists drill the filling out without any protective measures whatsoever. They have not been made aware of the issues set out above, because these deviate from conventional university teachings. However, in doing so, they release huge quantities of highly toxic, anorganic mercury vapor (HgO)⁽³⁾. After routine amalgam removal like this, it is not uncommon for patients to experience neurological complaints, chronic fatigue, joint and muscle complaints or other symptoms recently added to this list. For this reason, it is imperative that six-fold protection be used when removing amalgam fillings (Fig. 2):

- Using a cofferdam, a protective rubber cloth, provides protection from amalgam chips and fragments, which could come loose and collect in the tissue. The most recent generation is latex-free and made out of silicone (ROEKO:Flexidam). This has the advantage that mercury in gaseous form cannot penetrate silicone.
- Using a clean-up suction device. This provides additional protection from mercury vapor, as the device is positioned above the tooth being treated.
- Carefully drilling at a low speed using a carbide cutter to prevent the development of toxic mercury vapors.
- Using a gold-coated nose guard. This absorbs mercury vapors, because gold and mercury have a high mutual affinity. Breathing masks categorized as FFP3 are good and affordable alternatives. They protect not only against 99% of mercury but also against all toxic dust, smoke and aerosols smaller than $0,6 \mu\text{m}$, carcinogenic and radioactive substances as well as viruses, bacteria and fungal spores.
- Using an iQ-Air ambient exchanger: a type of "nozzle" positioned as closely as possible to the oral cavity. The

device then works similarly to a vacuum cleaner, using an extremely high suction force to extract all the air in the area surrounding the heads of the patient and the staff performing the treatment, filtering out mercury and pathogens before releasing it back into the room.

- Once the amalgam has been removed, a chlorella algae insert is placed in the tooth to bind any mercury remaining there.

Supplying oxygen through a nasal tube is no longer recommended, because, according to Dr. Klinghardt, it opens the blood-brain barrier and does more harm than good. Depending on the state of the patient's health, the teeth are either treated immediately and conclusively (using ceramic or composite) or temporarily with cement (glass ionomer cement fillings) until drainage is complete. Infusions of high doses vitamin C and other micronutrients may also be provided on an optional basis. Large quantities of water should be drunk after treatment. Subsequently, a professional and personalized amalgam drainage plan should be followed under the guidance of an environmental physician or naturopath.

Removal of metal inlays, metal crowns and metal bridges
All metals are removed using cofferdam protection at the very least to prevent metal particles from being absorbed by the mucous membranes and the gastrointestinal tract. In the event of serious illnesses such as ALS or upon the patient's request, maximum protection (see amalgam removal) may also be used for general metal removal.

Explantation of titanium implants

Using a special system (Implant Removal Set®, Neobio-tech) it is possible in most cases to unscrew the titanium implants from the bone without incurring the usual bone defect. Depending on the state of the patient's health, a fully ceramic implant can then be fitted directly without having to wait for the bone to heal (Fig. 3). Switching out titanium for ceramic in this way avoids bone loss and saves time, because the new implant can be screwed directly into the same bone cavity. In cases where there is no titanium intolerance and no electrosensitivity, the tita-

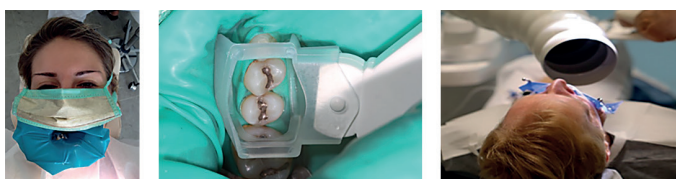

Figure 2: Amalgam removal using six-fold protection.

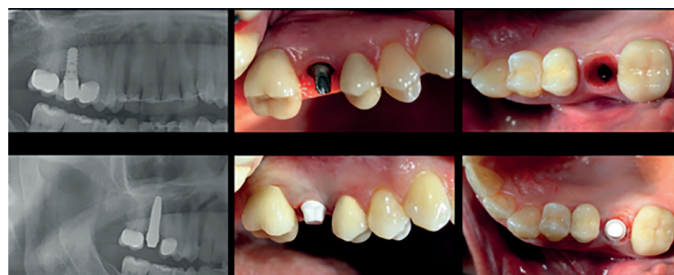

Figure 3: Explanation of a titanium implant and insertion of a ceramic implant

anium implant may be left in for the time being. The structure and the screw on the implant are usually made of a gold alloy, and must therefore always be replaced with a fully ceramic structure (abutment) with a titanium screw to avoid a localized current flow.

WISDOM TEETH AND FDOJ (FORMERLY NICO)

FDOJ (fatty degenerative osteonecrosis and osteolysis of the jawbone), formerly NICO (neuralgia inducing cavitation osteonecrosis) or IO (ischemic osteonecrosis). It is justified to ask why wisdom teeth should play such an important role in western industrialized nations and why they are so often displaced transversely in the jaw, have insufficient room to erupt and therefore require surgical removal. Has nature made a mistake? No, rather it is a flaw in human behavior. At some point, mothers in western industrialized nations started to shorten the period during which they breastfed, giving it up entirely or expressing breast milk and giving it to their babies in bottles. Suckling at the mother's breast, however, alongside the many other emotional and psychological advantages, serves to improve the stomatognathic system and encourage the jaw to develop forwards⁽⁴⁾. To a certain extent, this is orthodontic in nature: The constant pressure exerted during suckling over many months is transferred to the jaw. If infants were breastfed for one and a half to two years, as nature intended and still is the norm in many indigenous cultures, the jaw would be large enough to provide sufficient space for the wisdom teeth.

This is largely infeasible in our society, which is why young people have their wisdom teeth surgically removed, usually between the ages of 12 and 20. This is not ideal, as this is the period during which young people suffer from general mineral deficiency due to a strong growth spurt, often exacerbated by unhealthy eating habits at this age. All four wisdom teeth are usually removed at once, focusing on speed, i.e. the shortest possible surgery times. Usually,

the wound is not fully cleaned or sterilized (e.g. using ozone), and is then consigned to secondary healing by inserting a strip containing antibiotics and cortisone, blocking the immune system. Antibiotics are almost always given orally as well, further weakening the immune system. The operation is usually very invasive (“major surgery, major incision”) and traumatic, and therefore involves severe swelling. However, this procedure prevents the switch into the parasympathetic tone, which is necessary for effective healing. Under these conditions, the bone defect is unable to heal, which is why around 90% of all wisdom tooth operations lead to an FDOJ. This means that, while the gum tissue and often the hard bone underneath (known as “compact or cortical bone”) do heal, a cavity remains, which is either completely empty, filled with pure fat or with a mixture of fat and dead trabeculae. This is also known as “chronic fatty degenerative inflammation”. The correct radiological term is “osteolysis of the jawbone”. The former term “NICO” has been replaced with “FDOJ” (fatty degenerative osteonecrosis of the jawbone). This is important when communicating with radiologists, insurance providers and experts. The formation of an FDOJ can only be avoided by strictly following the BTP Biological Treatment Protocol described here. In many cases, however, broken wisdom teeth and those in a row must also be removed, as they constitute an interference field. In the course of the removal, an FDOJ is then found behind the wisdom teeth. Dr. Volz has found a simple and logical method of differentiation: If keratinized “attached gingiva” can also be found around the wisdom tooth on the dorsal side, the wisdom tooth can be left in. In this case, the “immunological door” is closed (gingiva = ectoderm, bone = mesoderm, see also 38). There is only ever really enough space if the wisdom tooth is not only able to erupt, but also if there is up to 15 mm of horizontal bone behind it. Only in these cases is it possible for continuous keratinized gingiva to form. Otherwise, there is a connection between the oral cavity and the bone in the form of a hugely dirty gingival pocket. In these cases, the “immunological door” is wide open. 2D imagery is not well suited to the diagnosis of an FDOJ. It is only with a great deal of experience that a surgeon may be able to identify an FDOJ on just an orthopantomogram (panoramic x-ray). A reliable diagnosis can be made based on a 3D recording, a DVT. When gum tissue above an FDOJ is opened, the condition can usually be detected from the outside thanks to the yellow to brown discoloration of the bone caused by LDL cholesterol deposits. The blood also glistens due to the floating droplets of fat released by opening the bone. Taking a closer look at the histopathology of these fatty degenerative bone necrosis areas, you can see thin trabeculae of bone where the bony interconnections have been lost. The bone marrow, containing fats, shows mucoid degenerations with inter-

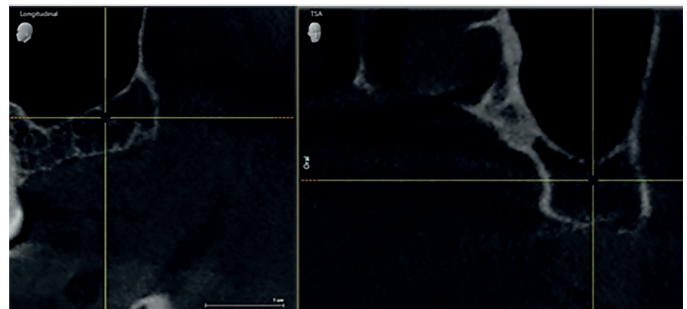


Figure 4: FDOJ on a DVT

stitial edema. In principle, the number of fat cells is strikingly increased⁽⁶⁾. This is chronic, silent inflammation resulting from the lack of an acute cellular inflammation reaction due to the significantly increased amount of interleukin-1 receptor antagonist (IL-1ra)⁽⁷⁾. In this case, IL-1ra acts as a masking cap, causing the immune system to fail to regulate the excessive expression of dangerous inflammatory mediators such as RANTES (Regulated on activation, normal T cell expressed and secreted) and FGF-2 (Fibroblast growth factor 2) down. This shows in the strikingly low IL-6 and TNF- α -levels⁽⁶⁾—a sign of the fact that the immune system has not registered anything out of the ordinary! (Fig. 6)!

The tissue shows fatty, degenerative and osteolytic components due to insufficient nutritional supply. Expanded intertrabecular spaces often contain small, necrotic bone fragments, fatty micro-bubbles and reservoirs of liquefied fat, resembling fat cysts, with nearly complete loss of adipocyte cell nuclei and retained, degenerated bone marrow. An accumulation of acidic glycosaminoglycans can also be seen in the bone marrow. Small nerve fibers are another distinguishing feature in most FDOJ biopsies, located in the vicinity of degenerated, fatty tissue^(6,8). The fact that these often cause facial pain gave rise to the name NICO (neuralgia inducing cavitation osteonecrosis). Alongside IL-1ra masking, FDOJs have another disastrous characteristic: In what could be deemed a “bone infarction”, a bone necrosis, the connection to vessels and therefore the connection to our body’s own healing, repair and immune systems is impaired. This means that an FDOJ can barely be bettered using non-invasive therapy or medicine. At the same time, FDOJ waste products cannot be transported away, because lymphatic drainage is inactive. FDOJs do, however, have nerve vessels, which can transport toxins to the ganglia and other areas of the central nervous system (CNS) by axonal transport (see p. 18) very quickly cause severe which can cause nerve pain

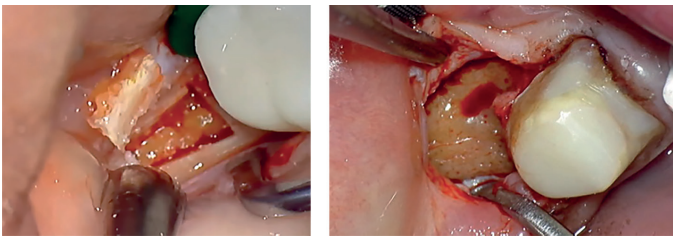


Figure 5: FDOJ in the lower and upper jaws

(neuralgia) or even nerve failure! Intraosseous inflammation has readily been recorded among patients with facial neuralgia⁽⁹⁾. FDOJs always go hand in hand with significant increases in inflammatory mediators, namely RANTES and FGF-2^(6,10,11). Both of these mediators are also always to be found in tissue in the event of severe illnesses such as ALS, MS, rheumatoid arthritis, cardiovascular diseases, breast cancer and other tumors, and are always present in extremely high concentrations^(6,10,12-17) (Fig. 7). Due to the production of RANTES and FGF-2, among other aspects, FDOJs are considered a significant cause of autoimmune diseases. RANTES is a member of the chemotactic cytokine family (chemokines). RANTES' chemotactic processes carry T cells, dendritic cells, NK cells, mast cells, eosinophil and basophil cells⁽¹⁸⁾ to areas that are infected or susceptible to inflammation. This can promote the development of MS and Parkinson's in the CNS. The impact on mast cells increases the risk of allergies, hair loss and thyroid gland diseases. Melanoma cells also excrete RANTES, which stimulate the growth of tumor cells. In Hodgkin lymphoma, malignant Sternberg-Reed cells produce RANTES, which trigger the chemotactic migration of mast cells into the tumor tissue⁽⁶⁾. Unfortunately, at present, there is no non-invasive or partially invasive therapy that can heal an FDOJ. Only the minimally invasive, atraumatic yet radical surgical FDOJ removal as per the THE SWISS BIOHEALTH CONCEPT can achieve comprehensive healing at the site, reduce the symptoms associated with it and, in the best case scenario, eliminate them entirely. Alongside neuralgic complaints, FDOJs are particularly readily associated with symptoms related to the meridians that run through this area, that is the heart/circulation, the triple warmer and the small intestine meridians: chronic fatigue (CFS) and lack of energy (burnout), all sorts of cardiovascular complaints, suprarenal gland deficiency, weight gain, allergies, skin diseases, problems with the small intestine, autoimmune diseases and Lyme disease in particular. Among these patients, FDOJs harbour large quantities of Borrelia, Babesia and Bartonella, to whom the FDOJ tissue is

the perfect environment in which to multiply and transmit their toxins into the body via nerve fibers. Particularly if Bartonella are elevated, so is the risk of infection and wound healing disorders. These patients require additional protection by means of daily antibiotics infusions for the week after the FDOJ surgery. The FDOJ tissue not only contains viruses, fungi, bacteria, parasites, FGF-2, RANTES and fat cysts, but also large quantities of heavy metals such as mercury, arsenic and lead, aluminum and, ever more frequently over the last few years, glyphosate, found in pesticides. Treatment now entails removing all soft material of this "chronic fatty degenerative inflammation" until only hard bone substance is left and the yellow coloration has completely disappeared, with no more fat droplets floating on the blood. The significance of the treatment is further confirmed by observing the size of patient's pupils: due to the chronic nature of the so-called "silent inflammation", patients find themselves in permanent sympathetic tone and their pupils are dilated. Once the FDOJ has been fully eliminated, the pupils become smaller, as the patients now enter a state of relaxation, i.e. they switch into the parasympathetic tone. Ozone is then used as sterilizing agent and the defect is filled with A-PRF membranes and sealed with absorbable sutures (Atramat), preventing contamination by saliva. Dr. Klinghardt developed a method to ensure maximum safety during the clearance of the FDOJ, which has subsequently been optimized under his guidance at the SWISS BIOHEALTH CLINIC. It involves removing material from the FDOJ during cleaning and placing it in a sterile glass vial.

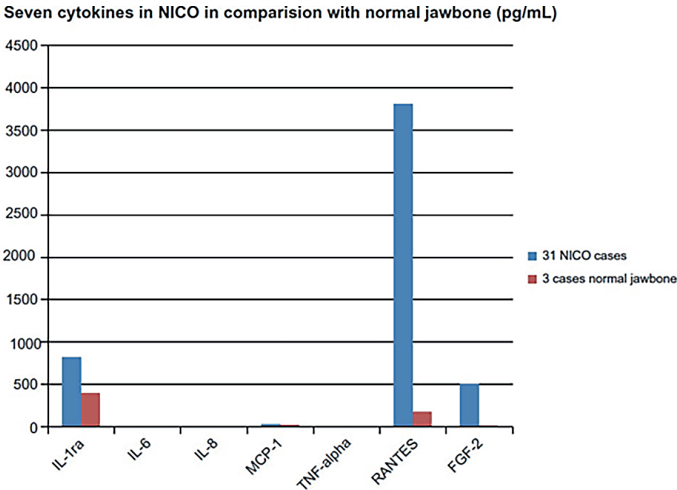


Figure 5 Distribution of seven cytokines in NICO (n = 31) and in normal jawbone (n = 3) (values in pg/mL). Abbreviations: FGF-2, fibroblast growth factor; IL; interleukin; MCP-1, monocyte chemotactic protein 1; NICO, neuralgia-inducing cavitation osteonecrosis; ra, receptor antagonist; RANTES, regulated upon activation normal T-cell expressed and secreted/chemokine ligand 5; TNF, tumor necrosis factor.

Figure 6: Cytokine distribution in FDOJs⁽⁶⁾

To check the cleaning result, the practitioner can now project the information via a sterile glass rod in different directions into the FDOJ cavity and, at the same time, use the ART (autonomous response test) by Dr. Klinghardt to test whether the cavity was also perfectly cleaned, even at a microscopic scale. If the test is positive, the surgeon has to continue cleaning and clearing out in the direction of the glass rod until the test no longer responds in any direction. Upper jaw FDOJ: I-PRF infiltration, alveolar ridge incision without vertical relief and wedge-shaped incision below as a tuber plastic in order to reduce the thickness of the connective tissue on the tuber. Complete removal of the tuber and cleaning of the area using manual instruments and the piezo tool with the diamond-coated ball-shaped tip, ozone, possibly ART-TEST, A-PRF and absorbable sutures. Lower jaw FDOJ: I-PRF infiltration, alveolar ridge incision at an angle of approximately 30% in the vestibular direction in order to protect the lingual nerve in a similar manner to the method used for wisdom tooth removal. No vestibular relief, fenestration with piezo saw, clearing of the FDOJ exclusively with piezo instruments (piezo tool with diamond-coated ball-shaped tip) in order to protect the inferior alveolar nerve. Possibly ART-TEST, filling and covering of the defect with A-PRF membranes following ozone application. A deep apical mattress suture (absorbable suture material) is subsequently placed over the matrices. The wound is then closed using a continuous suture or single button sutures. The use of piezo instruments was introduced to the FDOJ treatment by Dr. Volz in 2013, revolutionizing it in the process, as it allows for the extremely quick, safe, gentle and, above all, complete removal of the necrotic material. Piezo is an ultrasound-based based method in

which the instrument vibrates/oscillates at great speed, meaning that damage is avoided in the event of potential contact with a nerve or vessel⁽¹⁹⁾. The piezo method has been used in the field of brain and spinal surgery for many years⁽²⁰⁻²²⁾.

Empty jaw sections

FDOJs not only occur in the wisdom tooth area, but also in other dental regions. They may be caused by foreign bodies such as overfilled root fillings, amalgam from fillings and root residues. However, a dry socket can also result in the formation of an FDOJ. The formation of a dry socket is countered by priming the bone with a round bur, using ozone (the strong electromagnetic field at the glass tip activates bleeding) and then protecting the socket from saliva. Saliva has a very strong haemostatic effect, which at this stage is extremely undesirable, as the socket then completely fills with saliva, thus keeping out blood. The most reliable way to fully seal the socket is by completely filling it with A-PRF membranes and/or preferably by immediately placing ceramic implants.

Ankylotic root-canal-treated teeth

However, FDOJs are also frequently found in the sockets of ankylotically impacted teeth, as the “ligament insulation layer” is no longer present and toxins can permeate the bone unimpeded. It is interesting to note here that the better and the more complex the root canal treatment is, the higher the risk of ankylosis and thus an FDOJ! The poorer the quality of a root canal treatment and the more insufficient it is, the more likely it is that a cyst will be found. In contrast to the FDOJ, this indicates a reasonably intact immune system, as the cyst sac seals off emerging

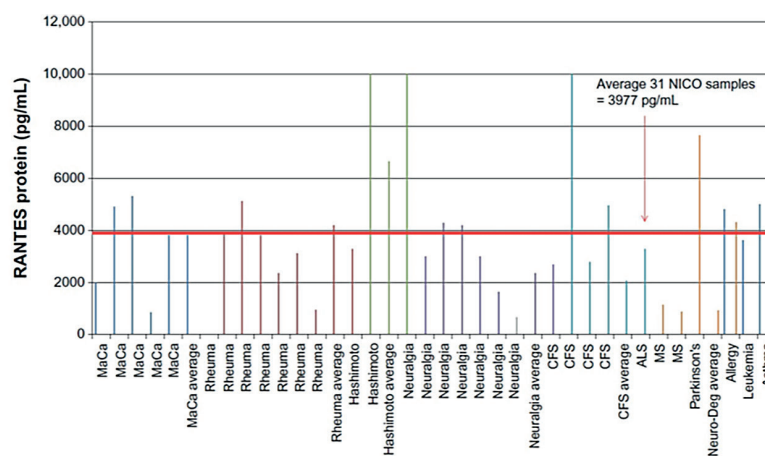


Figure 7: RANTES evidence in FDOJ tissue linked to several illnesses⁽¹⁾

bacteria from the rest of the body and forms a kind of “prison wall”. Furthermore, the bone around the cyst sac is always very hard and well mineralized, as this increased mineralization is in turn supposed to seal off the body from the inflammation. Therefore, even if immediate implantation is not planned, a “drilling test” should always be carried out through the socket wall, the socket tip and into the septum. If the tissue underneath it is soft and there are fat droplets floating on the escaping blood, then an FDOJ is sure to be present and needs to be cleaned. It is often necessary to remove large sections of the socket wall and the fatty degenerative lacunae often spread deep beneath the adjacent teeth, only the oral and vestibular compact bone of the jaw remaining after cleaning or FDOJ treatment. Towards the end of the treatment, the patient will begin to visibly relax; it is not uncommon for patients to fall asleep during the treatment. In around 50% of FDOJ treatments, patients feel a significant improvement even as they are getting up from the chair. Setting in no later than two to three days after the procedure, they experience relief, feelings of freedom, improvements on the associated meridians, etc.

EXTRACTION OF ROOT-TREATED TEETH

Many root-treated teeth show some form of inflammation of the surrounding tissue. This can be observed particularly well with the help of three-dimensional X-ray images (DVT). The cyst at the root tip is nothing more than a kind of capsule that is formed around the infected area by the immune system itself in order to shield it from the rest of the body. Especially infected teeth often ankylose with the surrounding bone. Metabolic processes are shut down at a local level—the body walls the tooth, creating a kind of prison, as it were. The only way to escape this chronic intoxication is to surgically remove the dead teeth. The surrounding inflamed or cystic tissues must be completely eliminated. Soft bone should be curetted without leaving any residue. The tissue is then disinfected using ozone. The placement of implants next to existing root-treated teeth should be rigorously evaluated in order to avoid possible failure due to focal infection⁽²³⁾. When removing root-treated teeth, immunological pre- and post-treatment (p. 45) must be performed to ensure that the body is able to heal the wound, generate new and healthy bone and prevent infection. As a rule, extraction is always carried out as gently as possible—following the removal of the tooth, the gingiva and bone must be left completely intact. Where possible, the attached gingiva should not be removed. The ligament, the elastic fiber system that holds the root, must be completely removed, however, as the brain will otherwise not realize that the tooth has been removed and would only initiate the corresponding bone growth factors following a resorption period of a few days/weeks.

Extraction

The gingiva is carefully detached from the tooth with crescent-shaped surgical scalpel blade No. 12. Using the forceps, gentle and isostatic leverage forces are exerted on the tooth in the sense of a horizontal eight until it is loosened. There are two options that make the extraction easier: If the tooth to be extracted is shortened a few days/weeks prior to the extraction date and is thus taken out of occlusion/no longer subjected to stress, it will grow upwards in the direction of the occlusal plane in the period prior to extraction and can then be removed much more easily. This is seen time and again during the extraction of broken teeth and root remnants, which are, generally speaking, always very easy to remove. Another option is to start with the extraction and then, after a few minutes of applying force, leave the tooth for a while (15 to 30 minutes) and perform another planned treatment in the meantime, for example. The bleeding into the periodontal space that occurs during this time gives rise to considerable pressure on the root in the direction of extraction, meaning that the tooth can now be removed easier and with less force.

Root infraction

If the tooth cannot be removed by means of ordinary extraction, under no circumstances—as is unfortunately still often the case—is an osteotomy to be performed. The removal of good and healthy bone using the so-called Lindemann bur in order to loosen a dead root is tantamount to physical injury and demonstrates a lack of dental skills and biological understanding. A logical method that is gentle on the tissue is root infraction, which involves the milling of a Mercedes star or a Swiss cross into the root. The root fragments are then removed bit by bit with a small lever. This method is easier to perform if slits are made along the root canal all the way down to the root tip or even slightly beyond (caution: roots close to the maxillary sinus or the nerve). This is usually very simple, as the root canal is either hollow or filled with a soft root-filling material.

Densotomy

If even the root infraction (see above) does not yield success, the root is then “pulverized” using a long, Rose bur and bored away completely. This is easier than expected because the drill rotates smoothly and evenly on the root dentine but immediately becomes very unsteady and has a “knocking” effect when it comes into contact with bone. This allows for a very precise differentiation to be made between bone and root. Here, it is helpful to work with a strong loupe and a bright light source as well as to attach the fine tip of the Surgitip® aspirator. In most cases, the root tip can be removed at some point using a fine instrument, for example the “papilla elevator”. Compared to a

lever, this has the advantage that it is extremely thin and can be slid between the bone and root without causing any damage to the bone.

Separate removal of a cyst or a foreign body in the area of the tooth tip

Cysts or foreign bodies can be removed by folding the gingiva down from the socket margin, as no scars are formed here and the blood supply is not destroyed. To this end, however, the sulcus edge incision normally has to be extended over several teeth in order to be able to fold down to the root tip. Alternatively, the opening for the removal of the cyst or a foreign body in the area of the root tip (retrograde root filling with amalgam or cement, overfilled root filling, broken canal instrument, etc.) can also be made via a vertical incision in the area of the free gingiva alongside the surgical site, meaning that an undamaged periosteum is subsequently achieved over the defective area. Horizontal incisions must never be made, as the blood vessels and the meridians run vertically and their function would be impaired more than is absolutely necessary. The cyst or foreign body can now be removed by sight. Here, it is important to ensure that any bone discolored with amalgam or other metallic foreign bodies is completely removed and that any metal tattoos located in the soft tissue are cut out. After the defect has been filled and covered with A-PRF membranes beforehand, the incision is then closed using very fine, continuous, saliva-proof sutures (better tension distribution compared to single button sutures and thus less scarring).

In all cases, the extraction socket is optimally cleaned, curretted and monitored for FDOJs (perform test drill!), sterilized using ozone and filled with procaine. It is ensured that a complete filling is carried out with the blood clot. Procaine is also injected into the vestibular fold by way of neural therapy. If an implant is not to be placed in the socket of the extracted tooth immediately, or if there are still void spaces between the implant and the socket following implant placement, these are covered using A-PRF membranes. In the event of insufficient blood circulation (dry socket) or an opening in the maxillary sinus (Oroantral Communication = OAC) without immediate implantation, the socket should be closed in a saliva-proof and air-tight manner with a Cytoplast/Tefgen membrane in addition to the filling with A-PRF membranes and protected against the impact of food residues. By way of exception, the gingiva must be folded down approximately 5 mm in line with prioritization. The membrane is trimmed and approximately 3 mm is pushed under the gingiva, which is closed in the area of the papilla with single button sutures. The rough structure of the membrane is thereby positioned adjacent to the oral cavity, as this

structure of the non-expanded Teflon membrane promotes the growth of soft tissue. If non-absorbable, the sutures are removed after about two weeks and the membrane after approximately four to six weeks. These can be removed very easily using a probe without the need for anesthesia. In the case of seriously ill patients, such as those with ALS, the complete removal of foreign bodies can be the difference between life and death. As we never know what state of health our patients will find themselves in ten or 20 years down the line, we must take precautions now in order to ensure that these deposits are fully removed.

OZONE TREATMENT

There are various ozone devices on the market. We prefer the very powerful OZONE DTA device, which is distributed by SDS Swiss Dental Solutions (www.swissdentalso-lutions.com). The strength is set to around seven to ten and the socket is aspirated at the same time, as the ozone should not be inhaled (exception: treatment of bronchitis) and as it can only take effect in the presence of atmospheric oxygen. At the tip of the probe, a strong electromagnetic field separates atmospheric oxygen into oxygen radicals with atomic oxygen which has an extremely strong bactericidal, virucidal and fungicidal effect. As these oxygen radicals are very reactive, they combine with the oxygen to form ozone O_3 (Fig. 8), which has a bacteriostatic effect. The concentration at the tip of the probe is between 10 and 100 mg/ml. However, ozone is not stable and breaks down again into the now active oxygen and oxygen radicals. It has a sterilizing effect on the bone up to a depth of 2.5 cm and is completely harmless to human cells, as oxygen cannot harm the human respiratory chain. In the respiratory chains of bacteria, viruses and fungi, however oxygen results in a metabolic breakdown and thus to the death of these pathogens⁽²⁴⁾. This provides dentists with a highly effective instrument for local sterilization that is completely free of side effects. Herpes or oral aphthae on the palate, mucus membranes or lips can be treated very effectively with the surface probe. In most cases, this shortens the healing process from around a week to a few hours. A further positive secondary effect is the short-term increase in blood flow due to the very strong electromagnetic field, thus meaning "dry sockets" are avoided.

BLOOD CONCENTRATES (A-PRF AND I-PRF)

These are plasma components extracted from the patient's blood, which are rich in growth factors and fibrin. Platelets (thrombocytes) not only stimulate blood coagulation, but also contain the largest volume of human growth factors. They thus allow for tissue regeneration after injuries or surgeries. These growth stimulators can be used in a very specific way by separating them from

the platelets or activating them together with the thrombocytes separated from the rest of the blood and introducing them to locations where growth and cell activation are to be stimulated on a targeted basis. The highly effective and side-effect-free PRGF therapy was developed in 1999 by a Spanish working group led by Dr. Eduardo Anitua⁽²⁵⁾. It is based on the activation of the patient's own blood platelets with the aim of stimulating the tissue and accelerating its regeneration^(26,27). This results in the shortening of the rehabilitation or convalescence period after surgical procedures. Overall, the wound healing phase is shortened by the concentrated effect of growth factors, and the risk of complications is significantly reduced. However, this is an open system in which calcium sulfate has to be added to produce membranes.

PRF blood concentrates

The functional principles of PRF blood concentrates should be taken into account during every surgical procedure. The PRF concentrates are matrices. A distinction is made between liquid (I-PRF) and solid (A-PRF) matrices. PRF supports the wound-healing process. The surgical area heals more quickly and in a more pain-free manner. The formation of scar tissue in the surgical area is also reduced.

A-PRF = Advanced Platelet Rich Fibrin

This is a treatment which uses leukocytes and platelet-rich fibrin to promote wound and bone healing as well as anabolic forces. In addition, the function of the leukocytes supports the immune response, and the slow release behavior of the A-PRF has the advantage of allowing a constant release of growth factors (TGF- α 1, PDGF-AB, VEGF)⁽²⁸⁾ and matrix proteins (fibronectin, vitronectin and thrombospondin 1) over ten days. These growth stimulators do not require activation and can be applied at locations where growth and cell activation is to be stimulated in a targeted manner. They stimulate the fibroblasts in the tissue, which, in turn, form collagen and hyaluronic acid, which softens the tissue. This is particularly effective where fibroblasts normally build tissue, such as in cartilage, bone, connective tissue, vessels and in subcutaneous tissue. Here again, what is involved is autologous cell extract therapy. This therapy—which is as effective and free of side effects as the PRGF therapy—was introduced to the market in 2009 by Prof. Joseph Choukron⁽²⁹⁾, and is patented and approved across Europe. Well over 200 scientific publications have confirmed the effectiveness and biological safety of this therapy. PRF has been shown to improve soft tissue healing and can prevent the risk of “dry sockets” following the removal of teeth⁽³⁰⁾.

Injectable Platelet Rich Fibrin (I-PRF)

The injectable version of PRF—I-PRF—has many uses. In

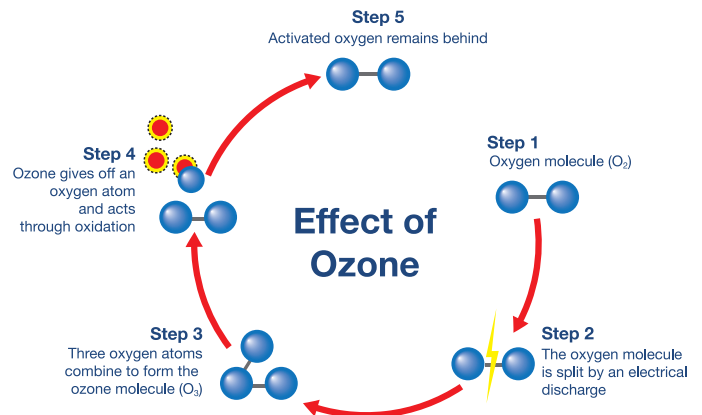


Figure 8: Effect of ozone (OSS Ozone System Solutions)

dentistry, it is applied as follows: I-PRF is injected into the vestibular fold in the area to be treated immediately prior to the beginning of a surgical restoration, thereby ensuring accelerated wound healing. It has the ability to release higher levels of various growth factors, induce higher fibroblast migration, and stimulate the expression of PDGF, TGF- β and collagen I^(31,32). Apart from its use in dentistry, it is indicated in muscle, tendon and joint disorders, for the treatment of persistent tendon base pain (tennis elbow, achillodynia), for the treatment of injuries (muscle and tendon tears), for cosmetic and regenerative treatments of the skin and the corrective filling of scars and wrinkles, as well as for the treatment of skin ulcers⁽³²⁾. A-PRF in particular plays a central role in THE SWISS BIOHEALTH CONCEPT, as its leukocyte content promotes “good inflammation”—i.e. the type of inflammation that results in tissue regeneration. A-PRF also contains 1.2% stem cells due to slow and gentle centrifugation process. Furthermore, it is much quicker and easier to use and there is no limit to the number of membranes that can be produced without effort (Fig. 9). Prof. Joseph Choukron has been personally teaching his techniques and concept at the SWISS BIOHEALTH EDUCATION CENTER since 2017. Prof. Shahram Ghanaati has standardized the concept of PRF production and scientifically established it internationally under the term LSCC (Low-speed centrifugation concept)⁽³³⁾. Using three manufacturing protocols, the application of LSCC allows for both liquid and solid PRF matrices to be produced. The relative centrifugal force (RCF) is decisive in determining the type of the resulting PRF matrix. The following factors, in particular, influence the quality of the matrices: the patient's degree of poisoning (a large toxic load reduces the quality of the matrices), hydration level (can be improved through an abundant intake of fluid prior to blood sampling) and a

high flow rate during blood sampling. The QR code shows the different settings of the centrifuge and the resulting type of PRF matrix.

CERAMIC IMPLANTOLOGY

Implants have long since established themselves as the most attractive form of dental prosthesis. They offer security and look good, while also boosting self-confidence and ensuring a greater quality of life. Implants are such a good replacement for lost teeth that they usually last longer than your own teeth. Whether it is just one tooth being replaced or several implants recreating a firm set of teeth—the material needs to function stably, neutrally and compatibly over a period of decades. The high-performance ceramic zirconia, long used in orthopedics for artificial hip joints, fulfills these requirements like no other material⁽³⁴⁾. Zirconia ceramic is a white, metal-free, immunologically neutral and biocompatible material, which offers many advantages over metal⁽³⁵⁾. Whether it is an intolerance to titanium or general uneasiness about the prospect of having metal in your body that prompts the use of a metal-free solution—the esthetically-pleasing white ceramic implants made of the biocompatible, high-performance material zirconia are always an excellent choice and according to current studies are classified as equivalent to titanium implants⁽³⁶⁻⁵¹⁾. Beautiful white




Figure 9: PRF matrices

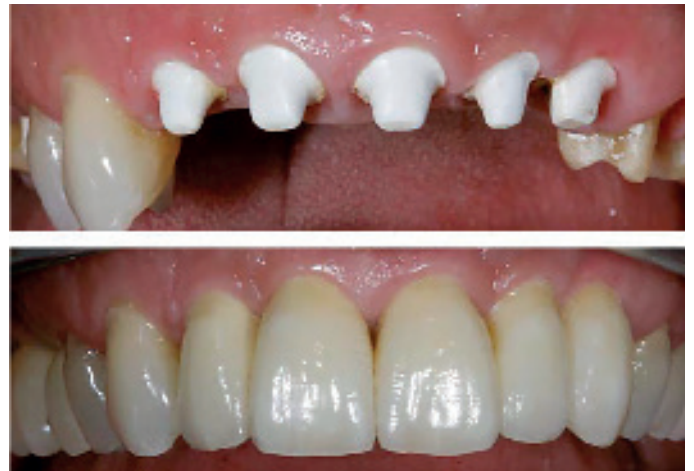

Figure 10: Preparation of ceramic implants (top) and final crown restoration (bottom)

teeth and pink gums are an expression of health, energy, vitality and self-confidence. The ceramic implants from SDS Swiss Dental Solutions are white through and through and come very close to the natural color of teeth, meaning they can contribute to preserving or restoring a radiant smile. In contrast to titanium implants, there are no gray tinges or annoying gray edges at the gingival cuff⁽⁵²⁾. Even if the overlaying gum is extremely thin or receding, the implant remains completely white. Not least for this reason, ceramic implants are ideal for use in the front teeth, in particular (Fig. 10). While the use of metal in the oral cavity can have a negative effect on the whole body, ceramic implants are outstanding in terms of their compatibility, as they are completely metal-free and fully biocompatible. Thanks to their optimal tissue compatibility⁽³⁴⁾, the regeneration of the gingiva around the implant is very good, and the gingiva even attaches to the zirconia. As ceramic allows for completely new and effective structures, the formation of bacteria and plaque^(34,53-59) and therefore the risk of gingivitis are significantly reduced—the risk of inflammation is even lower than with natural teeth⁽⁶⁰⁾. The patented surface structures and the bone-adapted thread shapes of the SDS implants allow for their excellent integration and mean they can be loaded after just a few weeks. There are SDS implants for all requirements. This means that your dentist will always be able to select the perfect implant. What's more, your dentist can completely dispense with metal during the implant procedure, as SDS provides instruments made from the same high-tech ceramic as the implants and crowns. This also means that no traces of metal are left in the bone. Founded by the ceramic pioneer and implantologist Dr. Karl Ulrich Volz, SDS is today regarded as a lead-

ing innovator in the field of ceramic implants. The Swiss company boasts unique proficiency in ceramics, many years of expertise and outstanding treatment results. A key success factor is the “from the practice, for practice” concept. SDS places the highest of demands on its products—these are certified according to current standards, carry the CE mark and were approved in the US by the FDA (Federal Drug Administration) in 2019.

Zirconia hi-tech ceramic

The introduction of high-performance zirconia ceramic implants by Dr. Volz revolutionized biological dentistry. For the first time, it was possible to offer a biological solution to the growing number of root-treated teeth and the increasing number of problems associated with this. Zirconia is a material that is 100% metal-free, harder than steel and can only be machined with diamond-coated tools. Zirconia is a “fully inert material” and has no free surface electrons. It is therefore absolutely neutral, cannot bond and cannot act as an interference field. Zirconium dioxide implants combine optimum biocompatibility with perfect esthetics^(36,61). The material can only be etched with hydrofluoric acid and has a melting point of over 2,680°C⁽⁶²⁾. Zirconia might be very complex in terms of its production, but is the implant material par excellence—a fact that has now been recognized by STRAUMANN, the global leader for titanium implants, who also introduced a zirconia implant to the market in 2014. The lifespan of a zirconia implant is far higher than that of a natural tooth⁽⁶⁴⁾, since the implant, due to its inert surface, is less prone to gingivitis than natural teeth (see Volz, Schlömer, Sidharta, Haase, University of Ulm, 2006⁽⁶⁰⁾), cannot be attacked by caries bacteria and does not have a nerve that could die and turn the tooth into an immunological problem. Zirconia implants also significantly outperform titanium implants: Titanium implants have a slightly higher short-term healing rate⁽⁴³⁾, since titanium heals by way of a chronic inflammation and will thus also heal relatively reliably in poor-quality bone. In contrast, ceramic implants heal without a sustained inflammatory process. Therefore, zirconia poses no risk whatsoever of consisting of peri-implantitis. Titanium implants, on the other hand, have been associated with peri-implant lesions after 10 years of wear in one study⁽⁶³⁾.

In the long term, therefore, zirconia implants have a significantly better success rate than titanium implants. As well, they offer esthetic advantages over grey-black titanium and its immunological risks and corrosion behavior^(55,65-72). With nearly 20 years of experience and about 20,000 zirconia implants placed, Dr. Volz has by far the most comprehensive experience in this field and has developed several implant systems (including Z-Systems). His long-standing experience with this material has led to

a growing understanding of the advantages and disadvantages of zirconia and to “thinking in ceramics”, which in turn has enabled the development of shapes (Fig. 11) and therapy protocols which eliminate—or at least reduce—its disadvantages and make maximum use of its advantages. Both the latest shapes and types of zirconia implants developed by SDS SWISS DENTAL SOLUTIONS AG (www.swissdentalsolutions.com) and Dr. Volz’s SCC Short Cut Concept are based on this knowledge. The main and most significant advantages of zirconia over titanium are the following: Zirconia is immunologically neutral, metal-free, has no free electrons, and its ivory color delivers excellent esthetic results^(74,75). Zirconia poses no risk of peri-implantitis⁽⁵⁵⁾ and has therefore a significantly higher success rate in the long term than titanium (Fig. 12 and 13). Soft tissue affinity: In contrast to titanium, zirconia implants⁽³⁴⁾ attach to both soft tissue (gingiva) and bone⁽⁷⁶⁾. As early as 20 years ago, Dr. Hans Rudelt (University of Hamburg- Eppendorf in cooperation with Tokyo University) was able to prove this by means of histological examinations of human material preparations sampled



Figure 11: SDS SWISS DENTAL SOLUTIONS ceramic implants

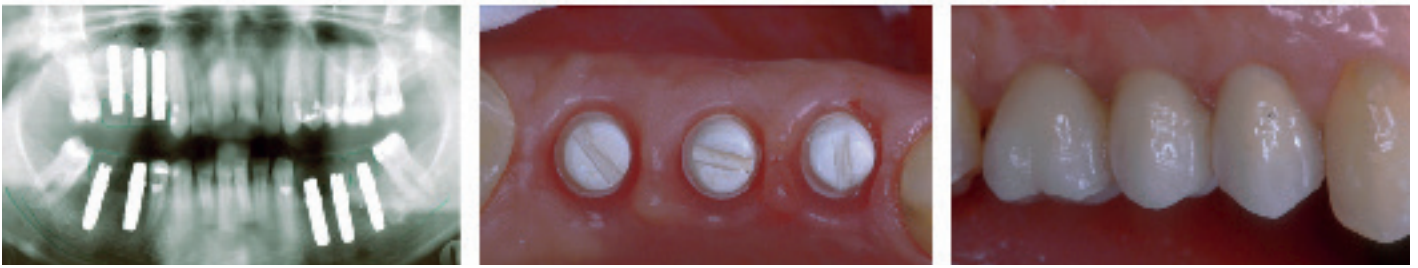

Figure 12: Dr. Volz was able to demonstrate the outstanding esthetic properties of ceramics by means of his first eight prototypes implanted as early as 2000. These implants remain in situ even today (2020) without any bone loss having occurred.

after an implant service life of 20 years. The research groups around Prof. Kniha from Munich⁽⁷⁷⁾ and Prof. Dr. Josep Oliva Damés from Barcelona also demonstrated this beyond any doubt. This affinity supports the “attached gingiva, prevents bacteria from penetrating into the area between implant and tissue and—for the first time in the history of dentistry—not only bone grafts but also ceramics can be used to replace lost bone. Until now, defects always had to be rebuilt with new bone, since soft tissue and esthetics depend on the bone available. However, since soft tissue also attaches to zirconia and thus “follows” this material, esthetics can, in many cases, be restored without the need for bone augmentation. With titanium implants, the entire implant must, in any case, be surrounded by at least 1 mm of bone in the mandible and at least 0.5 mm of bone in the maxilla⁽⁷⁸⁾. With zirconia implants, there is a flowing and variable transition, since both bone and gingiva attach to ceramics. Volz’s postulate: Whenever ceramics are in contact with bone, ceramics will act as an implant. Whenever ceramics are in contact with the gingiva, ceramics will act as an abutment. Titanium implantology tries to make use of these properties to some extent by placing zirconia abutments on titanium implants and recommending that they never be removed, as this might destroy the bond created between the zirconia and the gingiva (“One Abutment, One Time”).

- The lack of ductility of zirconia ceramics has another major advantage: In contrast to titanium, which is a highly ductile material, ceramic implants are anchored in the jawbone in an extremely rigid and immobile fashion. As a result, any thin bone tapering off around the implant is not resorbed. In many cases, bone augmentation will not be necessary, or the implant can be placed in narrower bones than with titanium. In addition, it was demonstrated that in the event of buccal dehiscence, zirconia implants will heal significantly better compared to titanium implants⁽⁷⁹⁾. Immediate implant placement with one-piece zirconia implants has proven to be the

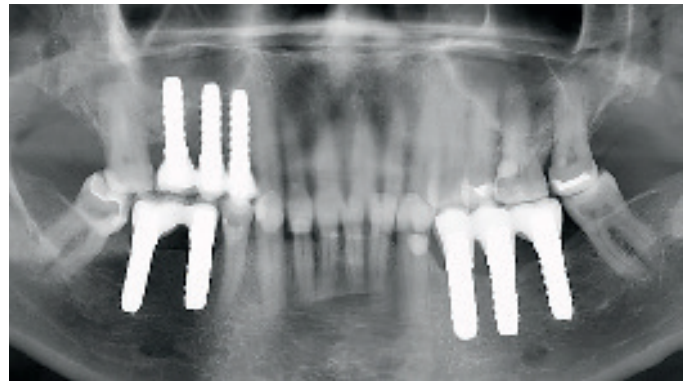


Figure 13: OPG x-ray taken in March 2019 showing the absence of bone loss around the eight implants.

optimum solution for single-rooted teeth. Zirconia implants have been available as two-piece implants for all indications since 2013.

The stability of even two-part SDS zirconia implants has meanwhile even far exceeded the stability of titanium implants with the same diameter: The increase in stability was made possible by ceramic structure improvements as well as the intelligent shape of the SDS implant, where the connection is located in the area of the upper, wide part of the implant—the abutment (or tulip) (Fig. 14)—, and therefore does not weaken the thread portion of the implant, which is again made of solid zirconia (Fig. 14). In addition, the microthread of the load-bearing area further increases stability, providing the 3.8 mm implant with a core diameter of 3.72 mm. This is otherwise only possible with implants with diameters of around 4.5 mm. An increasing number of scientific publications available on PubMed corroborate the successful placement of zirconia implants. In summary, the study by Apratim et al. from 2015 states: “Literature search showed that some of



Figure 14: “Tulip”

the properties of zirconia seem to be suitable for making an ideal dental implant, such as biocompatibility, osseointegration, favorable soft tissue response and esthetics due to light transmission and its color.”⁽⁶¹⁾ A recent study by Giulini et al. also showed excellent results and a remarkable implant survival rate of 100% 7.8 years after insertion⁽⁶⁰⁾.

Immediate implant placement

Replacing a diseased tooth in a single session with a ceramic implant and an immediate temporary crown constitutes a unique opportunity and a technique that should be applied whenever possible. It is difficult to understand why an extraction wound, which usually involves a large loss of bone and gingiva, should first be left to heal, making it necessary to then first augment the lost bone before implant placement is even possible. In addition, osteogenetic activity is highest immediately after extraction, comes to a complete standstill after a few months and needs to be reactivated again. Since the tooth socket (the extraction alveolus) of the removed tooth will be filled with new bone anyway—as the stem cells contained in the blood know exactly where to form bone and gingiva—it makes a great deal of sense to place the implant at exactly this particular point in time, so that the new bone will automatically grow around it. Titanium implants by way of chronic inflammation by releasing TNF- α und IL-1 β —similar to the way a foreign body in the skin is encapsulated by connective tissue (bone is a special type of connective tissue). Therefore, immediate implantation with titanium implants is usually very risky and can lead to severe infections with enormous bone loss. Since zirconia—an oxidized and thus completely inert material—does not have any free electrons, no infections will occur if THE SWISS BIOHEALTH CONCEPT is observed. In the worst case, the implant will not integrate

with the bone (osseointegrate), but no bone will be lost. In most cases involving impaired osseointegration, the extremely aggressive thread in the lower section (only present in SDS implants) makes it possible to retighten the implant. In all probability, this procedure will be successful once 35 Ncm is reached again. The following basic rule applies: Generally speaking, success rates of between 92 and 99% can be expected if the SCC principle is meticulously adhered to, depending of course on how consistently the protocol is applied and how well a patient cooperates. This was proven by a study conducted by Dr. Volz in cooperation with Prof. Dr. Ralf Smeets and doctoral student cand. med. dent. Leon Neuhöffer at Hamburg-Eppendorf University. This prospective immediate ceramic implant study was the biggest of its kind and involved 112 immediate implants using one-piece implants which, in nearly all cases, were immediately restored with long-term temporaries (material: Luxatemp®) and firmly cemented (Durelon™)⁽⁶¹⁾. The resulting bone loss amounted to only 0.7 mm on average, which corresponds to the average bone loss associated with a late implant, i.e. the placement of an implant in “healed bone”, where 1 to 10 mm of bone have already been lost. The “Pink Esthetic Score”(PES) achieved a value of 12.3 out of a maximum possible 14 points, which, in most cases, resulted in an increase in gum tissue⁽⁶¹⁾ (Fig. 15 and 16). Sick teeth can cause severe chronic diseases—but until now, removing these teeth took a heavy toll, resulting in loss of bone and gingiva, esthetics, comfort, time, money and ability to socialize. Thanks to their unique Dynamic Thread® design, SDS-Swiss Dental Solutions’ one-piece ceramic implants are suited for immediate replacement of extracted teeth—even in the posterior teeth region—in

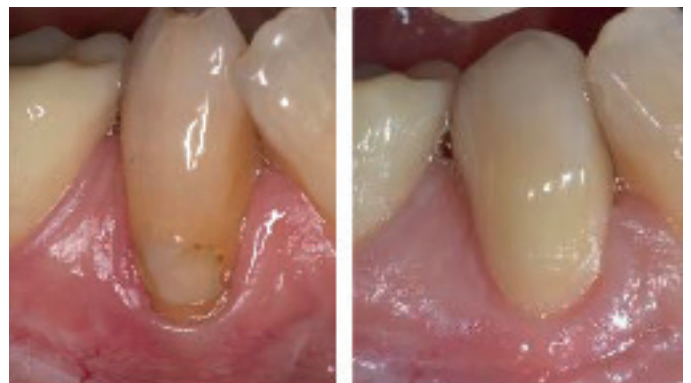

Figure 15: Left-hand side: the diseased tooth to be removed, right-hand side: the final crown on the SDS immediate implant with significantly better, healthier and more voluminous gingiva

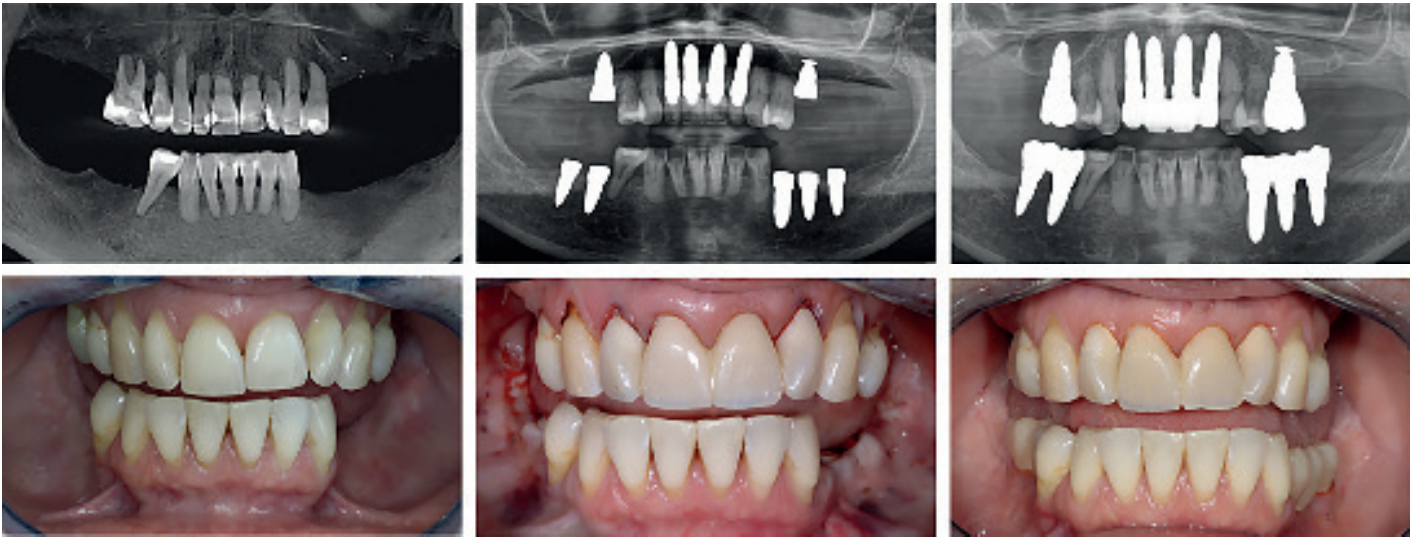


Figure 16: Upper left: The four anterior teeth with resorbed (dissolved) roots, which were replaced with SDS immediate implants and restored with final ceramic crowns (upper row). Bottom left: The clinical starting point with exposed tooth necks on the lateral incisors. Middle: The long-term temporaries on the day of implantation, with the temporaries ending at the “target gingival level”. Bottom right: More than 1 mm of gingiva has grown up to the edge of the long-term temporaries. The SCC Shortcut Concept has clearly resulted in a significantly healthier and more esthetic outcome than the initial situation.

almost all cases. A temporary restoration with fixed and esthetic plastic crowns is always possible, at least in the visible area. As a result, patients will usually receive fixed and esthetic teeth on the same day and can resume their normal social activities. Nevertheless, we recommend a postsurgical resting period of 3-4 days to provide the immune system with the energy required for healing (“My BIOHEALTH Week”). A smart integration of basic immunological principles according to the BTP Biological Treatment Protocol within THE SWISS BIOHEALTH CONCEPT will allow for an activation of the immune system and an acceleration of wound and bone healing and ensure that patients not only suffer neither pain nor swelling, but also look and feel better as early as the first postoperative day. By contrast, the usual tooth removal sequence, three to four months healing, 3D X-ray, possibly bone augmentation (= additional five months lost), covering the implant site with a removable temporary denture and a fixed crown restoration after another two to six months—would be equivalent to taking a (an expensive) “detour”.

Even the slightest stimulation of the immediate implant by the tongue encourages tissue metabolism and activates the meridians running through the rows of teeth. This “principle of stable restlessness” is known from orthopedics and is another reason why it makes sense to

replace every tooth that has to be removed with an implant, because otherwise not only the “meridian would atrophy”, but bone and gingiva in the respective area would also degrade as a result of a reduction or complete cessation of metabolism in this area (immobilization osteoporosis). Dentists consider it normal to extract teeth and to then let these regions “heal”, which means nothing other than that letting the papilla, gingiva and surrounding bone collapse, thus irrevocably and significantly compromising the esthetic appearance. It is astonishing to see that this approach is still adopted—to the detriment of patients—as it neglects the principle of “physical integrity” resulting in patients having to accept massive losses in esthetics and bone volume frequently involving the necessity of later bone augmentation. Irreversible disadvantages of this type can only be prevented by placing immediate implants, whereby zirconia performs significantly better than titanium: It is not only neutral and biocompatible and therefore less susceptible to infections, but can be shaped in a more voluminous fashion in the upper section of the implant, the so-called tulip, which emerges from the gingiva. The surrounding gingiva will integrate with it, sealing the cavity and will in turn be supported and retain its volume by integrating with the ceramic implant. Immediate implant placement will result in the tooth socket healing faster and better than if no

implant was placed, and the implant will heal faster in the extraction socket because the extraction will trigger the system's "healing and bone formation" process. Therefore, immediate implant placement according to the SCC protocol is considered the best and most biological "socket preservation" method.

Delayed immediate implant placement

Immediate implant placement is not possible in all cases. If there is poor soft tissue and also in the case of severely inflamed teeth, delayed immediate implant placement should always be considered. During a period of six weeks following tooth extraction, there is still no risk of bone resorption. This approach has the great advantage, however, that more soft tissue can be generated⁽⁸²⁾. If the socket is filled or plugged following tooth extraction using plugs made of PRF matrices, a gingival gain can be observed after four to six weeks. If the implant is placed at this time, i.e. around six weeks post-surgery, this gingiva can be used as a soft tissue build-up around the implant. This is a major advantage, particularly in the anterior region.

Late implant placement

Late implantation differs from immediate implantation in that the bone has already "healed". The focus here is now placed on generating a healthy, widely attached gingiva during implant placement. An implant is only placed in a

"flapless" fashion if the attached gingiva is very wide and if there is a seam of at least 5 mm of attached gingiva around the implant after punching or after "flapless surgery". Otherwise, a so-called wave-shaped incision is made which follows the oral position of the implant tulip in the shape of a wave.

The attached gingiva thus obtained from the cervical area is shifted in a vestibular direction and supported by the high tulip of the SDS implant, ensuring the growth of a broad seam of attached gingiva after healing. Thanks to the drilling protocol for SDS implants in conjunction with the "Dynamic Thread" developed by Dr. Volz, implants will—for the first time— have the same primary stability (max. 35 Ncm insertion torque) in all bone classes. This is extremely important when it comes to ceramic implants, since one of the disadvantages of ceramics is that they do not dissipate the frictional heat generated when the implant is screwed in, and because there is a risk of bone overheating and denaturation when the implant is screwed into hard class I bone⁽⁸³⁾. This is particularly relevant when it comes to cortical bone, which has poor blood supply and can therefore die and resorb very quickly when compressed. For this reason, 0 Ncm is the optimum torque to be applied in the cortical bone area. We virtually always achieve this torque when placing immediate implants through the alveolar gap and have therefore not observed any bone loss in that area (see the dissertation by Dr. Leon Neuhöffer⁽⁸⁴⁾). The drilling protocol provides for an extended drilling in hard bone, thereby creating cavities between the implant core and the bone, which, on the one hand, reduces friction and thus heating of the bone, and on the other hand, creates space for blood and growth factors (bioactive containers, stem cell niches, healing chambers). This triggers callus formation, resulting in the faster growth (10 to 50 μm per day) of much higher quality bone, namely vascularized lamellar bone^(85,86). If the implant is in contact with the bone (independent of the implant material), the bone will switch to poorly vascularized and slow (1 to 3 μm per day) appositional growth^(87,88). In soft class III and IV bone, the drilling protocol also always ensures an insertion torque of more than 35 Ncm, which means that these implants can usually also be immediately provided with long-term temporaries (Fig. 17) —a huge advantage for patients. However, when drilling in soft bone, it is always important to check whether there are grease drops floating on the blood. This would be a sign of an FDOJ, which must be completely removed Implantation (see p. 79) and then closed with the implant as if by a cork.



Figure 17: SDS SWISS DENTAL Solutions bone-class based implantation set

BONE AUGMENTATION MEASURES

Bone augmentation measures should always be performed in the most atraumatic, minimally invasive and tis-

sue-conserving fashion possible in order to avoid damaging the blood flow and losing esthetics. Even though bone augmentation measures can virtually always be avoided by means of immediate implant placement according to the SCC protocol, augmentation is often necessary in patients who have undergone alio loco extraction:

- Widening of the alveolar ridge: the “Angle Modulation Technique developed by Dr. Ernst Fuchs⁽⁸⁹⁾ is a method for a bone spread during which the gingiva is not folded down. Instead, the piezo technique is used to make vertical and sagittal bone incisions below the intact periosteum. After some gentle stretching and spreading of the gingiva, this technique will result in a so-called “greenstick fracture” leading to the release of growth factors and triggering callus formation. The void space between the implants must bleed in and must not be filled with bone replacement material, as this would disturb the extremely fast callus formation inside the “bio-active container” created. However, the void space can/should be filled with A-PRF membranes.
- Internal sinus lift: Here, drilling is only carried out to just below the cortical maxillary sinus floor which, using appropriate instruments, is then mobilized in a cranial direction together with the Schneiderian membrane situated above it. Since the flexibility and (one-dimensional) extensibility of the membrane amounts to about 132%⁽⁹⁰⁾, approximately 2.5 to 4.5 mm bone height can thus be gained⁽⁹¹⁾.
- Intralift™: If a large amount of bone is missing in the maxillary sinus area, this particularly gentle procedure can be used to build up bone easily and safely in some cases. A special set (SCA® = Sinus Crestal Approach) is used to open the bone all the way up to the mucosa of the maxillary sinus (Schneiderian membrane) without damaging it. We prefer our specially developed method—namely an internal lift using Summers osteotomes—which has the advantage that the Schneiderian membrane is additionally protected by a bone flap. The Acteon™ piezo method is then used to pump sterile Ringer’s solution via a “trumpet” and spread by means

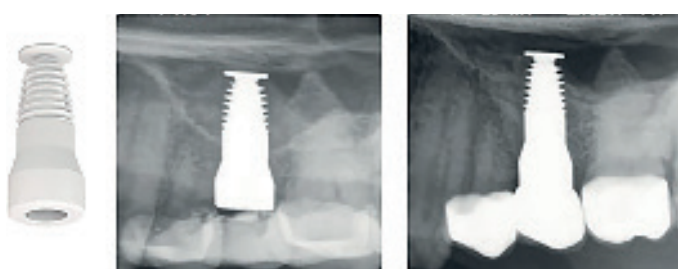


Figure 18: Sinus implant

of piezo vibrations, into the area between the maxillary sinus floor and the mucous membrane, resulting in its detachment. Now the A-PRF and the patient’s endogenous bone can be introduced into the newly created space via the small bore hole. Unfortunately, however, this method only works with U-shaped cross-sections of the maxillary sinus, since tension from the Schneiderian membrane must never be applied to the augmentation material and/or the bone. This would lead to expulsive forces being exerted and a potential loss of the augmentation material and/or the implant. This technique is also indicated if the Schneiderian membrane can only be removed with difficulty and is strongly attached to the sinus floor bone. This can be determined very easily beforehand, since this particular characteristic is always analogous to the condition of the gingiva: if it can be easily detached, the Schneiderian membrane will be easily detachable as well (and vice versa).

- External sinus lift: It will be always performed in the event of difficult or unsafe conditions in the maxillary sinus, as it enables a direct view of the area in question, making it the safest method. Here, the intervention area will be defined by means of a straight alveolar ridge and gingival margin incision running over the maxillary tuber without vertical relief, and a piezo saw used to cut a window. The void space is filled with a mixture of A-PRF membranes and autologous bone obtained by means of the safe Scraper™ prior to the window cutting. Additional bone may also be harvested during the FDOJ surgery in the adjacent wisdom tooth region, which is usually performed in a first surgical step. The bone should never be stored in a sterile saline solution prior to its use, as this will lead to bone cell destruction. It is better to store PRF membranes in exudate or patient blood. If at all possible, an implant should always be placed immediately according to the tent-pole principle in order to support the Schneiderian membrane cranially and prevent a collapse of the cavity⁽⁹²⁾. This can be optimally achieved with the sinus implant developed by Dr. Volz, which has a wide plate at its tip that will gently and securely support the mucosa and thus significantly reduce the risk of perforation (Fig. 18). In addition, this enables the creation of a larger void space, since the implant now not only acts as a tent pole, but also has a kind of umbrella at its tip. Hundreds of interventions of this type have demonstrated that this revolutionary implant design results in that healthy new callus being formed without having materials—whether of synthetic, human or animal origin—becoming necessary (Fig. 19 and 20). A new milestone in the field of biological dentistry has thus been reached: New, endogenous bone always performs best in terms of angiogenesis, i.e. the formation of new blood vessels. This is the main criterion for

determining whether bone quality and quantity will be preserved over the decades to come⁽⁹³⁾. Bone replacement material will in principle always represent an obstacle to new bone formation, as it reduces the size of the remaining void spaces and thus the possibility of vascularization. Apart from that, a loss of the implant would lead to a regression to the initial situation in the worst case. If secondary materials are used during implant placement and the implant is lost, the mucosa of the maxillary sinus tends to usually get irreversibly damaged and compromised for the rest of a patient's life.

Basic principles of wound healing

The physiological remodeling processes involved in tooth extraction: Immediately following extraction, the inflammation phase is initiated at a microscopic level. The aim of this phase is to activate the fibroblasts present in the tissue. These, in turn, respond by producing collagen (proliferation phase), meaning that the final phase of tissue formation can ultimately be initiated (regeneration phase). At a macroscopic level, extraction always goes hand in hand with atrophy of the soft tissue unless the socket is "held".

Soft tissue management

As technology progresses, knowledge of the biology of the human body is also constantly evolving—this also especially applies to the field of modern dentistry. However, conventional dentistry today is in part still based on scientific studies from 50 years ago—a time when biological processes and their interactions with our environment had not yet been adequately researched. Working in cooperative synergy, Prof. Dr. mult. Shahram Ghanaati and Dr. Karl Ulrich Volz are pursuing their vision of taking into account these original biological findings, while at the same time harmonizing them with the latest knowledge gleaned from decades of research and medical progress.

For example, atraumatic soft tissue management remains one of the most important fundamental factors in the success of a surgical procedure. It is undisputed within the dentistry profession that hard tissue follows the morphology of soft tissue and vice versa: Gum recession as a result of a traumatic brushing technique or incorrect eccentricity/occlusion directly leads to bone recession, while any bone loss in turn results in the collapse of soft tissue in this area. The original motivation to shield wounds in the maxillary region as tightly as possible from the outside oral cavity under all circumstances is now more questionable than ever according to the latest findings on wound healing and augmentation principles.

Bone metabolism and healing

In order to be able to understand the precise interactions between soft tissue, the patient's endogenous bone and the augmentation material, fundamental knowledge of bone metabolism is a further crucial factor. Once a tooth is lost or a periodontal problem emerges, the bone or socket in this area never fully regenerates. Tooth extraction, in particular, eliminates the source of the physiological metabolic process. Nevertheless, bone (which is not comparable to the surrounding, untouched bone) forms in places where it was never intended by nature—in the dental socket. The principles of fracture healing can only be applied to dental trauma in connection with a fractured alveolar process. The preservation of the periosteum should be the objective of any oral surgical procedure, as this optimally promotes bone healing. This can be ensured with the help of atraumatic incision and the specific healing technique.

Bone Growing Implants

This term refers to a new type of implants, developed by Dr. Volz in 2016, which make optimal use of the principles of biology and enable bone to grow both in height and width, without the need for artificial or animal bone. The use of these implants makes it possible to reduce costs significantly, since they not only render additional procedures unnecessary, but also allow for cost savings when it comes to bone replacement material, screws, plates, bone blocks and membranes. In addition to the sinus implant described above, whose wide plate at the tip creates a large and stable void space in the maxillary sinus that subsequently fills with blood clot—the precursor of bone—there are other bone-forming shapes. They always make use of the tent pole principle to keep the periosteum or the Schneiderian membrane at distance, thus creating a mechanically stable cavity which will reliably fill with bone due to the osteoinductive (bone-forming) potency of the periosteum and the Schneiderian membrane^(92,95-96).

- Balcony implant: An implant with a balcony-like bulge in its tulip area that also keeps the tissue at a distance in the gingival area, seals the socket and enables new bone growth (Fig. 21).
- Oval implants: these implants are based on the same principle as balcony implants—with the difference that they have a balcony-shape on each side (Fig. 22).
- Short implants: Another variant that utilizes the principle of void spaces (bioactive containers, stem cell niches). The rectangular notches of these short implants increase the contact surface and both quantity and quality of newly formed bone on the implant body (Fig. 23).
- Disc umbrella: Based on experience with the above-mentioned Bone Growing Implants, Dr. Karl Volz—together with Prof. Dr. Alain Simonpieri (developer of the brush-

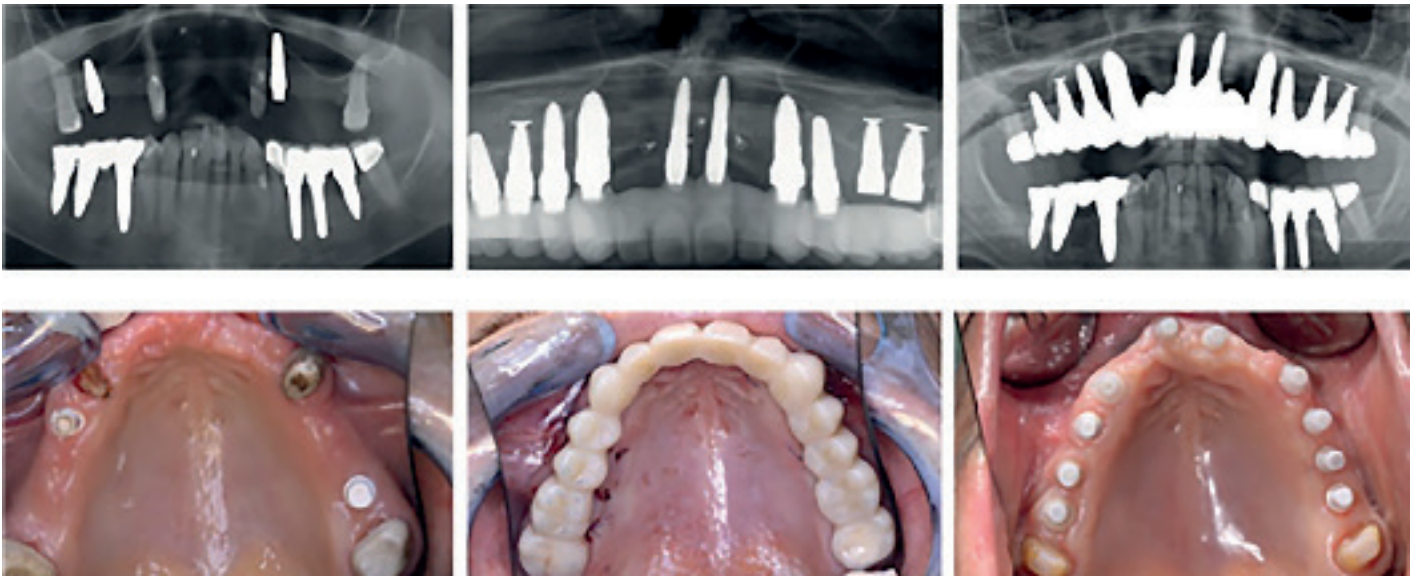


Figure 19: Complete restoration of the upper jaw with insertion of three sinus implants. Left-hand side: pre-op, middle: post-op after LTT placement, right-hand side: final restoration (top) and healed implants (bottom)

ing technique) and Prof. Joseph Choukroun (developer of the PRF technique)— designed a so-called “disk umbrella”, which utilizes the parasol effect in a very smart way (Fig. 24).

The Bone management criteria formulated by Prof. Choukroun in 2016 and 2017 and later expanded by Dr. Volz form the basis for all bone augmentation measures and, in particular, for Bone Growing Implants:

BONE MANAGEMENT CRITERIA

Systemic conditions

- A strong immune system: The immune system can be strengthened by taking supplements such as vitamin D3, K2/mk7 and C, magnesium, zinc, Omega-3 fatty acids, by following an optimized, sugarreduced alkaline diet and by abstaining from harmful habits such as smoking, heavy drinking and excessive use of mobile phones, while reducing EMF exposure in general.
- The ability to form strong bones: Again, this is achieved by taking the above supplements.
- Activation of the parasympathetic nervous system and inhibition of the sympathetic nervous system: This is achieved by taking vitamin D, which has an anti-depressant effect and thus relaxes and brightens the mood, and by an alkaline diet, alkaline baths and infusions. In addition, patients should refrain from working for at least one day prior to and at least 4 days after surgery, reduce microwave radiation (EMF) and receive Procaine as part of their IV infusion during each check-up appointment.

Local conditions

- Reduced bad inflammation (associated with multinuclear giant cells): This reduction is achieved by IV administration of cortisone and antibiotics and by taking vitamins D3 and C.
- Activated good inflammation: this is achieved by means of the leukocytes contained in A-PRF and by means of atraumatic, minimally invasive, but radically clean surgical interventions.
- Reduced contamination by breath and saliva: this is done by mixing metronidazole to the augmentation material or the PRF matrix.
- Stimulated bone and activated bleeding by bone “refreshing”: The oversized preparation prescribed by the biological SDS drilling protocol enables the growth of stem cells and the creation of bioactive containers and healing chambers. The same effect is achieved in the area of the cortical bone by reducing it in terms of volume, i.e. by preparing the socket in an oversized fashion.
- The extracellular matrix will improve as a result of traction relief achieved by using apical mattress sutures, as well as by the creation of cavities under the periosteum and Schneiderian membrane, and by leaving the sutures in place for 3–6 weeks (monofilaments: Atramat®). Spacers can be placed by means of screws, plates, the Choukroun Fast System or the BISS Bilateral Implant Stabilization System developed by Dr. Volz, or in an automated way by using bone growing implants with the wide SDS Tulip, the sinus implant or the disk umbrel-

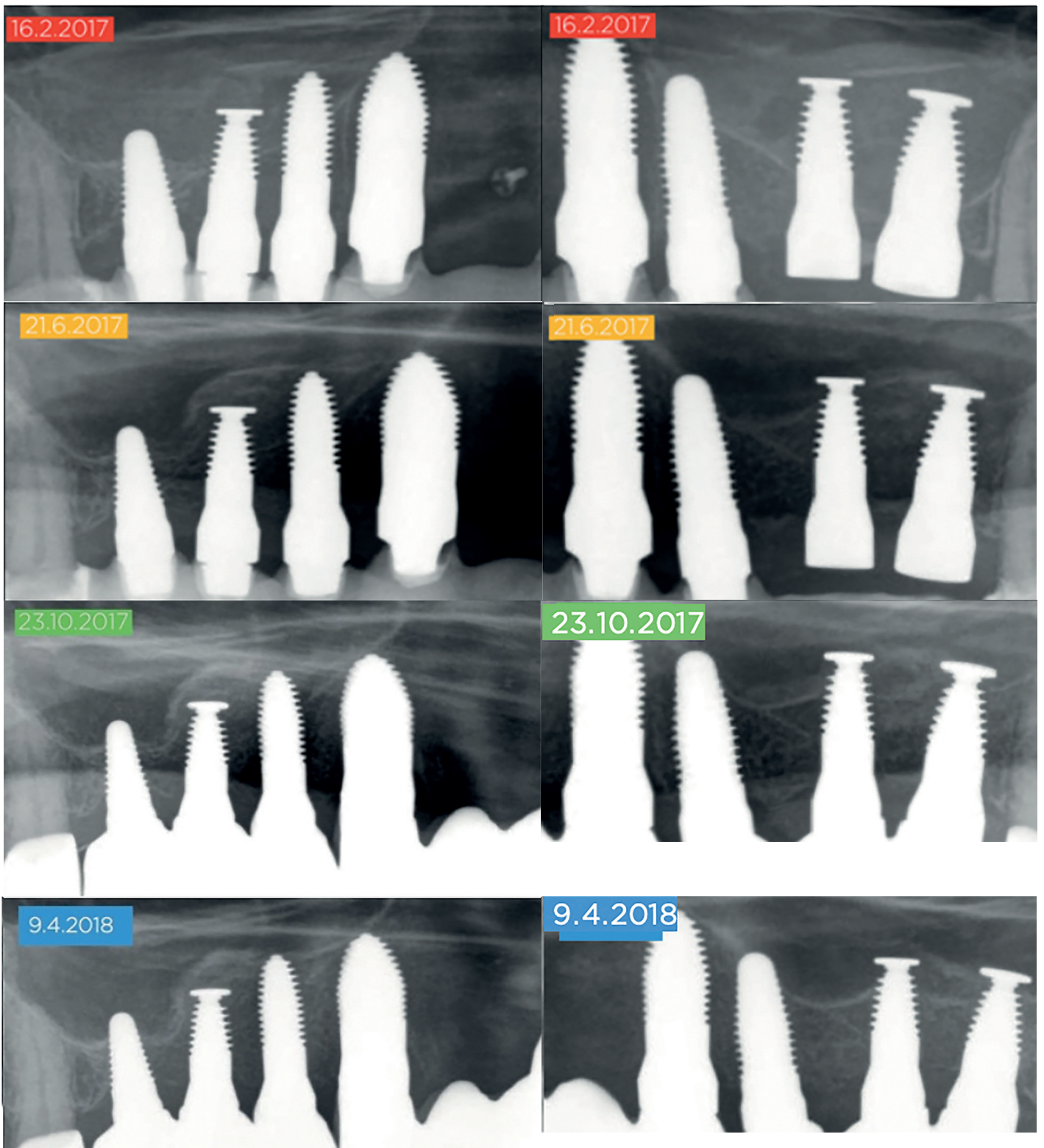


Figure 20: Significant bone gain after external sinus lift and insertion of (sinus) implants in the first quadrant (left column) and in the second quadrant (right column).

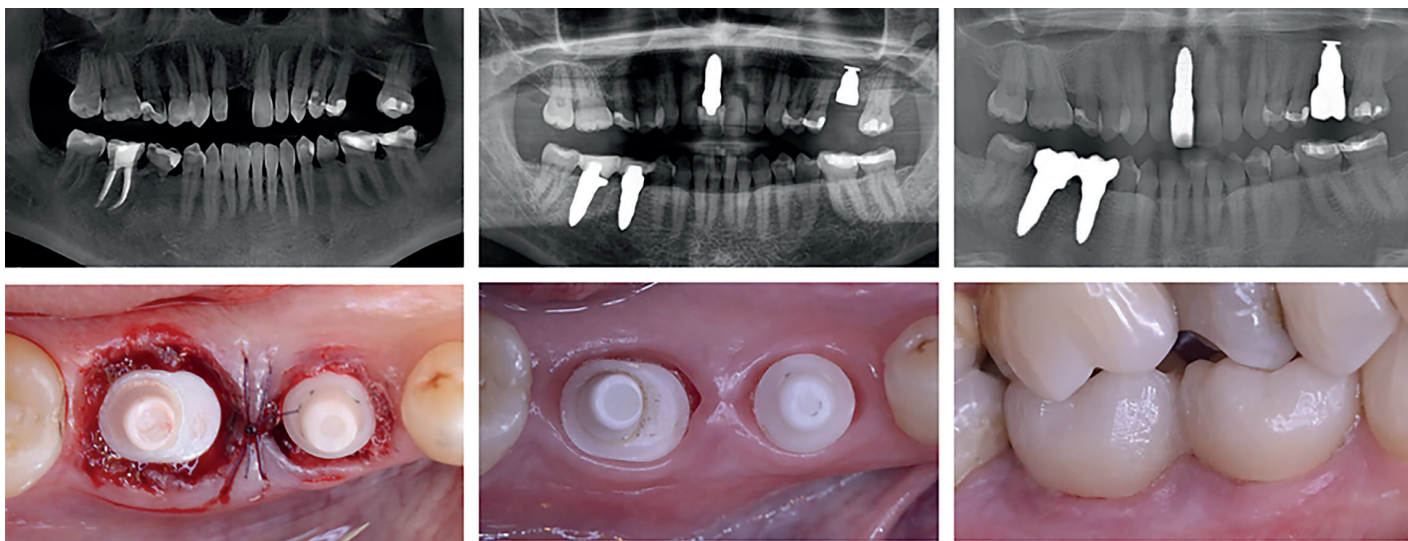


Figure 21: SDS SWISS DENTAL SOLUTIONS balcony implants

las, etc.

- Preservation of blood flow: If blood flow is to be preserved (Mammoto's Law)⁹³⁾ the cortical bone must not be compressed in any way, since this bone—which has poor blood flow by nature—would be additionally compromised.

The aforementioned bone management protocol represents the Holy Grail of biological dentistry, so to speak, since all measures serve only one purpose: to build up healthy and well vascularized endogenous bone and keep it healthy for life! This can be done mechanically by means of SDS implants in general and bone-growing implants in particular. From a bio-immunological point of view, all preparatory, accompanying and follow-up surgical intervention measures described here in THE SWISS BIO-HEALTH CONCEPT serve this one purpose. Therefore, all

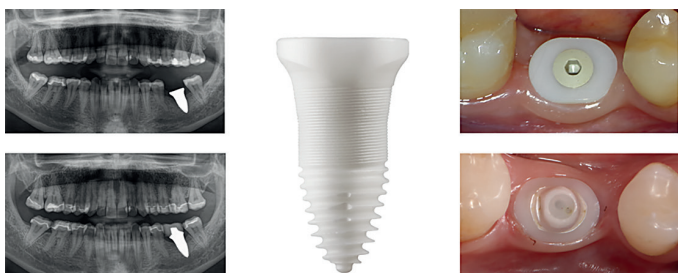

Figure 22: SDS SWISS DENTAL SOLUTIONS oval implants

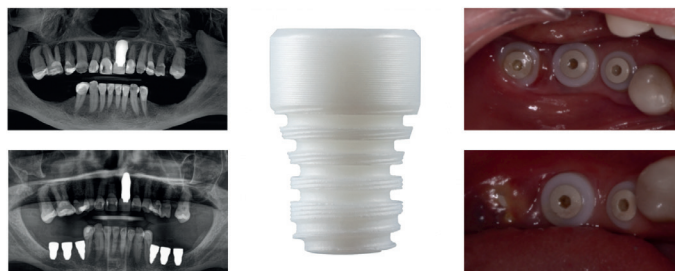

Figure 23: SDS SWISS DENTAL SOLUTIONS short implants

the minute pieces making up the mosaic of this concept have a deeper meaning and should never be ignored or, worse, disregarded!

SPECIAL TECHNIQUES AND ASPECTS

Brushing technique

In order to avoid slitting the periosteum, which entails a destruction of many blood vessels and damaging of meridians as a result of the long and deep horizontal slit, it is essential to use the “brushing technique” developed by Prof. Alain Simonpieri. Its purpose is to stretch the gingiva during bone augmentation measures. During this procedure, the intrinsically rigid periosteum is brushed with the various tools contained in the “brushing kit”, leading to a vertical separation of fibers without blood vessels being destroyed or meridians damaged. This

technique is based on the finding that the periosteum, which was originally thought to be non-elastic, consists of millions of rubber fibers which are vertically bonded together and which are separated from each other during the brushing process. After a few minutes of brushing, the initially rigid gingiva can be stretched by up to 1.5 cm. Since no blood vessels or meridians are damaged, the patients will experience no pain or swelling. Prof. Simonpieri has been personally teaching this revolutionary technique in workshops held at the SWISS BIOHEALTH EDUCATION CENTER since 2018.

Apical mattress suture

The apical mattress suture (Fig. 25) was further perfected by Simonpieri and Choukroun, and represents an extremely simple and safe technique to generate keratinized “attached gingiva” purely by using a special suture technique in combination with the brushing technique and A-PRF membranes, without a so-called “free mucosa transplantation” being performed. Always starting at the facial aspect, a resorbable suture (preferably Atramat®) is placed by inserting the needle deeply through the periosteum on the facial side and along the bone in an oral direction. From there, to prevent the suture from tearing, the needle is inserted again in a facial direction at a distance of 2–3 mm in order to exit the gingiva 2–3 mm from the insertion site. The suture is now tightened with a slow

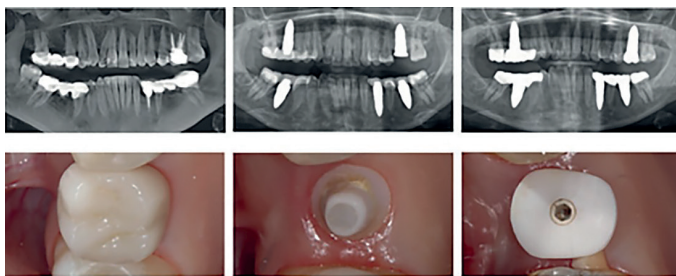


Figure 24: SDS SDS SWISS DENTAL SOLUTIONS disc umbrella

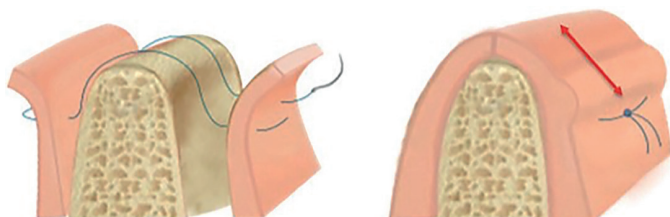

Figure 25: Apical mattress suture

and even pull to prevent the suture or gingiva from tearing. This pulls the periosteum towards the bone at the level of the puncture site and removes any traction from the incision area. As a result, keratinized “attached” gingiva will develop between this point and the incision area. This technique must be used for all sutures to avoid traction on the incision area and thus the risk of dehiscence with subsequent infection. For this reason, the surgeon must exert a strong pull on the lip in the intervention area at the end of each intervention in order to ensure that no traction is transferred from the lip or “free gingiva” onto the incision area. This technique is also suitable for treating dehiscences on natural teeth in a fast, simple and safe fashion by first detaching the gingiva with a gingival margin incision and then flapping it open in an apical direction as a “full flap”. The periosteum brushing technique is then used to stretch the periosteum, which is subsequently lined with several layers of A-PRF to introduce growth factors and stem cells into this area. In a next step, an “apical mattress suture” is applied in each interdental space and the gingiva is closed with traction-free single button sutures or so-called esthetic sutures as used by Dr. Volz.

Bone replacement

Allogeneic and autologous bone: Generally speaking, preference should always be given to autologous bone for biological, forensic and economic reasons. Autologous bone has the greatest potential to become the patient’s own living bone and has the lowest level of risk in terms of infection or rejection. There are a number of methods for collecting or extracting bone. Numerous possibilities for obtaining autologous bone are available. However, its available quantity may be too small in the case of significant defects (e.g. following an extraction involving a very large cyst, infection or FDOJ, in the absence of a vestibular lamella or in the event of extremely thin bone in the sinus region of less than 2 mm). After informing the patient accordingly in advance, the autologous bone, which represents the gold standard, can be stretched with allogeneic bone. The advantage of this allogeneic, i.e. human, donor bone is that it is very similar to autologous bone and exhibits practically the same properties as the patient’s own bone—with the sole disadvantage that it does not come from the patient themselves. There are various products available on the market, which vary from country to country. What’s more, in Germany, for example, they may only be distributed to companies with a pharmacy license. This bone is obtained from femoral heads removed and replaced with implants during hip joint surgeries. It is therefore not cadaver bone, but rather bone from living donors. This bone is processed into granules, completely demineralized and cleaned of all organic matter, meaning there is no risk of infection.

The safety of this bone is also guaranteed by blood tests carried out on the donors for all conceivable diseases. Every medium or medium-rare steak, every blood bag and every handshake carries a risk of infection that is a million times higher. This material can actually form new and living bone. Augmentation and BRM: The success of an augmentation procedure comes down to the both the body's immunological reaction to the material and the mechanical force. The aim of every augmentation procedure should be to ensure that the inserted BRM is not recognized by the immune system as a foreign body. Focus should not be placed on the product, but rather on the technique used to achieve this goal depending on the indication (indication-based dentistry). This is primarily based on existing residual bone. Bone chips or granules offer an ideal option for bone augmentation in the case of smaller bone defects and should ideally be combined with collagen membranes. In the case of larger defects, however, they do not have sufficient volume stability. In such instances, a basic framework has to serve as a placeholder in the sense of the tent pole umbrella principle (bone blocks using the Khoury technique, umbrella screws or the BISS). In any technique, the biologization of the BRM and membranes used (see the corresponding studies by Prof. Ghanaati) is a measure that is vital for successful bone augmentation. The biologization can be implemented perfectly within THE SWISS BIOHEALTH CONCEPT with the help of the LSCC protocol.

The dome technique

The "Dome technique" developed by Simonpieri and Choukroun in 2018 is another promising new technique which consists of introducing a flattened and folded equine collagen sponge into the maxillary sinus in such a way that the rather stable structure ends up creating a "dome". First results show that within a few weeks, a stable bone layer starts growing along this collagen membrane, thus shaping and maintaining a cavity in the maxillary sinus.

Open Healing Protocol according to Prof. Ghanaati

The OPEN HEALING PROTOCOL developed by Prof. Ghanaati provides a solution that allows for successful, tension-free wound healing and bone augmentation by protecting the augmentation material against resorption and the soft tissue against dehiscence by using a placeholder such as is the case with the BISS.

BISS - Bone Implant Stabilization System

By mid-2020, an entirely new and unprecedented system closed the last gap and enabled one-session implant placement even in the most hopeless situations. The so-called BISS—the bone implant stabilization system developed by Dr. Volz in November 2018 enables the safe

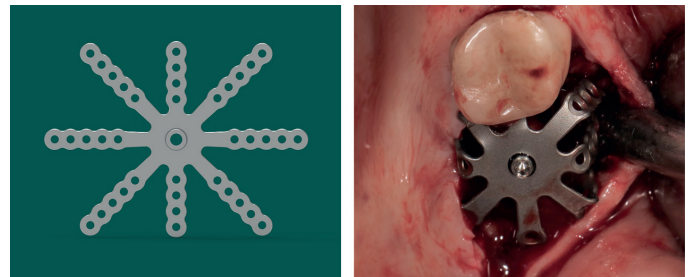


Figure 26: Single cage for volume and bone augmentation. SDS ceramic implants or umbrella screws can be stabilized via the central opening.

stabilization of any conventional SDS implant in any defect, no matter how great, promoting the integration of new bone with the implant according to the "Tent pole umbrella principle". The first 20 pilot surgeries in 2019 were exceedingly successful and promising in terms of this system's broad and reliable applicability. Additional treatments were carried out successfully until the end of 2021. Figures 26 and 27 illustrate the use of a single cage to stabilize an SDS implant.

AIM (Anatomical Implantation Method)

Based on the work of Prof. Simonpieri, the anatomical implantation method has developed to become a helpful




Figure 27: AIM tray.

technique for the positioning of implants. Prof. Simonpieri found that the canalis incisivus runs absolutely parallel to the axis of the maxillary implants and the distance between the implants in the esthetic zone is 7 mm. Furthermore, the two upper anterior implants are between 5 mm and 7 mm from the canalis incisivus. Working on the basis of this knowledge, special tools have been developed that take these values into account and place the implants in a perfectly aligned position.

RAP (rebuild aesthetics procedure)

The RAP was developed on the basis of valuable ideas from Prof. Simonpieri. As part of an ALL-IN-ONE operation, it allows for the esthetics to be optimally restored. Certain modifications were made and new tools or products were developed to this end. In order to gain comprehensive in-depth knowledge in the field of bone augmentation, the Bone Augmentation Week is held at the Swiss Biohealth Education on an annual basis. It provides information on all theoretical aspects of the various bone augmentation materials directly in combination with practical exercises on the model. Further information and details on the registration procedures can be found at www.swissdentalsolutions.com/education/bone-augmentation.



Clinical application of the RAP – REBUILD AESTHETICS PROCEDURE

FINAL PROSTHETIC RESTORATION

The final restoration will of course always be made with zirconia ceramic and will be preceded by a temporomandibular joint analysis and, possibly, gnathological therapy. It is of the utmost importance to compensate for any previous loss of bite height. Any loss of bite height (and reduced jaw movements/masticatory muscle activity) will reduce cerebral blood flow^(99,100) as well as venous outflow which is immensely important for detoxification. 1 mm loss of bite height results in 50% less cerebral blood flow.

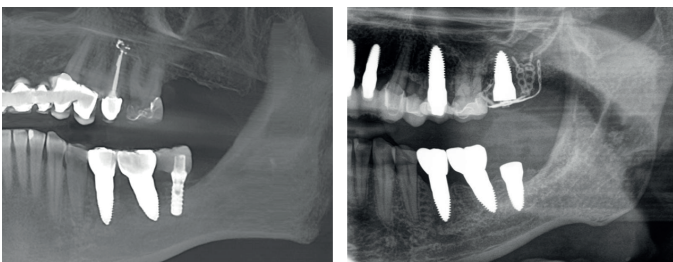


Figure 28: Stabilization of an SDS ceramic implant with a single cage in region 27.

This is due to the fact that a loss of bite height always leads to a compression of the temporomandibular joint which is located in direct proximity to the large vessels and “pinches” them off. This is not a pathology, but a principle intended by evolution: Once a human being has fulfilled its reproductive role, it must age and die as quickly as possible so that it does not unnecessarily burden the ecosystem. Of course we have come to reject this principle, opting instead for anti-aging measures of all kinds and striving for longevity, because we would like to live as long as possible, maintaining our health and quality of life to the greatest extent possible. II- and III-surface defects should be treated with ceramic inlays, for example based on the CEREC procedure, which has the advantage of allowing the restoration of defects in one session directly after old fillings or caries have been removed. This does not only mean that the patient does not have to come back for follow-up appointments, but reduces the risk of loss of temporaries, dental cusp fracture and pulp infection. Crowns and bridges are restored with zirconia and fixed with glass ionomer cement (Ketac™)—a fully biocompatible material. Any excess material can be easily and reliably removed en bloc during the curing phase. A newer approach involves making sure that the surfaces which are in contact with the papilla are made of pure zirconia and neither polishing nor overlaying them, but rather irradiating them with 20–50 µm of corundum at 1.2 bar. Gingival tissue will attach to it in the same way as it attaches to the implant margin and become perfectly stabilized, which leads to an even better result in the long term. However, patients should then no longer destroy this bond by flossing their teeth. The rapid development of so-called monolithic zirconia restorations with entire crowns made of colored zirconia is facilitating this approach. During the impression stage, no retraction cords should be inserted under any circumstances, since they—as their name suggests—will lead to retraction, i.e. loss of gingiva. This outdated technique dates back to the last millennium and was used with teeth and implants ground by means of tangential preparation. The retraction cord destroys the bond between the tooth or implant and the gingiva during insertion and is only used to take an impression of subgingival preparations. Subgingival preparations, in turn, are used to compensate for the retraction caused by the retraction cord. The retraction cord is therefore the solution to a problem caused by the retraction cord. If the retraction cord is simply omitted, as Dr. Volz has been putting forward for many years, no retraction will occur and preparations can be made at gingival level (equigingivally) without any risk whatsoever. This means that impressions can be taken safely and easily without using a cord, creating perfectly shaped restorations (Fig. 29). Prior to preparing the ceramic implants, it has proven useful to remove excess gingiva in an ovoid

shape with a coarse diamond. This goes back to Erni Fuchs, who succeeded in proving that even stem cells are released in the process. Furthermore, it is also possible to remove scars and lip frenula simply and without any complications. It is recommended to finally run a red ring diamond over any scars and to treat them with two drops of an astringent. Lip frenula can be ground away with the diamond and left to free epithelialization. The benefits include that the patients do not complain of any pain and it is a quick process overall. In our clinic, we prefer this approach to the use of a laser. Zirconia implants are placed as described in the prosthodontics manual (<https://www.swissdentalsolutions.com/downloads>), taking account of the following important principles: Reduced occlusal contacts need to be created, since implants, unlike natural teeth, are not suspended in a fibrous apparatus and therefore do not give way under load. If crowns and bridges on implants had the same strong occlusal contact as natural teeth, they would be subjected to much greater loading. This can be examined very easily: The occlusion foil—which has a thickness of approximately 10 μm —should only get stuck when the patients bites firmly, but not when there is only light contact in the area of implant crowns. For the same reason, implants are never splinted with natural teeth, because this would restrict their natural range of movement. Instead, they are always splinted with other implants, since fractures are only known to occur on single-tooth implants. Splints must never be placed across symphyses, as this might result in the patient suffering from tension, headaches and migraines. The symphyses (lines of junction) are located in the median line of the mandible and in the area of the maxillary canines. This is why large, splinted maxillary implants are separated by the median line. In the mandible, they are made up of an anterior segment and two posterior segments. Therefore, 8 implants (“Great on Eight”, Fig. 29) will always be required for the restoration of an entire jaw, preventing a blocking of the symphyses and, at the same time, activating all meridians. A restoration using PEEK—an elastic material—is only indicated if a splinting of the symphyses cannot be prevented as a result of the number of implants and position of the implants required. We do, in principle, recommend that all materials remaining permanently in the patient be tested in advance with the ART technique developed by Dr. Klinghardt.

DENTAL HYGIENE

Once the restoration has been completed, patients are advised to only brush their teeth, ceramic crowns and ceramic implants with a soft toothbrush, using healthy, fluoride-free toothpaste. Under no circumstances should they use dental sticks, interdental brushes, oral irrigators, superfloss or normal dental floss, as these destroy the

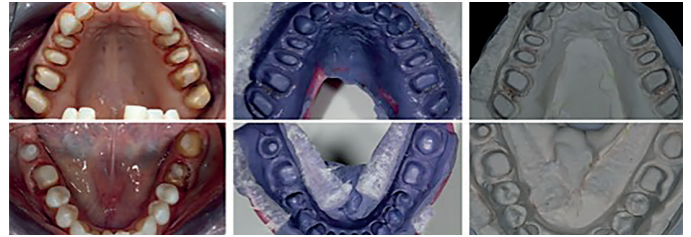

Figure 29: Preparations, impressions and plaster model production

firm bond between the zirconia ceramic of the crown or implant and the gingiva. This theory, postulated by Dr. Volz many years ago, was confirmed when the American Dental Association withdrew its recommendation of dental floss in October 2017⁽⁹⁸⁾! In addition, we recommend the so-called “oil-pulling” advanced by Dr. Karach, preferably with virgin coconut oil in the morning before brushing the teeth. Furthermore, it is extremely important to keep all micronutrients at a high level by regularly taking BASELINE and BOOST, increasing the amounts in times of stress, as gingivitis is always a symptom of micronutrient deficiency⁽⁹⁹⁾ and not of inadequate dental hygiene. It goes without saying that dental hygienists or prophylaxis assistants must only remove and polish superficial concretions and plaque when performing regular professional dental cleaning. Under no circumstances should scalers and curettes be introduced under the gingiva, as they would destroy the firm bond created. It is much more effective to measure 25-OH vitamin D3 levels (storage vitamin D3 in the blood) instead of determining the SBI (sulcus bleeding index) or the PI (plaque index). This can be done with the vitamin D3 chairside test which makes it possible to determine vitamin D3 levels in just 15 minutes. The results will however not be as accurate as a regular laboratory test.

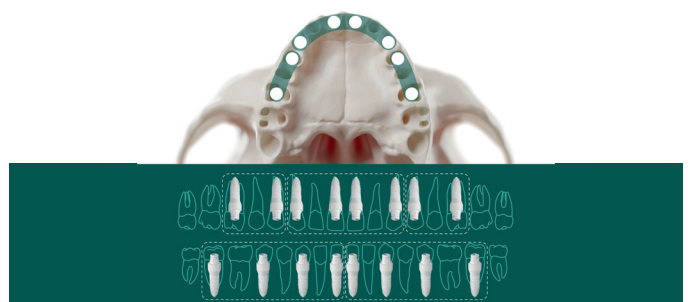


Figure 30: “Great on Eight”: 8 implants will always be required for optimal restoration and activation of all meridians.

Scientific substantiation of THE SWISS BIOHEALTH CONCEPT

A prospective pilot study completed in spring 2020 to scientifically substantiate THE SWISS BIOHEALTH CONCEPT produced some remarkable findings. As explained in this brochure, THE SWISS BIOHEALTH CONCEPT is a comprehensive concept aimed at removing interference fields in the oral cavity followed by immediate restoration with zirconia implants in the sense of the ALL IN ONE CONCEPT (Fig.1). The dental measures are part of a set of carefully matched medical measures to improve immunocompetence and ensure the optimal healing of bone and soft tissue. The pilot study included SWISS BIOHEALTH CLINIC patients with at least one root-treated tooth and possibly further interference fields such as, for example, osteonecrosis of the jaw (FDOJ) and/or metal loads such as amalgam. In addition, they had to present physical complaints, which were quantified on the basis of the Medical Symptoms Questionnaire (MSQ). This questionnaire was developed to record the main symptoms in all of a organ areas of a patient's body's. The change in MSQ total score comparing preoperative and postoperative results was used as main test parameter. The pilot study comprised a prospective and a retrospective group. All patients in the first group who had been treated at the clinic between October 8, 2019, and February 2, 2020, and met the inclusion criteria were evaluated. Evaluation was carried out at two time points—immediately before surgery and a few days after the surgical procedure. 19 of the total of 20 patients registered were evaluated. Despite the small number of cases, the result of $p < 0.001$ was extremely remarkable in statistical terms (Fig.2). This proves the significant improvement of the patients' complaints—a fact documented by countless testimonials in the past.

The result was verified by evaluating a second retrospective group, which included patients whose MSQ was

checked up to one year after surgery. The result of around $p < 0.004$ confirmed system improvement stability beyond the immediate postoperative time point in an impressive manner. This is one of the few prospective studies—possibly the first of its kind—conducted in the field of interference field research. It has provided the first scientific confirmation of the improvement of symptoms observed in many individual cases, especially of chronic diseases, through treatment according to THE SWISS BIOHEALTH CONCEPT. Encouraging results were yielded by further test criteria with regard to telomere length and mitochondrial function. Telomeres are biomarkers of aging, and their shortening is associated with chronic diseases. In the patient shown above, laboratory results showed telomere lengthening as early as four weeks after surgery, which corresponds to a reduction in biological age (Fig. 3). Mitochondria are of central importance for the vitality of an organism, mitochondrial diagnostics constituting an early warning system regarding the derailment of bioenergetic processes. Individual patients also started showing significant improvement just a few days after surgery (Fig.4). Overall, however, the values in this small group were insufficient for statistical evaluation.

This study has provided the first proof that THE SWISS BIOHEALTH CONCEPT can make a significant contribution to the treatment of chronic diseases by removing chronic interference fields in the oral cavity. The treatment helps to strengthen the immune system, making the organism more vital, resistant and capable of regeneration. The challenges posed by increasing environmental pollution and the global spread of pathogens make it essential to strengthen one's own defenses and remediate interference fields. This is of particular importance in view of the COVID-19 pandemic.

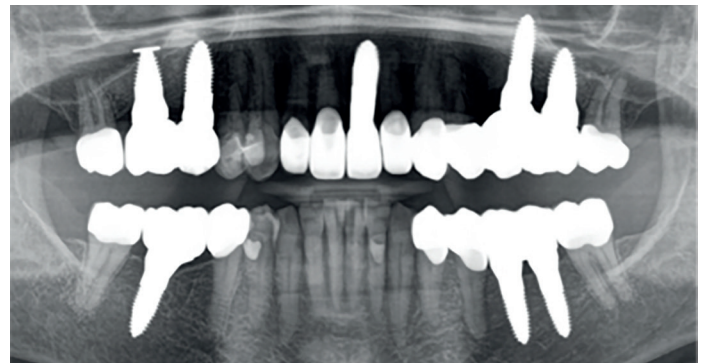
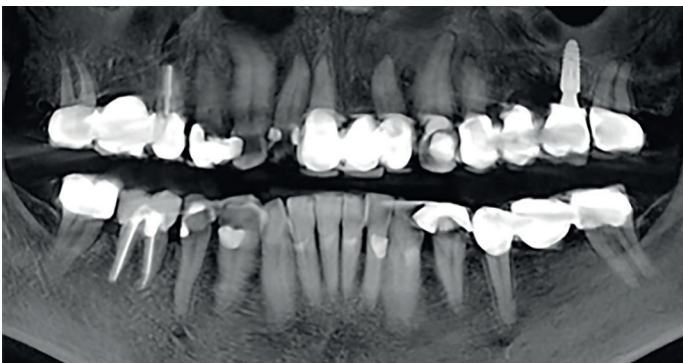


Figure 1: OPG before (left) and after surgery (right) aimed at restoring interference fields based on the ALL IN ONE CONCEPT.

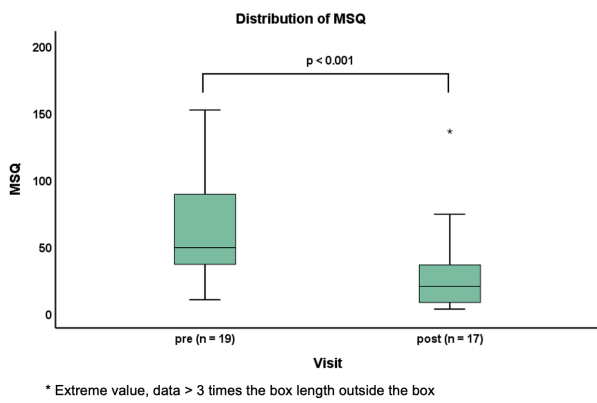


Figure 1 Distribution of MSQ
p-value of Wilcoxon test for paired samples (n = 17)

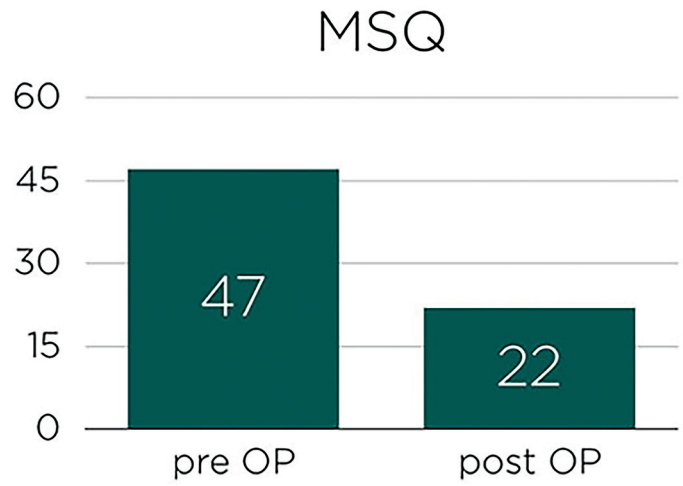
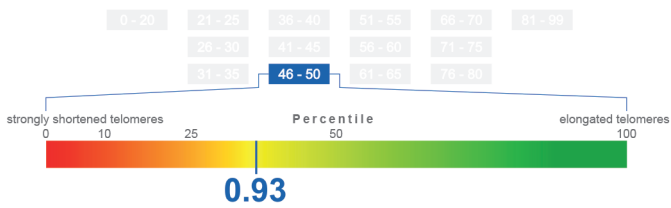
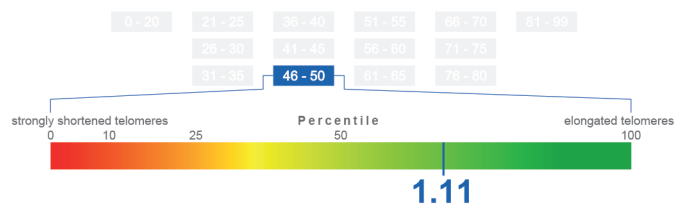


Figure 2: The MSQ evaluation for the prospective group shows a statistically significant improvement of the MSQ after removal of all interference fields (left-hand side). The example of an MSQ evaluation shows an improvement in the patient's general symptoms after restoration of all interference fields (right).



The relative mean telomere length of leukocytes is 0.93 (T/S Ratio).



The relative mean telomere length of leukocytes is 1.11 (T/S Ratio).

TEST RESULTS
Ages 46 to 50

36 %

Within the age group 46 to 50 years, this result corresponds to the 36th percentile of the database population for the telomere lengths of the relevant population sample. The result means that the telomeres are longer than in 36% of the persons in the relevant age group and thus still normative with a tendency to become shorter.

DIAGNOSTICS
INTERPRETATION

The normative length of your telomeres means that your biological age is approximately equal to your chronological age in years of life.

MEDICAL
METHODOLOGY

To measure the length of telomeres, the genomic DNA of peripheral leukocytes is extracted from a blood sample. As a measure of the relative mean telomere length, the ratio (T/S ratio) of the variable telomere length to the constant length of a gene once present in the genome (single-copy gene) is then determined by quantitative polymerase chain reaction (Q-PCR) which is then used as a standard reference. The individual test result is then compared with the data relevant for the age group in a database and classified in comparison with the clinical average values.

TEST RESULTS
Ages 46 to 50

68 %

Within the age group 46 to 50 years, this result corresponds to the 68th percentile of the database population for the telomere lengths of the relevant population sample. The result means that the telomeres are longer than in 68% of the individuals in the age group in question and are therefore equivalent to the norm.

DIAGNOSTICS
INTERPRETATION

The normative length of your telomeres means that your biological age is approximately equal to your chronological age in years of life.

MEDICAL
METHODOLOGY

To measure the length of telomeres, the genomic DNA of peripheral leukocytes is extracted from a blood sample. As a measure of the relative mean telomere length, the ratio (T/S ratio) of the variable telomere length to the constant length of a gene once present in the genome (single-copy gene) is then determined by quantitative polymerase chain reaction (Q-PCR) which is then used as a standard reference. The individual test result is then compared with the data relevant for the age group in a database and classified in comparison with the clinical average values.

Figure 3: Laboratory results on telomere length before (left) and after (right) interference field restoration (Ganzim-mun laboratory, Mainz).

	Current values	Baseline value 10/23/2019	(Optimal) target value
Bioenergetic Health Index (BHI)	1.35	0.39	> 2.5
Mitochondrial bioenergetics			
Coupling efficiency expressed as a percentage	81.39	71.19	100
Reserve respiratory capacity in %	263.00	111.17	> 400
Cellular oxygen consumption profile			
Contribution of non-mitochondrial respiration to total respiration in %	33.96	52.85	> 10
Contribution of proton leak to total respiration in %	12.13	13.57	
Contribution of respiration to mitochondrial ATP production in %	53.91	33.59	> 90
ATP turnover rate (mitochondrial oxygen consumption)			
ATP basal metabolic rate in %	22.75	33.77	> 20
ATP reserve in %	77.25	66.23	> 80
Possible maximum oxygen consumption rate in pmol oxygen/min.	99.58	46.22	> 300
Cellular energy phenotype			
Resting	dormant	glycolytic	dormant
With energy demand	energetic	glycolytic/aerobic	energetic
Metabolic potential in % – mitochondria –	270.93	152.29	> 350
Metabolic potential in % – glycolysis –	253.18	96.38	> 350
Oxygen consumption/glycolysis with energy demand	balanced	Strong preference for mitochondria	

Figure 4: Improvement of mitochondrial values within five days after surgical interference field restoration. The traffic light system shows a change from predominantly red (right-hand side) before the surgery to green/ yellow (left-hand side) after the surgery (MMD Laboratory, Magdeburg).

References and sources

THE CORRELATION BETWEEN DENTAL STRESS AND CHRONIC DISEASES

1. Bach J-F. The effect of infections on susceptibility to autoimmune and allergic diseases. *The New England Journal of Medicine*. 2002; 347 (12): 911-920.
2. Baio J, Wiggins L, Christensen DL, Maenner MJ, Daniels J, Warren Z, et al. Prevalence of Autism Spectrum Disorder Among Children Aged 8 Years—Autism and Developmental Disabilities Monitoring Network, 11 Sites, United States, 2014. *Morbidity and mortality weekly report Surveillance summaries* (Washington, DC: 2002). 2018; 67 (6): 1-23.
3. Kip M, Zimmermann A, Bless H-H. Epidemiologie der Multiplen Sklerose. In 2016. p. 13-21.
4. Huggins H. Root Canal Dangers: DNA Studies Confirm Dr. Weston Price's Century-Old Findings [Internet]. 2010. Available at: <http://www.westonaprice.org/holistic-healthcare/root-canal-dangers/>
5. Sharma K, Bittner F, Kamholz J. Epidemiology of multiple sclerosis in the United States (P1.140). *Neurology* [Internet]. 2018;90(15 Supplement). Available at: https://n.neurology.org/content/90/15_Supplement/P1.140
6. Grytten N, Torkildsen Ø, Myhr K-M. Time trends in the incidence and prevalence of multiple sclerosis in Norway during eight decades. *Acta neurologica Scandinavica*. 2015; 132 (199): 29-36.
7. Talbott EO, Malek AM, Lacomis D. The epidemiology of amyotrophic lateral sclerosis. *Handbook of clinical neurology*. 2016; 138: 225-238.
8. ALStreatment.com. ALS incidence [Internet]. 2019. Available at: <https://alstreatment.com/amyotrophic-lateral-sclerosis-incidence/>
9. Mehta P, Kaye W, Raymond J, Punjani R, Larson T, Cohen J, et al. Prevalence of Amyotrophic Lateral Sclerosis—United States, 2015. *MMWR Morbidity and mortality weekly report*. 2018; 67 (46): 1285-1289.
10. American Association of Endodontics. Available at: <https://www.aae.org/specialty/about-aae/news-room/endodontic-treatment-statistics/>
11. Greater Washington Endodontics. Available at: <https://va-rootcanal.com/dental-facts/>
12. KZBV. Jahrbuch 2018: Statistische Basisdaten zur vertragszahnärztlichen Versorgung. 2018.
13. Dr. Susan Blum. Autoimmunerkrankungen erfolgreich behandeln: Second edition: Kirchzarten: VAK Verlags GmbH; 2015.
14. VitaminDWiki. ALS [Internet]. 2019. Available at: <https://vitamindwiki.com/Incidence+of+30+health+problems+related+to+vitamin+D+has+doubled+in+a+decade>
15. Carina Rehberg. Titandioxid – Ein Stoff, den Sie meiden sollten [Internet]. 2019. Available at: <https://www.zentrum-der-gesundheit.de/titandioxid-verursacht-krebs-170204010.html>
16. Grande F, Tucci P. Titanium Dioxide Nanoparticles: a Risk for Human Health? *Mini-Reviews in Medicinal Chemistry*. 2016; 16 (9): 762-769.
17. Metalcor GmbH. Data sheet Ti1 [Internet]. 2019. Available at: <http://www.metalcor.de/datenblatt/121/>
18. Harloff T, Hönle W, Holzwarth U, Bader R, Thomas P, Schuh A. Titanium allergy or not? "Impurity" of titanium implant materials. *Health*. 2010; 02 (04): 306-310.
19. Giessen University. Entstehung der Nickel-Allergie aufgeklärt: Metall aktiviert Rezeptor des angeborenen Immunsystems [Internet]. 2010. Available at: <https://www.scinexx.de/news/biowissen/entstehung-der-nickel-allergie-aufgeklaert/>
20. Ahlström MG, Thyssen JP, Menné T, Johansen JD. Prevalence of nickel allergy in Europe following the EU Nickel Directive—a review. *Contact Dermatitis*. 2017; 77 (4): 193-200.
21. Schneiderman N, Ironson G, Siegel SD. Stress and health: psychological, behavioral, and biological determinants. *Annual Review of Clinical Psychology*. 2005; 1: 607-628.
22. Tracey KJ. The inflammatory reflex. *Nature*. 2002; 420 (6917): 853-859.
23. Gandhi OP, Morgan LL, de Salles AA, Han Y-Y, Herberman RB, Davis DL. Exposure limits: the underestimation of absorbed cell phone radiation, especially in children. *Electromagnetic Biology and Medicine*. 2012; 31 (1): 34-51.
24. Hardell L. Effects of Mobile Phones on Children's and Adolescents' Health: A Commentary. *Child Development*. 2018; 89 (1): 137-140.
25. Redmayne M. International policy and advisory response regarding children's exposure to radio frequency electromagnetic fields (RF-EMF). *Electromagnetic Biology and Medicine*. 2016; 35 (2): 176-185.
26. Sage C, Burgio E. Electromagnetic Fields, Pulsed Radiofrequency Radiation, and Epigenetics: How Wireless Technologies May Affect Childhood Development. *Child Development*. 2018; 89 (1): 129-136.
27. de Salles AA, Bulla G, Rodriguez CEF. Electromagnetic absorption in the head of adults and children due to mobile phone operation close to the head. *Electromagnetic Biology and Medicine*. 2006; 25 (4): 349-360.
28. Schoeni A, Roser K, Rössli M. Memory performance, wireless communication and exposure to radiofrequency electromagnetic fields: A prospective cohort study in adolescents. *Environment International*. 2015; 85: 343-351.
29. Chiu C-T, Chang Y-H, Chen C-C, Ko M-C, Li C-Y. Mobile phone use and health symptoms in children. *Journal of the Formosan Medical Association*. 2014; 114.
30. Fejes I, Závaczki Z, Szöllosi J, Koloszar S, Daru J, Kovács L, et al. Is there a relationship between cell

- phone use and semen quality? *Archives of Andrology*. 2005; 51 (5): 385-393.
31. Balci M, Devrim E, Durak I. Effects of mobile phones on oxidant/antioxidant balance in cornea and lens of rats. *Current Eye Research*. 2007; 32 (1): 21-25.
 32. Bortkiewicz A, Gadzicka E, Szymczak W. Mobile phone use and risk for intracranial tumors and salivary gland tumors—A meta-analysis. *International journal of occupational medicine and environmental health*. 2017; 30 (1): 27-43.
 33. Jenaro C, Flores N, Gómez-Vela M, González-Gil F, Caballo C. Problematic internet and cell-phone use: Psychological, behavioral, and health correlates. *Addiction Research & Theory*. 2007; 15 (3): 309-320.
 34. Kivrak EG, Yurt KK, Kaplan AA, Alkan I, Altun G. Effects of electromagnetic fields exposure on the antioxidant defense system. *Journal of Microscopy and Ultrastructure*. 2017; 5 (4): 167-176.
 35. Kocaman A, Altun G, Kaplan AA, Deniz ÖG, Yurt KK, Kaplan S. Genotoxic and carcinogenic effects of non-ionizing electromagnetic fields. *Environmental Research*. 2018; 163: 71-79.
 36. Nikolai Nikolaevich Kositsky, Aljona Igorevna Nizhelska. Influence of High-frequency Electromagnetic Radiation at Non-thermal Intensities on the Human Body (A review of work by Russian and Ukrainian researchers). *Newsletter of the Cellular Phone Taskforce Inc*. Februar 2001;(Volume 3, Number 1).
 37. Pall ML. Wi-Fi is an important threat to human health. *Environmental Research*. 2018; 164: 405-416.
 38. Prasad M, Kathuria P, Nair P, Kumar A, Prasad K. Mobile phone use and risk of brain tumours: a systematic review of association between study quality, source of funding, and research outcomes. *Neurological sciences : official journal of the Italian Neurological Society and of the Italian Society of Clinical Neurophysiology*. 2017; 38 (5): 797-810.
 39. Wang J, Su H, Xie W, Yu S. Mobile Phone Use and The Risk of Headache: A Systematic Review and Meta-analysis of Cross-sectional Studies. *Scientific Reports*. 2017; 7 (1): 12595.
 40. Wdowiak A, Mazurek PA, Wdowiak A, Bojar I. Effect of electromagnetic waves on human reproduction. *Annals of agricultural and environmental medicine : AAEM*. 2017; 24 (1): 13-18.
 41. La Vignera S, Condorelli RA, Vicari E, D'Agata R, Calogero AE. Effects of the exposure to mobile phones on male reproduction: a review of the literature. *Journal of Andrology*. 2012; 33 (3): 350-356.
 42. Lennart Hardell. World Health Organization, radiofrequency radiation and health—a hard nut to crack (Review). June 06, 2017;
 43. German Federal Office for Radiation Protection (Bundesamt für Strahlenschutz). 5G [Internet]. 2019. Available at: http://www.bfs.de/DE/themen/emf/mobilfunk/basiswissen/5g/5g_node.html
 44. Di Ciaula A. Towards 5G communication systems: Are there health implications? *International Journal of Hygiene and Environmental Health*. 2018; 221 (3): 367-375.
 45. McClelland S, Jaboin JJ. The Radiation Safety of 5G Wi-Fi: Reassuring or Russian Roulette? *International Journal of Radiation Oncology, Biology, Physics*. 2018; 101 (5): 1274-1275.
 46. Neufeld E, Kuster N. Systematic Derivation of Safety Limits for Time-Varying 5G Radiofrequency Exposure Based on Analytical Models and Thermal Dose. *Health Physics*. 2018.
 47. Russell CL. 5 G wireless telecommunications expansion: Public health and environmental implications. *Environmental Research*. 2018; 165: 484-495.
 48. Betzalel N, Ben Ishai P, Feldman Y. The human skin as a sub-THz receiver—Does 5G pose a danger to it or not? *Scientific Reports*. 2018; 163: 208-216.
 49. Lehmann I, Sack U, Lehmann J. Metal ions affecting the immune system. *Metal Ions in Life Sciences*. 2011; 8: 157-185.
 50. Zhou Y, Luo G-H. *Porphyromonas gingivalis* and digestive system cancers. *World Journal of Clinical Cases*. 2019; 7 (7): 819-829.
 51. Wei M-Y, Shi S, Liang C, Meng Q-C, Hua J, Zhang Y-Y, et al. The microbiota and microbiome in pancreatic cancer: more influential than expected. *Molecular Cancer*. 2019;18.
 52. Ha NH, Park DG, Woo BH, Kim DJ, Choi JI, Park BS, et al. *Porphyromonas gingivalis* increases the invasiveness of oral cancer cells by upregulating IL-8 and MMPs. *Cytokine*. 2016; 86: 64-72.
 53. Castellarin M, Warren RL, Freeman JD, Dreolini L, Krzywinski M, Strauss J, et al. *Fusobacterium nucleatum* infection is prevalent in human colorectal carcinoma. *Genome Research*. 2012; 22 (2): 299-306.
 54. Tezal M, Sullivan MA, Reid ME, Marshall JR, Hyland A, Loree T, et al. Chronic periodontitis and the risk of tongue cancer. *Archives of Otolaryngology-Head & Neck Surgery*. 2007; 133 (5): 450-454.
 55. Guven DC, Dizdar O, Alp A, Akdoğan Kittana FN, Karakoc D, Hamaloglu E, et al. Analysis of *Fusobacterium nucleatum* and *Streptococcus gallolyticus* in saliva of colorectal cancer patients. *Biomarkers in Medicine*. 2019; 13 (9): 725-735.
 56. Mahendra J, Mahendra L, Kurian VM, Jaishankar K, Mythilli R. 16S rRNA-based detection of oral pathogens in coronary atherosclerotic plaque. *Indian Journal of Dental Research : official publication of Indian Society for Dental Research*. 2010; 21 (2): 248-252.
 57. Dominy SS, Lynch C, Ermini F, Benedyk M, Marczyk A, Konradi A, et al. *Porphyromonas gingivalis* in Alzhei-

mer's disease brains: Evidence for disease causation and treatment with small-molecule inhibitors. *Science Advances*. 2019; 5 (1): eaau3333.

58. Ott SJ, El Mokhtari NE, Musfeldt M, Hellmig S, Freitag S, Rehman A, u. a. Detection of diverse bacterial signatures in atherosclerotic lesions of patients with coronary heart disease. *Circulation*. 2006; 113 (7): 929-937.
59. Hieken TJ, Chen J, Hoskin TL, Walther-Antonio M, Johnson S, Ramaker S, et al. The Microbiome of Aseptically Collected Human Breast Tissue in Benign and Malignant Disease. *Scientific Reports*. 2016; 6: 30751.

CHANGES IN OUR ENVIRONMENT

1. Thomas Karow RL-R. Allgemeine und Spezielle Pharmakologie und Toxikologie: vorlesungsorientierte Darstellung und klinischer Leitfaden für Studium und Praxis 23.Auflage. 2014.
2. Wehrwein EA, Orer HS, Barman SM. Overview of the Anatomy, Physiology, and Pharmacology of the Autonomic Nervous System. *Comprehensive Physiology*. 2016; 6 (3): 1239-1278.
3. Karemaker JM. An introduction into autonomic nervous function. *Physiological Measurement*. 2017;38(5):R89-118.
4. Optimum.me. Dr. Otto Warburg und sein Medizin-Nobelpreis [Internet]. 2014. Available at: <https://www.optimum.me/saeure-basen-haushalt/dr-otto-warburg-und-sein-medizin-nobelpreis>
5. Dr. med. Alfred Lohninger. Herzratenvariabilität: Das HRV-Praxis-Lehrbuch. facultas; 2017.
6. Shaffer F, McCraty R, Zerr CL. A healthy heart is not a metronome: an integrative review of the heart's anatomy and heart rate variability. *Frontiers in Psychology*. 2014; 5: 1040.
7. Kemp AH, Quintana DS. The relationship between mental and physical health: insights from the study of heart rate variability. *International Journal of Psychophysiology* : official journal of the International Organization of Psychophysiology. 2013; 89 (3): 288-296.
8. Golbidi S, Li H, Laher I. Oxidative Stress: A Unifying Mechanism for Cell Damage Induced by Noise, (Water-Pipe) Smoking, and Emotional Stress-Therapeutic Strategies Targeting Redox Imbalance. *Antioxidants & redox signaling*. 2018; 28 (9): 741-759.
9. VNS ANALYSIS SAMPLE MEASUREMENTS. Available at: <https://www.vnsanalyse.de/de/anwendung/beispiele-vns-analysen.html>
10. Dr. med. dent. Johann Lechner. Immunstress durch Zahnmetalle und Elektrosmog. *Raum & Zeit*. 1995 (74): 5-13.
11. Gomes C, Martinho FC, Barbosa DS, Antunes LS, Póvoa HCC, Baltus THL, et al. Increased Root Canal Endotoxin Levels are Associated with Chronic Apical Periodontitis, Increased Oxidative and Nitrosative Stress, Major

Depression, Severity of Depression, and a Lowered Quality of Life. *Molecular Neurobiology*. 2018; 55 (4): 2814-2827.

12. Reiffenstein RJ, Hulbert WC, Roth SH. Toxicology of hydrogen sulfide. *Annual Review of Pharmacology and Toxicology*. 1992; 32: 109-134.
13. Valko M, Rhodes CJ, Moncol J, Izakovic M, Mazur M. Free radicals, metals and antioxidants in oxidative stress-induced cancer. *Chemico-biological interactions*. 2006; 160 (1): 1-40.
14. Saha SK, Lee SB, Won J, Choi HY, Kim K, Yang G-M, et al. Correlation between Oxidative Stress, Nutrition, and Cancer Initiation. *International Journal of Molecular Sciences*. 2017; 18 (7).
15. Dhas Y, Mishra N, Banerjee J. Vitamin D Deficiency and Oxidative Stress in Type 2 Diabetic Population of India. *Cardiovascular & Hematological Agents in Medicinal Chemistry*. 2017; 14 (2): 82-89.
16. Belyaev I, Dean A, Eger H, Hubmann G, Jandrisovits R, Kern M, et al. EUROPAEM EMF Guideline 2016 for the prevention, diagnosis and treatment of EMF-related health problems and illnesses. *Reviews Environmental Health*. 2016; 31 (3): 363-397.
17. Lutgendorf SK, Costanzo ES. Psychoneuroimmunology and health psychology: an integrative model. *Brain, Behavior, and Immunity*. 2003; 17 (4): 225-232.
18. Di Yang, Yang X, Deng F, Guo X. Ambient Air Pollution and Biomarkers of Health Effect. *Advances in Experimental Medicine and Biology*. 2017; 1017: 59-102.
19. Kotłęga D, Gołęb-Janowska M, Masztalewicz M, Ciećwież S, Nowacki P. The emotional stress and risk of ischemic stroke. *Neurologia i Neurochirurgia Polska*. 2016; 50 (4): 265-270.
20. Pongratz G, Straub RH. Role of peripheral nerve fibres in acute and chronic inflammation in arthritis. *Nature Reviews Rheumatology*. 2013; 9 (2): 117-126.
21. Straub RH, Rauch L, Fassold A, Lowin T, Pongratz G. Neuronally released sympathetic neurotransmitters stimulate splenic interferon-gamma secretion from T cells in early type II collagen-induced arthritis. *Arthritis & Rheumatology*. 2008; 58 (11): 3450-3460.
22. Pongratz G, Straub RH. The sympathetic nervous response in inflammation. *Arthritis Research & Therapy*. 2014; 16 (6): 504.
23. Koopman FA, van Maanen MA, Vervoordeldonk MJ, Tak PP. Balancing the autonomic nervous system to reduce inflammation in rheumatoid arthritis. *Journal of Internal Medicine*. 2017; 282 (1): 64-75.

MECHANISMS OF ORAL DISTURBANCES

1. Ganzimmun Diagnostics AG. Endotoxinämie: LPS im Serum als Marker für Silent Inflammation. 2015 (26 (0086)): 1-11.
2. Cotti E, Dessi C, Piras A, Flore G, Deidda M,

- Madeddu C, u. a. Association of endodontic infection with detection of an initial lesion to the cardiovascular system. *Journal of Endodontics*. 2011; 37 (12): 1624-1629.
3. Cotti E, Dessì C, Piras A, Mercurio G. Can a chronic dental infection be considered a cause of cardiovascular disease? A review of the literature. *International Journal of Cardiology*. 2011; 148 (1): 4-10.
 4. Bains R, Bains VK. Lesions of endodontic origin: An emerging risk factor for coronary heart diseases. *Indian Heart Journal*. 2018; 70 Suppl. 3: p. 431-4.
 5. Shelley Farrar Stoakes. Functions of MHC in the Immune System [Internet]. News Medical Life Science, Editor. Available at: <https://www.news-medical.net/life-sciences/Functions-of-MHC-in-the-Immune-System.aspx>
 6. Rassow J. *Biochemie: 50 tables*. Second updated edition, Stuttgart. Thieme; 2008. (dual series).
 7. Pendergrass JC, Haley BE. Inhibition of brain tubulin-guanosine 5'-triphosphate interactions by mercury: similarity to observations in Alzheimer's diseased brain. *Metal ions in biological systems*. 1997; 34: 461-478.
 8. Stejskal J, Stejskal V. The role of metals in autoimmunity and the link to neuroendocrinology. *Neuroendocrinology Letters*. 1999; 20: 351-364.
 9. Mutter J., Klinghardt D. Amalgam: Risiko für die Menschheit; Quecksilbervergiftungen richtig ausleiten, neue Fakten und Hilfe, auch nach der Amalgamentfernung! third revised and enlarged edition, [reprint]. Weil der Stadt: Fit-fürs-Leben publisher. In NaturaViva-Verl.-GmbH; 2013. (health).
 10. Trepel M. *Neuroanatomie: Struktur und Funktion*; [online access and interactive extras]. Fourth revised edition, [reprint]. Munich: Elsevier; 2009. (StudentConsult).
 11. Fischer L. *Pathophysiologie des Schmerzes und Neuraltherapie*. Praxis. 2003; 92 (48): 2051-2059.
 12. Goon ATJ, Isaksson MAI. Hand Eczema from Acrylate Compounds in Dentistry. In: Alikhan A, Lachapelle J-M, Maibach HI, editor. *Textbook of Hand Eczema*. Berlin, Heidelberg: Springer Berlin Heidelberg; 2014. p. 169-183.
 13. Dr. Kurt E. Müller. Immunreaktion auf physiologisch nicht benötigte Metalle. UMG [Internet]. 2013(4). Available at: <http://deguz.de/fachkreise/fachinformationen/metalle-und-Metallischer-zahnersatz/immunreaktion-auf-physiologisch-nicht-benoetigte-metalle.html/metalle-und-Metallischer-zahnersatz/immunreaktion-auf-physiologisch-nicht-benoetigte-metalle.html>
 14. Rader CP, Sterner T, Jakob F, Schütze N, Eulert J. Cytokine response of human macrophage-like cells after contact with polyethylene and pure titanium particles. *The Journal of Arthroplasty*. 1999; 14 (7): 840-848.
 15. Cadosch D, Chan E, Gautschi OP, Meagher J, Zellweger R, Filgueira L. Titanium IV ions induced human osteoclast differentiation and enhanced bone resorption in vitro. *Journal of biomedical materials research Part A*. 2009; 91(1): 29-36.
 16. Volker von Baehr, Sabine Schütt. Immunologische Grundlagen der Titaninduzierten Periimplantitis. *ZMK*. 2011; 27: 21-26.
 17. von Baehr V. Titanunverträglichkeit. *ZWR - Das Deutsche Zahnärzteblatt*. 2018; 127 (04): 180-181.
 18. Safioti LM, Kotsakis GA, Pozhitkov AE, Chung WO, Daubert DM. Increased Levels of Dissolved Titanium Are Associated With Peri-Implantitis - A Cross-Sectional Study. *Journal of periodontology*. 2017; 88 (5): 436-442.
 19. Myneni VD, Mezey E. Regulation of bone remodeling by vitamin K2. *Oral Diseases*. 2017; 23 (8): 1021-1028.
 20. Aghajanian P, Hall S, Wongworawat MD, Mohan S. The Roles and Mechanisms of Actions of Vitamin C in Bone: New Developments: ROLES AND MECHANISMS OF VITAMIN C IN BONE. *J Bone Miner Res*. November 2015; 30 (11): 1945-55.
 21. Chin K-Y, Ima-Nirwana S. Vitamin C and Bone Health: Evidence from Cell, Animal and Human Studies. *CDT*. March 19, 2018; 19 (5): 439-50.
 22. Nakamichi Y, Udagawa N, Horibe K, Mizoguchi T, Yamamoto Y, Nakamura T, et al. VDR in Osteoblast-Lineage Cells Primarily Mediates Vitamin D Treatment-Induced Increase in Bone Mass by Suppressing Bone Resorption: VITAMIN D TREATMENT INCREASES BONE MASS VIA OSTEOBLAST-LINEAGE VDR. *J Bone Miner Res*. JUNE 2017; 32 (6): 1297-308.
 23. van Leeuwen JP, van Driel M, van den Bermd GJ, Pols HA. Vitamin D control of osteoblast function and bone extracellular matrix mineralization. *Critical reviews in eukaryotic gene expression*. 2001; 11 (1- 3): 199-226.
 24. Lindsey RC, Cheng S, Mohan S. Vitamin C effects on 5-hydroxymethylcytosine and gene expression in osteoblasts and chondrocytes: Potential involvement of PHD2. *PLoS one*. 2019; 14 (8): e0220653.
 25. Kajarabille N, Díaz-Castro J, Hijano S, López-Frías M, López-Aliaga I, Ochoa JJ. A new insight to bone turnover: role of ω -3 polyunsaturated fatty acids. *The Scientific World Journal*. 2013; 2013: 589641.
 26. Liu H, Li W, Jia S, Li B. Puerarin and zinc additively prevent mandibular bone loss through inhibiting osteoclastogenesis in ovariectomized rats. *Histology and Histopathology*. 2017; 32 (8): 851-860.
 27. Welch AA, Skinner J, Hickson M. Dietary Magnesium May Be Protective for Aging of Bone and Skeletal Muscle in Middle and Younger Older Age Men and Women: Cross-Sectional Findings from the UK Biobank Cohort. *Nutrients*. 2017; 9 (11).
 28. Li A, Cong Q, Xia X, Leong WF, Yeh J, Miao D, et al. Pharmacologic Calcitriol Inhibits Osteoclast Lineage

- Commitment via the BMP-Smad1 and $\text{NF-}\kappa\text{B}$ Pathways. *Journal of bone and mineral research: the official journal of the American Society for Bone and Mineral Research*. 2017; 32 (7): 1406-1420.
29. Choi H, Kim G-J, Yoo H-S, Song D, Chung K-H, Lee K-J, et al. Vitamin C Activates Osteoblastogenesis and Inhibits Osteoclastogenesis via Wnt/ β -Catenin/ATF4 Signaling Pathways. *Nutrients*. February 27, 2019; 11 (3): 506.
30. 2nd International Conference on Membrane Science and Technology. 2018.
31. Komabayashi T, Nonomura G, Watanabe LG, Marshall GW, Marshall SJ. Dentin tubule numerical density variations below the CEJ. *Journal of Dentistry*. 2008; 36 (11): 953-958.
32. Kwang S, Abbott P. The presence and distribution of bacteria in dentinal tubules of root filled teeth. *International endodontic journal*. 2014; 47 (6): 600-610.
33. Mjör IA, Nordahl I. The density and branching of dentinal tubules in human teeth. *Archives of Oral Biology*. 1996; 41 (5): 401-412.
34. Merkur.de. Diese Viren und Bakterien machen uns krank: Sie sind unsichtbar, aber überall: Viren und Bakterien machen uns krank. Doch die beiden Erreger haben sonst wenig gemeinsam. Warum sie sich unterscheiden. [Internet]. 2017. Available at: <https://www.merkur.de/leben/gesundheit/viren-bakterien-sind-menschen-gefaehrlich-virusinfektion-zr-4417390.html>
35. Biologieschule.de. Makrophage [Internet]. Available at: <http://www.biologie-schule.de/makrophage.php>
36. Jacobi-Gresser E, Schütt S, Huesker K, von Baehr V. Methyl mercaptan and hydrogen sulfide products stimulate proinflammatory cytokines in patients with necrotic pulp tissue and endodontically treated teeth. *Journal of biological regulators and homeostatic agents*. 2015; 29 (1): 73-84.
37. Lechner J, von Baehr V. Impact of Endodontically Treated Teeth on Systemic Diseases. *Dentistry*. 2018; 08 (03).
38. Lechner J, von Baehr V. Stimulation of proinflammatory cytokines by volatile sulfur compounds in endodontically treated teeth. *International journal of general medicine*. 2015; 8: 109-118.
39. Gomes C, Martinho FC, Barbosa DS, Antunes LS, Póvoa HCC, Baltus THL, et al. Increased Root Canal Endotoxin Levels are Associated with Chronic Apical Periodontitis, Increased Oxidative and Nitrosative Stress, Major Depression, Severity of Depression, and a Lowered Quality of Life. *Molecular Neurobiology*. 2018; 55 (4): 2814-2827.
40. Vahlkamp T, Meijer AJ, Wilms J, Chamuleau RA. Inhibition of mitochondrial electron transfer in rats by ethanethiol and methanethiol. *Clinical science (London, England, 1979)*. 1979; 56 (2): 147-156.
41. IMD Berlin. Labordiagnostik bei chronisch entzündlichen Multisystemerkrankungen [Internet]. Available at: <https://www.imd-berlin.de/fachinformationen/diagnostikinformationen/entzuendungsdiagnostik-bei-multisystemerkrankungen.html>
42. Siqueira JF, Rôças IN, Alves FRF, Silva MG. Bacteria in the apical root canal of teeth with primary apical periodontitis. *Oral surgery, oral medicine, oral pathology, oral radiology, and endodontics*. 2009; 107 (5): 721-726.
43. Richardson N, Mordan NJ, Figueiredo JAP, Ng Y-L, Gulabivala K. Microflora in teeth associated with apical periodontitis: a methodological observational study comparing two protocols and three microscopy techniques. *International endodontic journal*. 2009; 42 (10): 908-921.
44. Dr. Elisabeth Jacobi-Gresser. Risiken für chronische Entzündungen durch orale Reizfaktoren: Immunlabordiagnostik in der Zahnheilkunde. *ZMK Allgemeine Zahnheilkunde*. September 28, 2012;
45. Cai X, Cao C, Li J, Chen F, Zhang S, Liu B, u. a. Inflammatory factor TNF- α promotes the growth of breast cancer via the positive feedback loop of TNFR1/ $\text{NF-}\kappa\text{B}$ (and/or p38)/p-STAT3/HBXIP/TNFR1. *Oncotarget*. 2017; 8 (35): 58338-58352.
46. Wolczyk D, Zaremba-Czogalla M, Hryniewicz-Jankowska A, Tabola R, Grabowski K, Sikorski AF, et al. TNF- α promotes breast cancer cell migration and enhances the concentration of membrane-associated proteases in lipid rafts. *Cellular Oncology (Dordrecht)*. 2016; 39 (4): 353-363.
47. Psiram.com. Thomas Rau [Internet]. 2018. Available at: https://www.psiram.com/de/index.php/Thomas_Rau
48. Aminoshariae A, Kulild JC, Mickel A, Fouad AF. Association between Systemic Diseases and Endodontic Outcome: A Systematic Review. *Journal of Endodontics*. 2017; 43 (4): 514-519.
49. Murray CA, Saunders WP. Root canal treatment and general health: a review of the literature. *International endodontic journal*. 2000; 33 (1): 1-18.
50. Liljestrand JM, Mäntylä P, Paju S, Buhlin K, Kopra KAE, Persson GR, et al. Association of Endodontic Lesions with Coronary Artery Disease. *Journal of Dental Research*. 2016; 95 (12): 1358-1365.
51. Segura-Egea JJ, Martín-González J, Castellanos-Cosano L. Endodontic medicine: connections between apical periodontitis and systemic diseases. *International endodontic journal*. 2015; 48 (10): 933-951.
52. IMD Berlin. Lymphozytentransformationstest (LTT) Zahnersatzmaterialien können Allergien verursachen [Internet]. Available at: <https://www.imd-berlin.de/spezielle-kompetenzen/zahnmedizin/allergien-und-unvertraeglichkeiten.html>

53. Gleditsch JM. Reflexzonen und Somatotopien: Vom Mikrosystem zu einer Gesamtschau des Menschen. Ninth edition. Urban & Fischer; 2005.
54. Chung MK BTL. Neural Therapy: An Overlooked Game Changer for Patients Suffering Chronic Pain? *Journal of Pain & Relief*. 2015; 04 (03).
55. Mieg R. Krankheitsherd Zähne: Wie sich kranke Zähne auf den ganzen Körper auswirken; mit vielen eindrucklichen Fallbeispielen; [Probleme erkennen - Hilfe finden]. [Sixth edition]. Stuttgart: Trias; 2010.
56. Voll R. Wechselbeziehungen von Odontonen und Tonsillen zu Organen, Störfeldern und Gewebssystemen. Fifth unchanged edition. Uelzen: Med.-Literarische Verl.-Ges; 1996.
57. Hahn-Godeffroy JD. Procain in der Neuraltherapie nach Huneke: Literaturüberblick und zusammenfassende Bewertung: Special edition. Fortbildung und Praxis für den Hausarzt. 14/93;15:876-883.
58. Hahn-Godeffroy JD, Mangold S, Bernert M, Bartelt A, Herdegen T. Langanhaltende Besserung von somatischen und psychovegetativen Störungen unter Procain-Infusionen: Eine multizentrische Anwendungsbeobachtung. *Complementary Medicine Research*. 2019; 26 (1): 13-21.
59. Lee JM, Suh JK, Jeong JS, Cho SY, Kim DW. Antioxidant effect of lidocaine and procaine on reactive oxygen species-induced endothelial dysfunction in the rabbit abdominal aorta. *Korean journal of anesthesiology*. 2010; 59 (2): 104-110.
60. URM R, R O, H N. Procaine and Procaine-Base-Infusion: A Review of the Safety and Fields of Application after Twenty Years of Use. *Clinical Research: Open Access*. 2018; 4 (1).
61. Badtke G. Neuraltherapie: Textbook and atlas. Second revised and enlarged edition. Wiesbaden: Ullstein Medical; 1998.
62. wikipedia. Viszerokutaner Reflex [Internet]. Available at: https://de.wikipedia.org/wiki/Viszerokutaner_Reflex
63. Orotox. Über Orotox [Internet]. 2019. Available at: <https://www.orotox.de/ueber-orotox/>
- Edition. Weil der Stadt: Fit fürs Leben publisher; 2014.
4. Bernhoft RA. Mercury toxicity and treatment: a review of the literature. *Journal of environmental and public health*. 2012; 2012: 460508.
5. Khan M, Naqvi AH, Ahmad M. Comparative study of the cytotoxic and genotoxic potentials of zinc oxide and titanium dioxide nanoparticles. *Toxicology Reports*. 2015; 2: 765-774.
6. Bjorklund G, Stejskal V, Urbina MA, Dadar M, Chirumbolo S, Mutter J. Metals and Parkinson's Disease: Mechanisms and Biochemical Processes. *Current Medicinal Chemistry*. 2018; 25 (19): 2198-2214.
7. Cariccio VL, Samà A, Bramanti P, Mazzon E. Mercury Involvement in Neuronal Damage and in Neurodegenerative Diseases. *Biological Trace Element Research*. 2019; 187 (2): 341-356.
8. Ingalls TH. Endemic clustering of multiple sclerosis in time and place, 1934-1984. Confirmation of a hypothesis. *The American Journal of Forensic Medicine and Pathology*. 1986; 7 (1): 3-8.
9. Mutter J. Is dental amalgam safe for humans? The opinion of the scientific committee of the European Commission. *Journal of occupational medicine and toxicology (London, England)*. 2011; 6: 2.
10. Siblingud RL. The relationship between mercury from dental amalgam and the cardiovascular system. *Science of The Total Environment*. 1990; 99 (1- 2): 23-35.
11. Siblingud RL, Motl J, Kienholz E. Psychometric evidence that mercury from silver dental fillings may be an etiological factor in depression, excessive anger, and anxiety. *Psychological Reports*. 1994; 74 (1): 67-80.
12. Wojcik DP, Godfrey ME, Christie D, Haley BE. Mercury toxicity presenting as chronic fatigue, memory impairment and depression: diagnosis, treatment, susceptibility, and outcomes in a New Zealand general practice setting (1994-2006). *Neuroendocrinology Letters*. 2006; 27 (4): 415-423.
13. Volz U. Qualitative Untersuchungen zur Amalgaminvasion in die Zahnpulpa. Inaugural dissertation for the obtention of the doctorate. Ulm. 1992.
14. IMD Berlin. Titanunverträglichkeit [Internet]. Available at: <https://www.imd-berlin.de/fachinformationen/diagnostikinformationen/titan-unvertraeglichkeit.html>
15. Christian Nobmann. Die neuen Regelungen zu Amalgam. *zm online* [Internet]. 2018; (13). Available at: <https://www.zm-online.de/archiv/2018/13/titel/die-neuen-regelungen-zu-amalgam/>
16. Bengtsson UG, Hylander LD. Increased mercury emissions from modern dental amalgams. *Biometals: an international journal on the role of metal ions in biology, biochemistry, and medicine*. 2017; 30 (2): 277-283.
17. Taskinen H, Kinnunen E, Riihimäki V. A possible case of mercury-related toxicity resulting from the grinding of old amalgam restorations. *Scandinavian Journal of*

THE EFFECTS OF A RANGE OF MATERIALS ON THE BODY

1. Stejskal J, Stejskal V. The role of metals in autoimmunity and the link to neuroendocrinology. *Neuroendocrinology Letters*. 1999; 20: 351-364.
2. Mutter J., Klinghardt D. Amalgam: Risiko für die Menschheit; Quecksilbervergiftungen richtig ausleiten, neue Fakten und Hilfe, auch nach der Amalgamentfernung! third revised and enlarged edition, [reprint]. Weil der Stadt: Fit-fürs-Leben publisher. In NaturaViva-Verl.-GmbH; 2013. (health).
3. Mutter J. Gesund statt chronisch krank!: Der ganzheitliche Weg: Vorbeugung und Heilung sind möglich. 3.

- Work, Environment & Health. 1989; 15 (4): 302–304.
18. Eggleston DW, Nylander M. Correlation of dental amalgam with mercury in brain tissue. *The Journal of Prosthetic Dentistry*. 1987; 58 (6): 704–707.
 19. Thier R, Bonacker D, Stoiber T, Böhm KJ, Wang M, Unger E, et al. Interaction of metal salts with cytoskeletal motor protein systems. *Toxicology Letters*. 2003; 140–141: 75–81.
 20. Stoiber T, Degen GH, Bolt HM, Unger E. Interaction of mercury(II) with the microtubule cytoskeleton in IMR-32 neuroblastoma cells. *Toxicology Letters*. 2004; 151 (1): 99–104.
 21. Stoiber T, Bonacker D, Böhm KJ, Bolt HM, Thier R, Degen GH, et al. Disturbed microtubule function and induction of micronuclei by chelate complexes of mercury(II). *Mutation Research*. 2004; 563 (2): 97–106.
 22. Pendergrass JC HBE. Mercury-EDTA Complex Specifically Blocks Brain-Tubulin-GTP Interactions: Similarity to Observations in Alzheimer's Disease. In *Status Quo and Perspective of Amalgam and Other Dental Materials*. International Symposium Proceedings. Edited by Friberg LT, Schrauzer GN Stuttgart: Thieme Verlag. 1995; 98–105.
 23. Pendergrass JC, Haley BE. Inhibition of brain tubulin-guanosine 5'-triphosphate interactions by mercury: similarity to observations in Alzheimer's diseased brain. *Metal ions in biological systems*. 1997; 34: 461–478.
 24. Mackert JR, Berglund A. Mercury exposure from dental amalgam fillings: absorbed dose and the potential for adverse health effects. *Critical reviews in oral biology and medicine: an official publication of the American Association of Oral Biologists*. 1997; 8 (4): 410–436.
 25. Barregård L, Svalander C, Schütz A, Westberg G, Sällsten G, Blohmé I, et al. Cadmium, mercury, and lead in kidney cortex of the general Swedish population: a study of biopsies from living kidney donors. *Environmental Health Perspectives*. 1999; 107 (11): 867–871.
 26. Becker K, Schulz C, Kaus S, Seiwert M, Seifert B. German Environmental Survey 1998 (GerES III): environmental pollutants in the urine of the German population. *International Journal of Hygiene and Environmental Health*. 2003; 206 (1): 15–24.
 27. Becker K, Kaus S, Krause C, Lepom P, Schulz C, Seiwert M, et al. German Environmental Survey 1998 (GerES III): environmental pollutants in blood of the German population. *International Journal of Hygiene and Environmental Health*. 2002; 205 (4): 297–308.
 28. Drasch G, Schupp I, Riedl G, Günther G. Einfluss von Amalgamfüllungen auf die Quecksilberkonzentration in menschlichen Organen. *Deutsche Zahnärztl Z*. 1992(08): 490–496.
 29. Drasch G, Schupp I, Höfl H, Reinke R, Roeder G. Mercury burden of human fetal and infant tissues. *European Journal of Pediatrics*. 1994; 153 (8): 607–610.
 30. Drasch G, Wanghofer E, Roeder G. Are blood, urine, hair, and muscle valid bio-monitoring parameters for the internal burden of men with the heavy metals mercury, lead and cadmium? *Trace Elem Electrolyt*. 1997 (14): 116–123.
 31. Gottwald B, Traenckner I, Kupfer J, Ganss C, Eis D, Schill WB, et al. "Amalgam disease"—poisoning, allergy, or psychic disorder? *International Journal of Hygiene and Environmental Health*. 2001; 204 (4): 223–229.
 32. Guzzi G, Grandi M, Cattaneo C. Should amalgam fillings be removed? *Lancet*. 2002; 380–2081.
 33. Guzzi G, Grandi M, Cattaneo C, Calza S, Minoia C, Ronchi A, u. a. Dental amalgam and mercury levels in autopsy tissues: food for thought. *The American Journal of Forensic Medicine and Pathology*. 2006; 27 (1): 42–45.
 34. Levy M, Schwartz S, Djak M, Weber J-P, Tardif R, Rouah F. Childhood urine mercury excretion: dental amalgam and fish consumption as exposure factors. *Environmental Research*. 2004; 94 (3): 283–290.
 35. Lorscheider FL, Vimy MJ, Summers AO. Mercury exposure from "silver" tooth fillings: emerging evidence questions a traditional dental paradigm. *The FASEB Journal*. 1995; 9 (7): 504–508.
 36. Kingman A, Albertini T, Brown LJ. Mercury concentrations in urine and whole blood associated with amalgam exposure in a US military population. *Journal of Dental Research*. 1998; 77 (3): 461–471.
 37. Mortada W, Sobh M, M El-Defrawy M, E Farahat S. Mercury in dental restoration: Is there a risk of nephrotoxicity? *Journal of Nephrology*. 2002; 15: 171–176.
 38. Nylander M. MERCURY IN PITUITARY GLANDS OF DENTISTS. *The Lancet*. 1986; 327 (8478): 442.
 39. Nylander M, Friberg L, Lind B. Mercury concentrations in the human brain and kidneys in relation to exposure from dental amalgam fillings. *Swedish dental journal*. 1987; 11 (5): 179–187.
 40. Nylander M, Weiner J. Mercury and selenium concentrations and their interrelations in organs from dental staff and the general population. *British Journal of Industrial Medicine*. 1991; 48 (11): 729–734.
 41. Pizzichini M, Fonzi M, Giannerini F, Mencarelli M, Gasparoni A, Rocchi G, et al. Influence of amalgam fillings on Hg levels and total antioxidant activity in plasma of healthy donors. *Science of The Total Environment*. 2003; 301 (1–3): 43–50.
 42. AXELWEINER J, Nylander M. The relationship between mercury concentration in human organs and different predictor variables. *Science of The Total Environment*. 1993; 138 (1–3): 101–115.
 43. Zimmer H, Ludwig H, Bader M, Bailer J, Eickholz P, Staehle HJ, u. a. Determination of mercury in blood, urine and saliva for the biological monitoring of an exposure from amalgam fillings in a group with self-re-

- ported adverse health effects. *International Journal of Hygiene and Environmental Health*. 2002; 205 (3): 205–211.
44. Ask K, Akesson A, Berglund M, Vahter M. Inorganic mercury and methylmercury in placentas of Swedish women. *Environmental Health Perspectives*. 2002; 110 (5): 523–526.
 45. Takahashi Y. Placental transfer of mercury in pregnant rats which received dental amalgam restorations. *Toxicology*. 2003; 185 (1-2): 23–33.
 46. Holmes AS, Blaxill MF, Haley BE. Reduced levels of mercury in first baby haircuts of autistic children. *International journal of toxicology*. 2003; 22 (4): 277–285.
 47. Morgan DL, Chanda SM, Price HC, Fernando R, Liu J, Brambila E, et al. Disposition of inhaled mercury vapor in pregnant rats: maternal toxicity and effects on developmental outcome. *Toxicological sciences: an official journal of the Society of Toxicology*. 2002; 66 (2): 261–273.
 48. Takahashi Y. Release of mercury from dental amalgam fillings in pregnant rats and distribution of mercury in maternal and fetal tissues. *Toxicology*. 2001; 163 (2– 3): 115–126.
 49. Vahter M, Akesson A, Lind B, Björs U, Schütz A, Berglund M. Longitudinal study of methylmercury and inorganic mercury in blood and urine of pregnant and lactating women, as well as in umbilical cord blood. *Environmental Research*. 2000; 84 (2): 186–194.
 50. Yoshida M, Watanabe C, Satoh M, Yasutake A, Sawada M, Ohtsuka Y, et al. Susceptibility of metallothionein-null mice to the behavioral alterations caused by exposure to mercury vapor at human-relevant concentration. *Toxicological sciences: an official journal of the Society of Toxicology*. 2004; 80 (1): 69–73.
 51. Drasch G, Aigner S, Roider G, Staiger F, Lipowsky G. Mercury in human colostrum and early breast milk. Its dependence on dental amalgam and other factors. *Journal of trace elements in medicine and biology: organ of the Society for Minerals and Trace Elements (GMS)*. 1998; 12 (1): 23–27.
 52. Oskarsson A, Schültz A, Skerfving S, Hallén IP, Ohlin B, Lagerkvist BJ. Total and inorganic mercury in breast milk in relation to fish consumption and amalgam in lactating women. *Archives of Environmental Health*. 1996; 51 (3): 234–241.
 53. Vimy MJ, Hooper DE, King WW, Lorscheider FL. Mercury from maternal “silver” tooth fillings in sheep and human breast milk. *Biological Trace Element Research*. 1997; 56 (2): 143–152.
 54. Yoshida M, Satoh M, Shimada A, Yamamoto E, Yasutake A, Tohyama C. Maternal-to-fetus transfer of mercury in metallothionein-null pregnant mice after exposure to mercury vapor. *Toxicology*. 2002; 175 (1-3): 215–222.
 55. McKee A, Fontenot A. Interplay of innate and adaptive immunity in metal-induced hypersensitivity. *Current Opinion in Immunology*. 2016; 42: 25–30.
 56. Saravanakumar P, Thallam Veeravalli P, Kumar V A, Mohamed K, Mani U, Grover M, et al. Effect of Different Crown Materials on the InterLeukin-One Beta Content of Gingival Crevicular Fluid in Endodontically Treated Molars: An Original Research. *Cureus*. 2017;9(6):e1361.
 57. Lehmann I, Sack U, Lehmann J. Metal ions affecting the immune system. *Metal Ions in Life Sciences*. 2011; 8: 157–185.
 58. Zohdi H, Emami M, Reza H. Galvanic Corrosion Behavior of Dental Alloys. In: Valdez B, editor. *Environmental and Industrial Corrosion – Practical and Theoretical Aspects*. InTech; 2012.
 59. Procházková J, Podzimek S, Tomka M, Kucerová H, Mihaljevic M, Hána K, et al. Metal alloys in the oral cavity as a cause of oral discomfort in sensitive patients. *Neuroendocrinology Letters*. 2006; 27 Suppl 1:53–58.
 60. Johansson BI. Electrochemical action due to short-circuiting of dental alloys. An in vitro and in vivo study. *Swedish dental journal Supplement*. 1986; 33: 1–47.
 61. Ciszewski A, Baraniak M, Urbanek-Brychczyńska M. Corrosion by galvanic coupling between amalgam and different chromium-based alloys. *Dental materials: official publication of the Academy of Dental Materials*. 2007; 23 (10): 1256–1261.
 62. Taher NM, Al Jabab AS. Galvanic corrosion behavior of implant suprastructure dental alloys. *Dental materials: official publication of the Academy of Dental Materials*. 2003; 19 (1): 54–59.
 63. Dr. med. dent. Johann Lechner. *Immunstress durch Zahnmetalle und Elektrosmog*. Raum & Zeit. 1995 (74): 5–13.
 64. Virtanen H, Huttunen J, Toropainen A, Lappalainen R. Interaction of mobile phones with superficial passive metallic implants. *Physics in Medicine and Biology*. 2005; 50 (11): 2689–2700.
 65. Klinghardt D. *Neural Therapy & Mesotherapy Course A: The Intensive Klinghardt Academy*. 2011; 80– 82.
 66. Schütt S, Von Baehr V. Hyperreaktivität von Gewebemakrophagen nach Kontakt mit Titanoxidpartikeln als Ursache einer verstärkten lokalen Entzündungsreaktion bei Patienten mit Periimplantitis. *ZWR - Das Deutsche Zahnärzteblatt*. 2010 (119): 222–232.
 67. Lindhe J, Meyle J. Peri-implant diseases: Consensus Report of the Sixth European Workshop on Periodontology. *Journal of Clinical Periodontology*. 2008; 35 (8 Suppl): 282–285.
 68. Barão VAR, Yoon CJ, Mathew MT, Yuan JC-C, Wu CD, Sukotjo C. Attachment of *Porphyromonas gingivalis* to corroded commercially pure titanium and titanium-aluminum-vanadium alloy. *Journal of periodontology*. 2014; 85 (9): 1275–1282.
 69. Delgado-Ruiz R, Romanos G. Potential Causes of Tita-

- nium Particle and Ion Release in Implant Dentistry: A Systematic Review. *International Journal of Molecular Sciences*. 2018; 19 (11).
70. Safioti LM, Kotsakis GA, Pozhitkov AE, Chung WO, Daubert DM. Increased Levels of Dissolved Titanium Are Associated With Peri-Implantitis - A Cross-Sectional Study. *Journal of periodontology*. 2017; 88 (5): 436-442.
 71. Fretwurst T, Nelson K, Tarnow DP, Wang H-L, Giannobile WV. Is Metal Particle Release Associated with Peri-implant Bone Destruction? An Emerging Concept. *Journal of Dental Research*. 2018; 97 (3): 259-265.
 72. Apaza-Bedoya K, Tarce M, Benfatti CAM, Henriques B, Mathew MT, Teughels W, et al. Synergistic interactions between corrosion and wear at titanium-based dental implant connections: A scoping review. *Journal of periodontal research*. 2017; 52 (6): 946-954.
 73. Senna P, Antoninha Del Bel Cury A, Kates S, Meirelles L. Surface Damage on Dental Implants with Release of Loose Particles after Insertion into Bone. *Clinical implant dentistry and related research*. 2015; 17 (4): 681-692.
 74. Rader CP, Sterner T, Jakob F, Schütze N, Eulert J. Cytokine response of human macrophage-like cells after contact with polyethylene and pure titanium particles. *The Journal of Arthroplasty*. 1999; 14 (7): 840-848.
 75. Olmedo D, Fernández MM, Guglielmotti MB, Cabrini RL. Macrophages related to dental implant failure. *Implant Dentistry*. 2003; 12 (1): 75-80.
 76. Sterner T, Schütze N, Saxler G, Jakob F, Rader CP. Auswirkungen von klinisch relevanten Aluminium Keramik-, Zirkonium Keramik- und Titanpartikel unterschiedlicher Größe und Konzentration auf die TNF alpha-Ausschüttung in einem humanen Makrophagensystem. *Biomedizinische Technik Biomedical engineering*. 2004; 49 (12): 340-344.
 77. Hallab NJ, Jacobs JJ. Biologic effects of implant debris. *Bulletin of the NYU Hospital for Joint Diseases*. 2009; 67 (2): 182-188.
 78. Jacobi-Gresser E. Pathogenese der Periimplantitis. *Dentale Implantologie & Parodontologie* [Internet]. 08.2019. Available at: https://www.dimagazin-aktuell.de/implantologie/periimplantitis/story/pathogenese-der-periimplantitis__6705.html
 79. Lechner J, Noubbissi S, von Baehr V. Titanium implants and silent inflammation in jawbone-a critical interplay of dissolved titanium particles and cytokines TNF- α and RANTES/CCL5 on overall health? *The EPMA Journal*. 2018; 9 (3): 331-343.
 80. Hedenborg M. Titanium dioxide induced chemiluminescence of human polymorphonuclear leukocytes. *International Archives of Occupational and Environmental Health*. 1988; 61 (1): 1-6.
 81. Stejskal VDM, Danersund A, Lindvall A, Hudecek R, Nordman V, Yaqob A, et al. Metal-specific lymphocytes: biomarkers of sensitivity in man. *Neuroendocrinology Letters*. 1999; 20 (5): 289-298.
 82. McGuff HS, Heim-Hall J, Holsinger FC, Jones AA, O'Dell DS, Hafemeister AC. Maxillary osteosarcoma associated with a dental implant: report of a case and review of the literature regarding implant-related sarcomas. *Journal of the American Dental Association* (1939). 2008; 139 (8): 1052-1059.
 83. Poggio CE. Plasmacytoma of the mandible associated with a dental implant failure: a clinical report. *Clinical Oral Implants Research*. 2007; 18 (4): 540-543.
 84. Dib LL, Soares AL, Sandoval RL, Nannmark U. Breast metastasis around dental implants: a case report. *Clinical implant dentistry and related research*. 2007; 9 (2): 112-115.
 85. Weingart D, Steinemann S, Schilli W, Strub JR, Hellerich U, Assenmacher J, et al. Titanium deposition in regional lymph nodes after insertion of titanium screw implants in maxillofacial region. *International Journal of Oral and Maxillofacial Surgery*. 1994; 23 (6): 450-452.
 86. Fujii Y. Sensation of Balance Dysregulation Caused/Aggravated by a Collection of Electromagnetic Waves in a Dental Implant. *Open Journal of Antennas and Propagation*. 2014; 02 (03): 29-35.

BIOLOGICAL DENTISTRY

1. Netter FH. The Ciba collection of medical illustrations: Volume 1 Nervous System Part I Anatomy and physiology. [Éd. variées]. Summit, N.J.: Ciba Pharmaceutical Products; 1959.
2. Miyamoto I, Yoshida K, Tsuboi Y, Iizuka T. Rehabilitation with dental prosthesis can increase cerebral regional blood volume. *Clinical Oral Implants Research*. 2005; 16 (6): 723-727.
3. Fang W-L, Jiang M-J, Gu B-B, Wei Y-M, Fan S-N, Liao W, et al. Tooth loss as a risk factor for dementia: systematic review and metaanalysis of 21 observational studies. *BMC Psychiatry*. 2018; 18 (1): 345.
4. Kato T, Usami T, Noda Y, Hasegawa M, Ueda M, Nabeshima T. The effect of the loss of molar teeth on spatial memory and acetylcholine release from the parietal cortex in aged rats. *Behavioural Brain Research*. 1997; 83 (1-2): 239-242.
5. Alvarenga MOP, Ferreira R de O, Magno MB, Fagundes NCF, Maia LC, Lima RR. Masticatory Dysfunction by Extensive Tooth Loss as a Risk Factor for Cognitive Deficit: A Systematic Review and Meta-Analysis. *Frontiers in physiology*. 2019; 10: 832.
6. Lexomboon D, Trulsson M, Waardh I, Parker MG. Chewing ability and tooth loss: association with cognitive impairment in an elderly population study. *Journal of the American Geriatrics Society*. 2012; 60 (10): 1951-1956.

7. Xie L, Kang H, Xu Q, Chen MJ, Liao Y, Thiyagarajan M, et al. Sleep drives metabolite clearance from the adult brain. *Science (New York, NY)*. 2013; 342 (6156): 373-377.
8. Plog BA, Nedergaard M. The Glymphatic System in Central Nervous System Health and Disease: Past, Present, and Future. *Annual Review of Pathology*. 2018; 13: 379-394.
9. Cardoso EM, Reis C, Manzanares-Céspedes MC. Chronic periodontitis, inflammatory cytokines, and interrelationship with other chronic diseases. *Postgraduate Medicine*. 2018; 130 (1): 98-104.
10. Louhelainen A-M, Aho J, Tuomisto S, Aittoniemi J, Vuento R, Karhunen PJ, et al. Oral bacterial DNA findings in pericardial fluid. *Journal of Oral Microbiology*. 2014; 6: 25835.
11. Macedo Paizan ML, Vilela-Martin JF. Is there an association between periodontitis and hypertension? *Current cardiology reviews*. 2014; 10 (4): 355-361.
12. Ott SJ, El Mokhtari NE, Musfeldt M, Hellmig S, Freitag S, Rehman A, u. a. Detection of diverse bacterial signatures in atherosclerotic lesions of patients with coronary heart disease. *Circulation*. 2006; 113 (7): 929-937.
13. Pessi T, Karhunen V, Karjalainen PP, Ylitalo A, Airaksinen JK, Niemi M, et al. Bacterial signatures in thrombus aspirates of patients with myocardial infarction. *Circulation*. 2013; 127 (11): 1219-28, e1-6.
14. Ichikawa Y, Akagawa Y, Nikai H, Tsuru H. Tissue compatibility and stability of a new zirconia ceramic in vivo. *The Journal of Prosthetic Dentistry*. 1992; 68 (2): 322-326.
15. Price WA. Dental infections and the degenerative diseases [Internet]. *west_virginia_university and americana*; 1923. Available at: <https://ia800307.us.archive.org/16/items/dentalin02pric/dentalin02pric.pdf>
16. Choukroun J, Khoury G, Khoury F, Russe P, Testori T, Komiyama Y, et al. Two neglected biologic risk factors in bone grafting and implantology: high low-density lipoprotein cholesterol and low serum vitamin D. *The Journal of oral implantology*. 2014; 40 (1): 110-114.
17. Bryce G, MacBeth N. Vitamin D deficiency as a suspected causative factor in the failure of an immediately placed dental implant: a case report. *Journal of the Royal Naval Medical Service*. 2014; 100 (3): 328-332.
18. Cooper LF. Systemic effectors of alveolar bone mass and implications in dental therapy. *Periodontology 2000*. 2000; 23: 103-109.
19. Schulze-Späte U, Dietrich T, Wu C, Wang K, Hasturk H, Dibart S. Systemic vitamin D supplementation and local bone formation after maxillary sinus augmentation - a randomized, double-blind, placebo-controlled clinical investigation. *Clin Oral Impl Res*. June 2016; 27(6): 701-6.
20. Kavyashree M, Harish PV, Mishra SK, Chowdhary R. Cell Phone Radiation Effect on Bone-to-Implant Osseointegration: A Preliminary Histologic Evaluation in Rabbits. *The International journal of oral & maxillofacial implants*. 2019; 34 (3): 643-650.
21. Infektionsbiologie. Der septische Schock [Internet]. Available at: http://www.infektionsbiologie.ch/seiten/lernwege/lernweg%20infektionsbiologie%20bakterien/infbakterien_kap4_07.htm
22. Huizen J. What are the side effects of antibiotics? [Internet]. *Medical News Today*, editor. 2018. Available at: <https://www.medicalnewstoday.com/articles/322850.php>
23. Tada A, Miura H. The Relationship between Vitamin C and Periodontal Diseases: A Systematic Review. *Int J Environ Res Public Health*. 11 2019; 16 (14).
24. Stein SH, Livada R, Tipton DA. Re-evaluating the role of vitamin D in the periodontium. *Journal of periodontal research*. 2014; 49 (5): 545-553.
25. Stein SH, Tipton DA. Vitamin D and its impact on oral health—an update. *The Journal of the Tennessee Dental Association*. 2011; 91 (2): 30-3; quiz 34-5.
26. Uwitonze AM, Murererehe J, Ineza MC, Harelimana EI, Nsabimana U, Uwambaye P, et al. Effects of vitamin D status on oral health. *The Journal of steroid biochemistry and molecular biology*. 2018; 175: 190-194.
27. Lee J-H, Shin M-S, Kim E-J, Ahn Y-B, Kim H-D. The association of dietary vitamin C intake with periodontitis among Korean adults: Results from KNHANES. *PLoS one*. 2017;12(5):e0177074.
28. Woelber JP, Bremer K, Vach K, König D, Hellwig E, Ratka-Krüger P, et al. An oral health optimized diet can reduce gingival and periodontal inflammation in humans - a randomized controlled pilot study. *BMC Oral Health*. 2016; 17 (1): 28.
29. adrenal-fatigue.de. Symptome der Nebennierenschwäche [Internet]. Available at: <https://www.adrenal-fatigue.de/>
30. Head KA, Kelly GS. Nutrients and botanicals for treatment of stress: adrenal fatigue, neurotransmitter imbalance, anxiety, and restless sleep. *Alternative medicine review: a journal of clinical therapeutic*. 2009; 14 (2): 114-140.
31. Schlereth T, Birklein F. The sympathetic system is and pain. *Neuromolecular Medicine*. 2008; 10 (3): 141-147.
32. HILOTHERM Clinic + HomeCare. HILOTHERM Clinic + HomeCare. 10-35 °C HILOTHERAPY® zur Vermeidung von Schwellungen, Hämatomen, Entzündungen und Schmerzen [Internet]. Available at: https://www.hilotherm.com/sites/default/files/RZ_HT_Clinic_Broschuere_DE_ANSICHT_1.pdf
33. Xie Z, Chen F, Li WA, Geng X, Li C, Meng X, et al. A review of sleep disorders and melatonin. *Neurological Research*. 2017; 39 (6): 559-565.
34. Peschke E, Bähr I, Mühlbauer E. Melatonin and Panre-

- atic Islets: Interrelationships between Melatonin, Insulin and Glucagon. *International Journal of Molecular Sciences*. 2013; 14 (4): 6981-7015.
35. Zamanian Z, Dehghani M, Hashemi H. Outline of Changes in Cortisol and Melatonin Circadian Rhythms in the Security Guards of Shiraz University of Medical Sciences. *International Journal of Preventive Medicine*. 2013; 4 (7): 825-830.
 36. Bassett SM, Lupis SB, Gianferante D, Rohleder N, Wolf JM. Sleep quality but not sleep quantity effects on cortisol responses to acute psychosocial stress. *Stress (Amsterdam, Netherlands)*. 2015; 18 (6): 638-644.
 37. National Sleep Foundation. How Blue Light Affects Kids & Sleep [Internet]. Available at: <https://www.sleepfoundation.org/articles/how-blue-light-affects-kids-sleep>
 38. Wahl S, Engelhardt M, Schaupp P, Lappe C, Ivanov IV. The inner clock-Blue light sets the human rhythm. *Journal of biophotonics*. 2019; e201900102.
 39. Patrick RP, Ames BN. Vitamin D hormone regulates serotonin synthesis. Part 1: relevance for autism. *FASEB journal : official publication of the Federation of American Societies for Experimental Biology*. 2014; 28 (6): 2398-2413.
 40. Patrick RP, Ames BN. Vitamin D and the omega-3 fatty acids control serotonin synthesis and action, part 2: relevance for ADHD, bipolar disorder, schizophrenia, and impulsive behavior. *FASEB journal : official publication of the Federation of American Societies for Experimental Biology*. 2015; 29 (6): 2207-2222.
 41. Salmon L.: Tired? The vitamins and minerals your body needs to help you sleep better: Not sleeping well is awful, so here are 10 natural remedies that could help you get some shut-eye. [Internet]. 2018. Available at: <http://home.bt.com/lifestyle/health/sleep/tired-the-vitamins-and-minerals-your-body-needs-to-help-you-sleep-better-11364098011805>
- ## IMPORTANCE OF MICRONUTRIENTS IN DENTISTRY
1. Mayer A-M. Historical changes in the mineral content of fruits and vegetables. *British Food Journal*. 1997; 99: 207-211.
 2. Vitamin D – das Sonnenhormon. Vitamin D Lebensmittel: Welche Lebensmittel enthalten Vitamin D? Wie viel Vitamin D sollte man zu sich nehmen? Welche Nahrungsmittel sind die besten Quellen? [Internet]. Available at: <https://www.vitamind.net/lebensmittel/>
 3. Lauer N. *Gesund mit veganer Ernährung*. 2015.
 4. Zittermann A, Gummert JF. Nonclassical vitamin D action. *Nutrients*. 2010; 2 (4): 408-425.
 5. Holick MF. Environmental factors that influence the cutaneous production of vitamin D. *The American journal of clinical nutrition*. 1995; 61 (3 Suppl): 638S-645S.
 6. MacLaughlin J, Holick MF. Aging decreases the capacity of human skin to produce vitamin D3. *The Journal of clinical investigation*. 1985; 76 (4): 1536-1538.
 7. Vitamin D – das Sonnenhormon. Vitamin D und Sonne: Vitamin D und Sonne: Sonnenlicht ist die wichtigste Vitamin-D-Quelle. Das Vitamin wird durch Sonne in der Haut gebildet. Wieviel Sonne ist dafür nötig? [Internet]. Available at: <https://www.vitamind.net/sonne/>
 8. Gröber U. *Mikronährstoffe: Metabolic Tuning - Prävention - Therapie; mit 134 Tabellen*. Third fully revised and enlarged edition, Stuttgart: Wiss. Verl.-Ges; 2011. (Für die Kitteltasche).
 9. Cheng S, Massaro JM, Fox CS, Larson MG, Keyes MJ, McCabe EL, et al. Adiposity, cardiometabolic risk, and vitamin D status: the Framingham Heart Study. *Diabetes*. 2010; 59 (1): 242-248.
 10. Savastano S, Barrea L, Savanelli MC, Nappi F, Di Somma C, Orio F, et al. Low vitamin D status and obesity: Role of nutritionist. *Reviews in Endocrine and Metabolic Disorders*. 2017; 18 (2): 215-225.
 11. Vimalaswaran KS, Berry DJ, Lu C, Tikkanen E, Pilz S, Hiraki LT, et al. Causal relationship between obesity and vitamin D status: bi-directional Mendelian randomization analysis of multiple cohorts. *PLoS medicine*. 2013; 10 (2): e1001383.
 12. Wacker M, Holick MF. Sunlight and Vitamin D: A global perspective for health. *Dermato-Endocrinology*. January 2013; 5 (1): 51-108.
 13. Webb AR, Kline L, Holick MF. Influence of season and latitude on the cutaneous synthesis of vitamin D3: exposure to winter sunlight in Boston and Edmonton will not promote vitamin D3 synthesis in human skin. *The Journal of Clinical Endocrinology and Metabolism*. 1988; 67 (2): 373-378.
 14. Chen T, Lu Z, Holick M. Photobiology of Vitamin D. In: *Vitamin D: Physiology, Molecular Biology, and Clinical Applications*. 2010. p. 35-60.
 15. Chapuy MC, Preziosi P, Maamer M, Arnaud S, Galan P, Hercberg S, et al. Prevalence of vitamin D insufficiency in an adult normal population. *Osteoporosis international : a journal established as result of cooperation between the European Foundation for Osteoporosis and the National Osteoporosis Foundation of the USA*. 1997; 7 (5): 439-443.
 16. van Schoor NM, Lips P. Worldwide vitamin D status. *Best practice & research Clinical endocrinology & metabolism*. 2011; 25 (4): 671-680.
 17. Vitamin D Grenzwerte des Vitamins. Available at: https://www.focus.de/gesundheit/ernaehrung/gesundessen/tid-17499/vitamin-d-grenzwerte-des-vitamins_aid_488149.html
 18. Ghanaati S, Choukroun J, Volz U, Hueber R, Mourão C de AB, Sader R, et al. One hundred years after Vitamin

- D discovery: Is there clinical evidence for supplementation doses? *Int J Growth Factors Stem Cells Dent.* 2020; 3 (1): 3.
19. Vitamin D – das Sonnenhormon. Vitamin D Stoffwechsel: Vitamin D Stoffwechsel: So verwertet der Körper Vitamin D. Vitamin-D-Synthese in der Haut, Umwandlung in die aktiven Formen und Regulation des Vitamin-D-Hormons [Internet]. Available at: <https://www.vitamind.net/vitamin-d3/stoffwechsel/>
 20. Khundmiri SJ, Murray RD, Lederer E. PTH and Vitamin D. *Comprehensive Physiology.* 2016; 6 (2): 561-601.
 21. Rassow J. *Biochemie: 50 tables.* Second updated edition, Stuttgart. Thieme; 2008. (dual series).
 22. Nakamichi Y, Udagawa N, Horibe K, Mizoguchi T, Yamamoto Y, Nakamura T, et al. VDR in Osteoblast-Lineage Cells Primarily Mediates Vitamin D Treatment-Induced Increase in Bone Mass by Suppressing Bone Resorption: VITAMIN D TREATMENT INCREASES BONE MASS VIA OSTEOBLAST-LINEAGE VDR. *J Bone Miner Res.* JUNE 2017; 32 (6): 1297-308.
 23. Driel van M, Pols H, van Leeuwen JP. Osteoblast Differentiation and Control by Vitamin D and Vitamin D Metabolites. *CPD.* August 01, 2004; 10 (21): 2535-55.
 24. Goltzman D. Functions of vitamin D in bone. *Histochem Cell Biol.* April 2018; 149 (4): 305-12.
 25. Bons PD, Bauer CC, Bocherens H, de Riese T, Drucker DG, Francken M, et al. Out of Africa by spontaneous migration waves. Ayub Q, publisher. *PLoS ONE.* April 23, 2019; 14(4): e0201998.
 26. Vitamin D – das Sonnenhormon. Vitamin D – Heilmittel für MS und Autoimmunerkrankungen? Interview mit Dr Coimbra über hochdosiertes Vitamin D für multiple Sklerose und andere Autoimmunerkrankungen: Das Coimbra Protokoll. Erfolgsquote 95 Prozent. [Internet]. Available at: <https://www.vitamind.net/interviews/coimbra-ms-autoimmun/>
 27. Smolders J, Damoiseaux J, Menheere P, Hupperts R. Vitamin D as an immune modulator in multiple sclerosis, a review. *Journal of Neuroimmunology.* 2008; 194 (1-2): 7-17.
 28. Hiremath VP, Rao CB, Naik V, Prasad KV. Anti-inflammatory effect of vitamin D on gingivitis: a dose-response randomised control trial. *Oral health & preventive dentistry.* 2013; 11 (1): 61-69.
 29. Chen Y, Zhang J, Ge X, Du J, Deb DK, Li YC. Vitamin D receptor inhibits nuclear factor κ B activation by interacting with κ kinase protein. *The Journal of Biological Chemistry.* 2013; 288 (27): 19450-19458.
 30. Cohen-Lahav M, Shany S, Tobvin D, Chaimovitz C, Douvdevani A. Vitamin D decreases NF κ B activity by increasing κ levels. *Nephrology, dialysis, transplantation: official publication of the European Dialysis and Transplant Association – European Renal Association.* 2006; 21 (4): 889-897.
 31. Muscogiuri G, Barrea L, Scannapieco M, Di Somma C, Scacchi M, Aimaretti G, et al. The lullaby of the sun: the role of vitamin D in sleep disturbance. *Sleep Medicine.* Februar 2019; 54: 262-5.
 32. Romano F, Muscogiuri G, Di Benedetto E, Zhukouskaya VV, Barrea L, Savastano S, et al. Vitamin D and Sleep Regulation: Is there a Role for Vitamin D? *CPD.* June 24, 2020; 26 (21): 2492-6.
 33. Gominak SC, Stumpf WE. The world epidemic of sleep disorders is linked to vitamin D deficiency. *Medical Hypotheses.* August 2012; 79 (2): 132-5.
 34. Azrielant S, Shoenfeld Y. Vitamin D and the Immune System. *The Israel Medical Association journal: IMAJ.* 2017; 19 (8): 510-511.
 35. Tabatabaeizadeh S-A, Tafazoli N, Ferns GA, Avan A, Ghayour-Mobarhan M. Vitamin D, the gut microbiome and inflammatory bowel disease. *Journal of Research in Medical Sciences: The Official Journal of Isfahan University of Medical Sciences.* 2018; 23.
 36. Kočovská E, Gaughran F, Krivoy A, Meier U-C. Vitamin D Deficiency As a Potential Environmental Risk Factor in Multiple Sclerosis, Schizophrenia, and Autism. *Frontiers in Psychiatry.* 2017; 8:47 AM.
 37. Berry DJ, Hesketh K, Power C, Hyppönen E. Vitamin D status has a linear association with seasonal infections and lung function in British adults. *The British Journal of Nutrition.* 2011; 106 (9): 1433-1440.
 38. CANNELL JJ, VIETH R, UMHAU JC, HOLICK MF, GRANT WB, MADRONICH S, et al. Epidemic influenza and vitamin D. *Epidemiology and Infection.* 2006; 134 (6): 1129-1140.
 39. Holick MF. Vitamin D: A millenium perspective. *Journal of cellular biochemistry.* 2003; 88 (2): 296-307.
 40. Gombart AF. The vitamin D-antimicrobial peptide pathway and its role in protection against infection. *Future Microbiology.* 2009; 4 (9): 1151-1165.
 41. Miznerova E, Hlavaty T, Koller T, Toth J, Holociova K, Huorka M, et al. The prevalence and risk factors for osteoporosis in patients with inflammatory bowel disease. *Bratislavske lekarske listy.* 2013; 114 (8): 439-445.
 42. Jagelavičienė E, Vaitkevičienė I, Šilingaitė D, Šinkūnaitė E, Daugėlaitė G. The Relationship between Vitamin D and Periodontal Pathology. *Medicina (Kaunas, Lithuania).* 2018; 54 (3).
 43. Stein SH, Tipton DA. Vitamin D and its impact on oral health—an update. *The Journal of the Tennessee Dental Association.* 2011; 91 (2): 30-3; quiz 34-5.
 44. Muscogiuri G, Annweiler C, Duval G, Karras S, Tirabassi G, Salvio G, et al. Vitamin D and cardiovascular disease: From atherosclerosis to myocardial infarction and stroke. *International Journal of Cardiology.* March 2017; 230: 577-84.
 45. Berridge MJ. Vitamin D deficiency: Infertility and neu-

- rodevelopmental diseases (attention deficit hyperactivity disorder, autism, and schizophrenia). *American journal of physiology, Cell physiology*. 2018; 314 (2): C135-51.
46. Ganmaa D, Stuart JJ, Sumberzul N, Ninjin B, Giovannucci E, Kleinman K, et al. Vitamin D supplementation and growth in urban Mongol schoolchildren: Results from two randomized clinical trials. *PloS one*. 2017;12(5):e0175237.
 47. Gao Q, Kou T, Zhuang B, Ren Y, Dong X, Wang Q. The Association between Vitamin D Deficiency and Sleep Disorders: A Systematic Review and Meta-Analysis. *Nutrients*. 2018; 10 (10).
 48. Chiang C-M, Ismaeel A, Griffis RB, Weems S. Effects of Vitamin D Supplementation on Muscle Strength in Athletes: A Systematic Review. *Journal of strength and conditioning research*. 2017; 31 (2): 566-574.
 49. Parker GB, Brotchie H, Graham RK. Vitamin D and Depression. *Journal of affective disorders*. 2017; 208: 56-61.
 50. Bischoff-Ferrari HA, Willett WC, Wong JB, Giovannucci E, Dietrich T, Dawson-Hughes B. Fracture prevention with vitamin D supplementation: a meta-analysis of randomized controlled trials. *JAMA*. 2005; 293 (18): 2257-2264.
 51. Lindqvist PG, Epstein E, Nielsen K, Landin-Olsson M, Ingvar C, Olsson H. Avoidance of sun exposure as a risk factor for major causes of death: a competing risk analysis of the Melanoma in Southern Sweden cohort. *Journal of Internal Medicine*. 2016; 280 (4): 375-387.
 52. Al Mheid I, Patel R, Murrow J, Morris A, Rahman A, Fike L, et al. Vitamin D status is associated with arterial stiffness and vascular dysfunction in healthy humans. *Journal of the American College of Cardiology*. 2011; 58 (2): 186-192.
 53. Anderson JL, May HT, Horne BD, Bair TL, Hall NL, Carlquist JF, et al. Relation of vitamin D deficiency to cardiovascular risk factors, disease status, and incident events in a general healthcare population. *The American Journal of Cardiology*. 2010; 106 (7): 963-968.
 54. Chowdhury R, Kunutsor S, Vitezova A, Oliver-Williams C, Chowdhury S, Kiefte-de-Jong JC, et al. Vitamin D and risk of cause specific death: systematic review and meta-analysis of observational cohort and randomised intervention studies. *BMJ (Clinical research ed)*. 2014; 348: g1903.
 55. Forman JP, Giovannucci E, Holmes MD, Bischoff HA, Tworoger SS, Willett WC, et al. Plasma 25 D levels and risk of incident hypertension. *Hypertension (Dallas, Tex : 1979)*. 2007; 49 (5): 1063-1069.
 56. Roy S, Sherman A, Monari-Sparks MJ, Schweiker O, Hunter K. Correction of Low Vitamin D Improves Fatigue: Effect of Correction of Low Vitamin D in Fatigue Study (EVIDiF Study). *North American journal of medical sciences*. 2014; 6 (8): 396-402.
 57. Zhou R, Wang M, Huang H, Li W, Hu Y, Wu T. Lower Vitamin D Status Is Associated with an Increased Risk of Ischemic Stroke: A Systematic Review and Meta-Analysis. *Nutrients*. 2018; 10 (3).
 58. Beard JA, Bearden A, Striker R. Vitamin D and the anti-viral state. *Journal of Clinical Virology*. March 2011; 50 (3): 194-200.
 59. Urashima M, Segawa T, Okazaki M, Kurihara M, Wada Y, Ida H. Randomized trial of vitamin D supplementation to prevent seasonal influenza A in schoolchildren. *The American Journal of Clinical Nutrition*. May 01, 2010; 91 (5): 1255-60.
 60. Grant WB, Lahore H, McDonnell SL, Baggerly CA, French CB, Aliano JL, et al. Evidence that Vitamin D Supplementation Could Reduce Risk of Influenza and COVID-19 Infections and Deaths. *Nutrients*. April 2, 2020; 12 (4): 988.
 61. Maghbooli Z, Sahraian MA, Ebrahimi M, Pazoki M, Kafan S, Tabriz HM, et al. Vitamin D sufficiency, a serum 25 COVID-19 D at least 30 ng/mL reduced risk for adverse clinical outcomes in patients with COVID-19 infection. Adrish M, publisher. *PLoS ONE*. September 25, 2020; 15(9): e0239799.
 62. Grant WB, Giovannucci E. The possible roles of solar ultraviolet-B radiation and vitamin D in reducing case-fatality rates from the 1918-1919 influenza pandemic in the United States. *Dermato-Endocrinology*. July 2009; 1(4): 215-9.
 63. Lang PO, Samaras D. Aging Adults and Seasonal Influenza: Does the Vitamin D Status (H)Arm the Body? *Journal of Aging Research*. 2012; 2012: 1-8.
 64. Sundaram ME, Coleman LA. Vitamin D and Influenza. *Advances in Nutrition*. July 01, 2012; 3 (4): 517-25.
 65. Xu J, Yang J, Chen J, Luo Q, Zhang Q, Zhang H. Vitamin D alleviates lipopolysaccharide-induced acute lung injury via regulation of the renin-angiotensin system. *Molecular Medicine Reports*. May 2017; 16 (5): 7432- 8.
 66. Hoogendijk WJG, Lips P, Dik MG, Deeg DJH, Beekman ATF, Penninx BWJH. Depression Is Associated With Decreased 25-Hydroxyvitamin D and Increased Parathyroid Hormone Levels in Older Adults. *Arch Gen Psychiatry*. May 1, 2008; 65 (5): 508.
 67. Lee DM, Tajar A, O'Neill TW, O'Connor DB, Bartfai G, Boonen S, et al. Lower vitamin D levels are associated with depression among community European men. *J Psychopharmacol*. October 2011; 25 (10): 1320-8.
 68. Maalmi H, Ordóñez-Mena JM, Schöttker B, Brenner H. Serum 25-hydroxyvitamin D levels and survival in colorectal and breast cancer patients: Systematic review and meta-analysis of prospective cohort studies. *European Journal of Cancer*. May 2014; 50 (8): 1510- 21.
 69. Shanafelt TD, Drake MT, Maurer MJ, Allmer C, Rabe KG, Slager SL, et al. Vitamin D insufficiency and prog-

- nosis in chronic lymphocytic leukemia. *Blood*. February 03, 2011; 117 (5): 1492-8.
70. Lee HJ, Muindi JR, Tan W, Hu Q, Wang D, Liu S, et al. Low 25(OH) vitamin D \AA levels are associated with adverse outcome in newly diagnosed, intensively treated adult acute myeloid leukemia: Acute Myeloid Leukemia and Vitamin D. *Cancer*. February 15, 2014; 120 (4): 521-9.
 71. Bittenbring JT, Neumann F, Altmann B, Achenbach M, Reichrath J, Ziepert M, et al. Vitamin D Deficiency Impairs Rituximab-Mediated Cellular Cytotoxicity and Outcome of Patients With Diffuse Large B-Cell Lymphoma Treated With but Not Without Rituximab. *JCO*. October 10, 2014; 32 (29): 3242-8.
 72. Ng K, Nimeiri HS, McCleary NJ, Abrams TA, Yurgelun MB, Cleary JM, et al. Effect of High-Dose vs Standard-Dose Vitamin D \AA Supplementation on Progression-Free Survival Among Patients With Advanced or Metastatic Colorectal Cancer: The SUNSHINE randomized Clinical Trial. *JAMA*. April 9, 2019; 321 (14): 1370.
 73. Borchmann S, Cirillo M, Goergen H, Meder L, Sasse S, Kreissl S, et al. Pretreatment Vitamin D Deficiency Is Associated With Impaired Progression-Free and Overall Survival in Hodgkin Lymphoma. *Journal of Clinical Oncology*. 2019; JCO.19.00985.
 74. Wu X, Hu W, Lu L, Zhao Y, Zhou Y, Xiao Z, et al. Repurposing vitamin D for treatment of human malignancies via targeting tumor microenvironment. *Acta pharmaceutica Sinica B*. 2019; 9 (2): 203-219.
 75. Grassroots Health Nutrient Research Institute. Lower Disease Incidence with Vitamin D levels 40-60 ng/ml [Internet]. Available at: <https://www.grassrootshealth.net/project/general-health/>
 76. Barker T, Henriksen V, Martins T, Hill H, Kjeldsberg C, Schneider E, et al. Higher Serum 25-Hydroxyvitamin D Concentrations Associate with a Faster Recovery of Skeletal Muscle Strength after Muscular Injury. *Nutrients*. April 17, 2013; 5 (4): 1253-75.
 77. Jastrzębski Z. EFFECT OF VITAMIN D SUPPLEMENTATION ON THE LEVEL OF PHYSICAL FITNESS AND BLOOD PARAMETERS OF ROWERS DURING THE 8-WEEK HIGH INTENSITY TRAINING. In 2015.
 78. Kaul A, Gläser S, Hannemann A, Schäper C, Nauck M, Felix SB, et al. Vitamin D is associated with cardiopulmonary exercise capacity: results of two independent cohorts of healthy adults. *Br J Nutr*. February 14, 2016; 115 (3): 500-8.
 79. Koundourakis NE, Androulakis NE, Malliaraki N, Margioris AN. Vitamin D and Exercise Performance in Professional Soccer Players. Heimesaat MM, editor. *PLoS ONE*. July 03, 2014; 9(7): e101659.
 80. de la Puente Yagüe M, Collado Yurrita L, Ciudad Cabañas MJ, Cuadrado Cenzual MA. Role of Vitamin D in Athletes and Their Performance: Current Concepts and New Trends. *Nutrients*. February 23, 2020; 12 (2): 579.
 81. Woelber JP, Bremer K, Vach K, König D, Hellwig E, Ratka-Krüger P, et al. An oral health optimized diet can reduce gingival and periodontal inflammation in humans - a randomized controlled pilot study. *BMC Oral Health*. 2016; 17 (1): 28.
 82. Teles FR, Teles RP, Martin L, Socransky SS, Haffajee AD. Relationships among interleukin-6, tumor necrosis factor- \AA , adipokines, vitamin D, and chronic periodontitis. *Journal of periodontology*. 2012; 83 (9): 1183-1191.
 83. Kim I-J, Lee H-S, Ju H-J, Na J-Y, Oh H-W. A cross-sectional study on the association between vitamin D levels and caries in the permanent dentition of Korean children. *BMC Oral Health*. Dezember 2018; 18(1): 43.
 84. Schroth RJ, Rabbani R, Loewen G, Moffatt ME. Vitamin D and Dental Caries in Children. *J Dent Res*. Februar 2016; 95 (2): 173-9.
 85. Kühnisch J, Thiering E, Kratzsch J, Heinrich-Weltzien R, Hickel R, Heinrich J, et al. Elevated Serum 25(OH)-Vitamin D Levels Are Negatively Correlated with Molar-Incisor Hypomineralization. *J Dent Res*. Februar 2015; 94 (2): 381-7.
 86. Bhargava A, Rastogi P, Lal N, Singhal R, Khatoon S, Ali Mahdi A. Relationship between VITAMIN D and chronic periodontitis. *Journal of Oral Biology and Craniofacial Research*. April 2019; 9 (2): 177-9.
 87. Meghil MM, Hutchens L, Raed A, Multani NA, Rajendran M, Zhu H, et al. The influence of vitamin D supplementation on local and systemic Marker in periodontitis patients: A pilot study. *Oral Dis*. July 2019; 25(5): 1403-13.
 88. Nørrisgaard PE, Haubek D, Kühnisch J, Chawes BL, Stokholm J, Bønnelykke K, et al. Association of High-Dose Vitamin D Supplementation During Pregnancy With the Risk of Enamel Defects in Offspring: A 6-Year Follow-up of a Randomized Clinical Trial. *JAMA Pediatr*. October 1, 2019; 173 (10): 924.
 89. Zhan Y, Samietz S, Holtfreter B, Hannemann A, Meisel P, Nauck M, et al. Prospective Study of Serum 25-hydroxy Vitamin D and Tooth Loss. *Journal of dental research*. 2014; 93 (7): 639-644.
 90. Grenier D, Morin M-P, Fournier-Larente J, Chen H. Vitamin D inhibits the growth of and virulence factor gene expression by *Porphyromonas gingivalis* and blocks activation of the nuclear factor kappa B transcription factor in monocytes. *J Periodont Res*. Juni 2016; 51(3): 359-65.
 91. McMahon L, Schwartz K, Yilmaz O, Brown E, Ryan LK, Diamond G. Vitamin D-Mediated Induction of Innate Immunity in Gingival Epithelial Cells. Bäumlér AJ, editor. *Infect Immun*. June 2011; 79 (6): 2250-6.
 92. Schulze-Späte U, Dietrich T, Wu C, Wang K, Hasturk H,

- Dibart S. Systemic vitamin D supplementation and local bone formation after maxillary sinus augmentation - a randomized, double-blind, placebo-controlled clinical investigation. *Clin Oral Impl Res.* June 2016; 27(6): 701-6.
93. Choukroun J, Khoury G, Khoury F, Russe P, Testori T, Komiyama Y, et al. Two neglected biologic risk factors in bone grafting and implantology: high low-density lipoprotein cholesterol and low serum vitamin D. *The Journal of oral implantology.* 2014; 40 (1): 110-114.
94. Bryce G, MacBeth N. Vitamin D deficiency as a suspected causative factor in the failure of an immediately placed dental implant: a case report. *Journal of the Royal Naval Medical Service.* 2014; 100 (3): 328-332.
95. Cooper LF. Systemic effectors of alveolar bone mass and implications in dental therapy. *Periodontology 2000.* 2000; 23: 103-109.
96. zm-online. Wie der Zahnarzt einen Vitamin D deficiency diagnostiziert: Auch der Zahnarzt kann einen Vitamin Mangel diagnostizieren. Und zwar mithilfe einer einfachen Röntgenaufnahme, wie kanadische Anthropologen jetzt herausgefunden haben. [Internet]. 2018. Available at: <https://www.zm-online.de/news/zahnmedizin/wie-der-zahnarzt-einen-vitamin-d-mangel-diagnostiziert>
97. Giustina A, Adler RA, Binkley N, Bollerslev J, Bouillon R, Dawson-Hughes B, et al. Consensus statement from 2nd International Conference on Controversies in Vitamin D. *Rev Endocr Metab Disord.* March 2020; 21 (1): 89-116.
98. Deutsche Gesellschaft für Ernährung e.V. Vitamin D (Calciferol) [Internet]. Available at: <https://www.dge.de/wissenschaft/referenzwerte/vitamin-d/>
99. Papadimitriou DT. The Big Vitamin D Mistake. *Journal of preventive medicine and public health = Yebang Uihakhoe chi.* 2017; 50 (4): 278-281.
100. Veugelers PJ, Ekwaru JP. A statistical error in the estimation of the recommended dietary allowance for vitamin D. *Nutrients.* 2014; 6 (10): 4472-4475.
101. Zentrum der Gesundheit. Tagesbedarf für Vitamin D: Ein Rechenfehler [Internet]. 2019. Available at: <https://www.zentrum-der-gesundheit.de/tagesbedarf-vitamin-d-ia.html>
102. Heaney Robert P. The IOM Miscalculated Its RDA For Vitamin D [Internet]. 2015. Available at: <http://blogs.creighton.edu/heaney/2015/02/13/the-iom-miscalculated-its-rda-for-vitamin-d/>
103. Wagner CL, Hollis BW. The Implications of Vitamin D Status During Pregnancy on Mother and her Developing Child. *Frontiers in Endocrinology.* 2018; 9: 500.
104. van Ballegooijen AJ, Pilz S, Tomaschitz A, Gröbler MR, Verheyen N. The Synergistic Interplay between Vitamins D and K for Bone and Cardiovascular Health: A Narrative Review. *International Journal of Endocrinology.* 2017; 2017: 1-12.
105. Risco F, Traba ML. Possible involvement of a magnesium dependent mitochondrial alkaline phosphatase in the regulation of the 25-hydroxyvitamin D₃-1 alpha and 25-hydroxyvitamin D₃-24R-hydroxylases in LLC-PK1 cells. *Magnesium research.* 1994; 7 (3-4): 169-178.
106. Risco F, Traba ML. Influence of magnesium on the in vitro synthesis of 24,25-dihydroxyvitamin D₃ and 1 alpha, 25-dihydroxyvitamin D₃. *Magnesium research.* 1992; 5 (1): 5-14.
107. Zittermann A. Magnesium deficit ? overlooked cause of low vitamin D status? *BMC Medicine.* 2013; 11: 229.
108. Zofková I, Kancheva RL. The relationship between magnesium and calciotropic hormones. *Magnesium research.* 1995; 8 (1): 77-84.
109. Dean C (2017): Magnesium. OMNS.
110. Sánchez-Martínez R, Castillo AI, Steinmeyer A, Aranda A. The retinoid X receptor ligand restores defective signalling by the vitamin D receptor. *EMBO Reports.* 2006; 7 (10): 1030-1034.
111. Johansson S, Melhus H. Vitamin A antagonizes calcium response to vitamin D in man. *Journal of bone and mineral research: the official journal of the American Society for Bone and Mineral Research.* 2001; 16 (10): 1899-1905.
112. Gröber U, Kisters K, Wissenschaftliche Verlagsgesellschaft Stuttgart. Corona, Influenza & Co. wie stärken ich mein Immunsystem? 2020.
113. Freedman L TTL. DNA Binding Properties of the Vitamin D₃ Receptor Zinc Finger Region. *Molecular Endocrinology.* 1991 (Vol 5 No.12): 1815-1826.
114. Plourde E. Sunscreens-biohazard: Treat as hazardous waste. Irvine, CA: New Voice Publications; 2012.
115. Allison D. Sunscreen causes cancer, not the sun! [Internet]. 2019. Available at: <https://awarenessact.com/sunscreen-causes-cancer-not-the-sun/>
116. Lin W, Xu Y, Huang C-C, Ma Y, Shannon K, Chen D-R. Toxicity of nano- and micro-sized ZnO particles in human lung epithelial cells. *Journal of Nanoparticle Research.* 2008; 11: 25-39.
117. Mayr-kuren.de. Die Sonne: Genuß und Schutz [Internet]. Available at: <https://www.mayr-kuren.de/sonne-sonnenschutz.html#sonnencreme>
118. DiNardo JC, Downs CA. Dermatological and environmental toxicological impact of the sunscreen ingredient oxybenzone/benzophenone-3. *Journal of cosmetic dermatology.* 2018; 17 (1): 15-19.
119. Schneider SL, Lim HW. Review of environmental effects of oxybenzone and other sunscreen active ingredients. *Journal of the American Academy of Dermatology.* 2019; 80 (1): 266-271.
120. The Guardian. Hawaii becomes first US state to ban sunscreens harmful to coral reefs [Internet]. 2018.

- Available at: <https://www.theguardian.com/travel/2018/may/03/hawaii-becomes-first-us-state-to-ban-sunscreens-harmful-to-coral-reefs>
121. Raffa RB, Pergolizzi JV, Taylor R, Kitzen JM. Sunscreen bans: Coral reefs and skin cancer. *Journal of clinical pharmacy and therapeutics*. 2019; 44 (1): 134-139.
 122. Siller A, Blaszkak SC, Lazar M, Olasz Harken E. Update About the Effects of the Sunscreen Ingredients Oxybenzone and Octinoxate on Humans and the Environment. *Plastic surgical nursing: official journal of the American Society of Plastic and Reconstructive Surgical Nurses*. 2018; 38 (4): 158-161.
 123. Chris Masterjohn. On the Trail of the Elusive X A Sixty-Two-Year-Old Mystery Finally Solved. Available at: http://www.cdahealing.com/uploads/3/7/2/0/37201993/k2_and_activator_x_-_weston_price_1.pdf
 124. Neue Erkenntnisse zu Vitamin K2 (Teil 1). Available at: <https://www.schallers-gesundheitsbriefe.de/archiv-der-gesundheitsbriefe/archiv-12/neue-erkenntnisse-zu-vitamin-k2-teil-1/>
 125. Geleijnse JM, Vermeer C, Grobbee DE, Schurgers LJ, Knapen MHJ, van der Meer IM, et al. Dietary Intake of Menaquinone Is Associated with a Reduced Risk of Coronary Heart Disease: The Rotterdam Study. *The Journal of Nutrition*. November 01, 2004; 134 (11): 3100-5.
 126. van Ballegooijen AJ, Beulens JW. The Role of Vitamin K Status in Cardiovascular Health: Evidence from Observational and Clinical Studies. *Curr Nutr Rep*. September 2017; 6 (3): 197-205.
 127. Knapen MHJ, Drummen NE, Smit E, Vermeer C, Theuwissen E. Three-year low-dose menaquinone-7 supplementation helps decrease bone loss in healthy postmenopausal women. *Osteoporos Int*. September 2013; 24 (9): 2499-507.
 128. Iwamoto J, Takeda T, Sato Y. Effects of Vitamin K2 on Osteoporosis. *CPD*. August 01, 2004; 10 (21): 2557-76.
 129. Kurnatowska I, Grzelak P, Masajtis-Zagajewska A, Kaczmarska M, Stefańczyk L, Vermeer C, et al. Effect of vitamin K2 on progression of atherosclerosis and vascular calcification in nondialyzed patients with chronic kidney disease stages 3-5. *Polish Archives of Internal Medicine*. July 15, 2015; 125 (9): 631-40.
 130. Schurgers LJ, Cranenburg ECM, Vermeer C. Matrix Gla-protein: the calcification inhibitor in need of vitamin K. *Thromb Haemost*. October 2008; 100 (4): 593-603.
 131. Gast GCM, de Roos NM, Sluijs I, Bots ML, Beulens JWJ, Geleijnse JM, et al. A high menaquinone intake reduces the incidence of coronary heart disease. *Nutrition, Metabolism and Cardiovascular Diseases*. September 2009; 19 (7): 504-10.
 132. Denisova NA, Booth SL. Vitamin K and Sphingolipid Metabolism: Evidence to Date. *Nutrition Reviews*. April 2005; 63 (4): 111-21.
 133. Setoguchi S, Watase D, Matsunaga K, Yamakawa H, Goto S, Terada K, et al. Antitumor Effects and Delivery Profiles of Menahydroquinone-4 Prodrugs with Ionic or Nonionic Promoiety to Hepatocellular Carcinoma Cells. *Molecules*. July 16, 2018; 23 (7): 1738.
 134. Li Y, Chen J peng, Duan L, Li S. Effect of vitamin K2 on type 2 diabetes mellitus: A review. *Diabetes Research and Clinical Practice*. Februar 2018; 136: 39-51.
 135. Patti A, Gennari L, Merlotti D, Dotta F, Nuti R. Endocrine Actions of Osteocalcin. *International Journal of Endocrinology*. 2013; 2013: 1-10.
 136. Southward K. A hypothetical role for vitamin K2 in the endocrine and exocrine aspects of dental caries. *Medical Hypotheses*. March 2015; 84 (3): 276-80.
 137. DGE. Available at: <https://www.dge.de/wissenschaft/referenzwerte/vitamin-k/>
 138. VitaminExpress. Vitamin K2 - natürlicher Schutz für Knochen und Arterien [Internet]. 2019. Available at: <https://www.vitaminexpress.org/de/vitamin-k2#toc-vitamin-k2-uberdosierung>
 139. Aponet.de. Die Top 5 der Vitamin-C-Bomben [Internet]. Available at: <https://www.aponet.de/wissen/gesunde-ernaehrung-und-sport/vitamine-mineralien-und-spuren/vitamine-im-ueberblick/vitamin-c-bomben.html>
 140. Chakraborty A, Ramani P, Sherlin H, Premkumar P, Natesan A. Antioxidant and pro Vitamin C in oral environment. *Indian J Dent Res*. 2014; 25(4): 499.
 141. Padayatty SJ, Katz A, Wang Y, Eck P, Kwon O, Lee J-H, et al. Vitamin C as an Antioxidant: Evaluation of Its Role in Disease Prevention. *Journal of the American College of Nutrition*. February 2003; 22 (1): 18-35.
 142. Choi H, Kim G-J, Yoo H-S, Song D, Chung K-H, Lee K-J, et al. Vitamin C Activates Osteoblastogenesis and Inhibits Osteoclastogenesis via Wnt/ β -Catenin/ATF4 Signaling Pathways. *Nutrients*. February 27, 2019; 11 (3): 506.
 143. Chin K-Y, Ima-Nirwana S. Vitamin C and Bone Health: Evidence from Cell, Animal and Human Studies. *CDT*. March 19, 2018; 19 (5): 439-50.
 144. Aghajanian P, Hall S, Wongworawat MD, Mohan S. The Roles and Mechanisms of Actions of Vitamin C in Bone: New Developments: ROLES AND MECHANISMS OF VITAMIN C IN BONE. *J Bone Miner Res*. November 2015; 30 (11): 1945-55.
 145. Haines DD, Varga B, Bak I, Juhasz B, Mahmoud FF, Kalantari H, et al. Summative interaction between astaxanthin, Ginkgo biloba extract (EGb761) and vitamin C in Suppression of respiratory inflammation": PHYTOCHEMICALS COOPERATIVELY SUPPRESS INFLAMMATION. *Phytother Res*. January 2011; 25 (1): 128-36.

146. Boyera N, Galey I, Bernard BA. Effect of vitamin C and its derivatives on collagen synthesis and cross by normal human fibroblasts. *Int J Cosmet Sci.* June 1998; 20 (3): 151-8.
147. Carr A, Maggini S. Vitamin C and Immune Function. *Nutrients.* November 3, 2017; 9 (11): 1211.
148. Li X, Tang L, Lin YF, Xie GF. Role of vitamin C in wound healing after dental implant surgery in patients treated with bone grafts and patients with chronic periodontitis. *Clin Implant Dent Relat Res.* October 2018; 20 (5): 793-8.
149. Wintergerst ES, Maggini S, Hornig DH. Immune-Enhancing Role of Vitamin C and Zinc and Effect on Clinical Conditions. *Ann Nutr Metab.* 2006; 50 (2): 85-94.
150. Tada A, Miura H. The Relationship between Vitamin C and Periodontal Diseases: A Systematic Review. *Int J Environ Res Public Health.* 11 2019; 16 (14).
151. Carpenter KJ. The Discovery of Vitamin C. *Ann Nutr Metab.* 2012; 61 (3): 259-64.
152. Hemilä H. Vitamin C and Infections. *Nutrients.* March 29, 2017; 9 (4): 339.
153. Kim TK, Lim HR, Byun JS. Vitamin C supplementation reduces the odds of developing a common cold in Republic of Korea Army recruits: randomised controlled trial. *BMJ Mil Health.* March 5, 2020; bmjmilitary-2019-001384.
154. Gorton HC, Jarvis K. The effectiveness of vitamin C in preventing and relieving the symptoms of virus-induced respiratory infections. *Journal of Manipulative and Physiological Therapeutics.* October 1999; 22 (8): 530-3.
155. Saul, Andrew W. VITAMIN C AND ITS APPLICATION TO THE TREATMENT OF nCoV CORONAVIRUS How Vitamin C Reduces Severity and Deaths from Serious Diseases Orthomolecular Medicine News Service. February 10, 2020;
156. Gander and Niederberger. Vitamin C in the handling of pneumonia. *Munch Med Wchnschr.* 31: 2074. 1936.
157. Hochwald A. Beobachtungen über Ascorbinsäurewirkung bei der krupposen Pneumonie. *Vienna, Archive for int. med.,* 353, 1936.
158. Deutsche Gesellschaft für Ernährung e.V. Vitamin C: Empfohlene Zufuhr. Available at: <https://www.dge.de/wissenschaft/referenzwerte/vitamin-c/>
159. DGOM e.V. Was bewirkt Ascorbin in unserem Körper? Available at: <https://www.dgom.de/22-inhalte/naehrstoffe/170-vitamin-c>
160. 58. Wehner-V. Segesser Sibylle. Der Trick mit dem Vitamin C [Internet]. 2008. Available at: https://www.nzz.ch/der_trick_mit_dem_vitamin_c-1.694995
161. Cameron E, Pauling L. Supplemental ascorbate in the supportive treatment of cancer: Prolongation of survival times in terminal human cancer. *Proceedings of the National Academy of Sciences.* October 01, 1976; 73 (10): 3685-9.
162. Commentary by Thomas E. Levy, MD, JD. Vitamin C and Cortisol Synergistic Infection and Toxin Defense. *Orthomolecular.org* [Internet]. Available at: <http://orthomolecular.org/resources/omns/v17n28.shtml>
163. Uwitonze AM, Rahman S, Ojeh N, Grant WB, Kaur H, Haq A, et al. Oral manifestations of magnesium and vitamin inadequacy. *The Journal of steroid biochemistry and molecular biology.* June 2020; 200: 105636.
164. Gröber U. *Orthomolekulare Medizin: ein Leitfaden für Apotheker und Ärzte ; mit 75 Tabellen.* Third unchanged edition, Stuttgart: Wiss. Verl.-Ges; 2008. 337 p.
165. <https://fachkreis.norsan.de/fachwissen/Omega-3-fettsauren/>
166. Hashim AF, Hamed SF, Abdel Hamid HA, Abd-El-salam KA, Golonka I, Musiał W, et al. Antioxidant and antibacterial activities of omega-3 rich oils/curcumin nanoemulsions loaded in chitosan and alginate-based microbeads. *Int J Biol Macromol.* November 1, 2019; 140: 682- 96.
167. Azuma MM, Cardoso C de BM, da Silva CC, de Oliveira PHC, Jacinto R de C, Andrada AC, et al. The use of omega-3 fatty acids in the treatment of oral diseases. *Oral Dis.* October 06, 2020;
168. Nicolai E, Sinibaldi F, Sannino G, Laganà G, Basoli F, Licoccia S, et al. Omega-3 and Omega-6 Fatty Acids Act as Inhibitors of the Matrix Metalloproteinase-2 and Matrix Metalloproteinase-9 Activity. *protein J.* August 2017; 36 (4): 278-85.
169. Chatterjee D, Chatterjee A, Kalra D, Kapoor A, Vijay S, Jain S. Role of adjunct use of omega 3 fatty acids in periodontal therapy of periodontitis. A Systematic Review and Meta-Analysis. *J Oral Biol Craniofac Res.* February 2022;12 (1): 55-62.
170. Gröber U. *COVID-19 und Long-COVID: Bessere Resilienz durch Mikronährstoffe: mit 47 Abbildungen und 5 Tabellen.* First edition Stuttgart: Wissenschaftliche Verlagsgesellschaft; 2021. 167 p.
171. Gröber U. *Mikronährstoffe: Metabolic Tuning, Prävention, Therapie.* Third fully revised and enlarged edition, Stuttgart: Wissenschaftliche Verlagsgesellschaft; 2011. 622 S. (Für die Kitteltasche).
172. Uwitonze AM, Rahman S, Ojeh N, Grant WB, Kaur H, Haq A, et al. Oral manifestations of magnesium and vitamin inadequacy. *The Journal of steroid biochemistry and molecular biology.* June 2020; 200: 105636.
173. Gerkin RC et al. The best COVID-19 predictor is recent smell loss: a cross-sectional study. July 28, 2020 [Internet]. Available at: <https://doi.org/10.1101/2020.07.22.20157263>
174. Hopkins C, Alanin M, Philpott C, Harries P, Whitcroft K, Qureishi A, et al. Management of new onset loss of sense of smell during the COVID-19 pandemic - BRS

- Consensus Guidelines. *Clin Otolaryngol*. September 24, 2020; coa.13636.
175. Jones BG, Oshansky CM, Bajracharya R, Tang L, Sun Y, Wong SS, et al. Retinol binding protein and vitamin D associations with serum antibody isotypes, serum influenza virus-specific neutralizing activities and airway cytokine profiles: Vitamins, IgA, antibody isotype and cytokine patterns in humans. *Clin Exp Immunol*. February 2016; 183 (2): 239–47.
 176. Grassroothealth <https://www.grassroothealth.net/wp-content/uploads/2017/01/disease-incidence-prev-chart-051317-web.png>
- ## RESTORATION
1. Mutter J. *Gesund statt chronisch krank!: Der ganzheitliche Weg: Vorbeugung und Heilung sind möglich*. 3. Edition. Weil der Stadt: Fit fürs Leben publisher; 2014.
 2. Mutter J., Klinghardt D. *Amalgam: Risiko für die Menschheit; Quecksilbervergiftungen richtig ausleiten, neue Fakten und Hilfe, auch nach der Amalgamentfernung! third revised and enlarged edition, [reprint]*. Weil der Stadt: Fit-fürs-Leben publisher. In *NaturaViva-Verl.-GmbH*; 2013. (health).
 3. Warwick D, Young M, Palmer J, Ermel RW. Mercury vapor volatilization from particulate generated from dental amalgam removal with a high-speed dental drill – a significant source of exposure. *Journal of Occupational Medicine and Toxicology*. 2019; 14 (1): 22.
 4. Wang X, Ge L. Influence of feeding patterns on the development of teeth, dentition and jaw in children. *Beijing da xue xue bao Yi xue ban = Journal of Peking University Health sciences*. 2015; 47 (1): 191–195.
 5. Lechner J. Validation of dental X-ray by cytokine RANTES - comparison of X-ray findings with cytokine overexpression in jawbone. *Clinical, Cosmetic and Investigational Dentistry*. 2014; 6: 71–79.
 6. Lechner J, von Baehr V. RANTES and fibroblast growth factor 2 in jawbone cavitations: triggers for systemic disease? *International journal of general medicine*. 2013; 6: 277–290.
 7. Arend WP. The balance between IL-1 and IL-1Ra in disease. *Cytokine & growth factor reviews*. 2002; 13 (4–5): 323–340.
 8. Lechner J, Bouquot JE, Baehr V von. *Histologie und Immunologie der kavitätenbildenden Osteolysen des Kieferknochens: Orale und systematische Manifestation einer Maxillo-Mandibulären Osteoimmunologie; pathomechanismen chronischer Entzündungserkrankungen*. 1. edition, Munich Independent publisher; 2015. (Kavitätenbildende Osteolysen des Kieferknochens; Bd. / J. Lechner; 2).
 9. Bouquot JE, Roberts AM, Person P, Christian J. NEURALGIA-inducing cavitational osteonecrosis (NICO). Osteomyelitis in 224 jawbone samples from patients with facial neuralgia. *Oral surgery, oral medicine, and oral pathology*. 1992; 73 (3): 307–19; discussion 319–20.
 10. Lechner J, von Baehr V. Chemokine RANTES/CCL5 as an unknown link between wound healing in the jawbone and systemic disease: is prediction and tailored treatments in the horizon? *The EPMA Journal*. 2015; 6 (1): 10.
 11. Lechner J, Rudi T, von Baehr V. Osteoimmunology of tumor necrosis factor-alpha, IL-6, and RANTES/CCL5: a review of known and poorly understood inflammatory patterns in osteonecrosis. *Clinical, Cosmetic and Investigational Dentistry*. 2018; 10: 251–262.
 12. Lechner J, von Baehr V. Hyperactivated Signaling Pathways of Chemokine RANTES/CCL5 in Osteopathies of Jawbone in Breast Cancer Patients-Case Report and Research. *Breast cancer: basic and clinical research*. 2014; 8: 89–96.
 13. Azenshtein E, Luboshits G, Shina S, Neumark E, Shahbazian D, Weil M, et al. The CC chemokine RANTES in breast carcinoma progression: regulation of expression and potential mechanisms of promalignant activity. *Cancer Research*. 2002; 62 (4): 1093–1102.
 14. von Luettichau I, Nelson PJ, Pattison JM, van de Rijn M, Huie P, Warnke R, et al. RANTES chemokine expression in diseased and normal human tissues. *Cytokine*. 1996; 8 (1): 89–98.
 15. Rentzos M, Nikolaou C, Rombos A, Boufidou F, Zoga M, Dimitrakopoulos A, et al. RANTES levels are elevated in serum and cerebrospinal fluid in patients with amyotrophic lateral sclerosis. *Amyotrophic lateral sclerosis: official publication of the World Federation of Neurology Research Group on Motor Neuron Diseases*. 2007; 8 (5): 283–287.
 16. Singh SK, Mishra MK, Eltoum I-EA, Bae S, Lillard JW, Singh R. CCR5/CCL5 axis interaction promotes migratory and invasiveness of pancreatic cancer cells. *Scientific Reports*. 2018; 8 (1): 1323.
 17. An G, Wu F, Huang S, Feng L, Bai J, Gu S, et al. Effects of CCL5 on the biological behavior of breast cancer and the mechanisms of its interaction with tumor-associated macrophages. *Oncology Reports*. 2019; 42 (6): 2499–2511.
 18. Bischoff SC, Krieger M, Brunner T, Rot A, von Tschanner V, Baggolini M, et al. RANTES and related chemokines activate human basophil granulocytes through different G protein-coupled receptors. *European Journal of Cancer*. 1993; 23 (3): 761–767.
 19. Stübinger S, Stricker A, Berg B-I. Piezosurgery in implant dentistry. *Clinical, Cosmetic and Investigational Dentistry*. 2015; 7: 115–124.
 20. Grauvogel J, Scheiwe C, Kaminsky J. Use of piezo-surgery for internal auditory canal drilling in acoustic neuroma surgery. *Acta Neurochirurgica*. 2011; 153 (10): 1941–7; discussion 1947.

21. Crosetti E, Battiston B, Succo G. Piezosurgery in head and neck oncological and reconstructive surgery: personal experience on 127 cases. *Acta otorhinolaryngologica Italica: organo ufficiale della Societa italiana di otorinolaringologia e chirurgia cervico-facciale*. 2009; 29 (1): 1-9.
22. Spinelli G, Mannelli G, Zhang YX, Lazzeri D, Spacca B, Genitori L, et al. Complex craniofacial advancement in paediatric patients: Piezoelectric and traditional technique evaluation. *Journal of Cranio-Maxillo-Facial Surgery: official publication of the European Association for Cranio-Maxillo-Facial Surgery*. 2015; 43 (8): 1422-1427.
23. Brisman DL, Brisman AS, Moses MS. Implant failures associated with asymptomatic endodontically treated teeth. *Journal of the American Dental Association (1939)*. 2001; 132 (2): 191-195.
24. DentaTec. Ozontherapie beim Zahnarzt - Nutzen und Anwendungsmöglichkeiten [Internet]. Available at: <https://denta-tec.com/ozontherapie-zahnarzt-nutzen-anwendungsmoeglichkeiten>
25. bti® human technology. bti® human technology. Endoret® (prgf®) Technology [Internet]. Available at: <http://bti-biotechnologyinstitute.com/regenerative-medicine/>
26. Anitua E, Prado R, Troya M, Zalduendo M, La Fuente M de, Pino A, Muruzabal F, Orive G. Implementation of a more physiological plasma rich in growth factor (PRGF) protocol: Anticoagulant removal and reduction in activator concentration. *Platelets*. 2016; 27 (5): 459-466.
27. Anitua E. Plasma rich in growth factors: preliminary results of use in the preparation of future sites for implants. *The International journal of oral & maxillofacial implants*. 1999; 14 (4): 529-535.
28. Kobayashi E, Flückiger L, Fujioka-Kobayashi M, Sawada K, Sculean A, Schaller B, et al. Comparative release of growth factors from PRP, PRF, and advanced-PRF. *Clinical Oral Investigations*. 2016; 20 (9): 2353-2360.
29. Ghanaati S, Booms P, Orlowska A, Kubesch A, Lorenz J, Rutkowski J, et al. Advanced platelet-rich fibrin: a new concept for cell-based tissue engineering by means of inflammatory cells. *The Journal of oral implantology*. 2014; 40 (6): 679-689.
30. Miron RJ, Zucchelli G, Pikos MA, Salama M, Lee S, Guillemette V, et al. Use of platelet-rich fibrin in regenerative dentistry: a systematic review. *Clinical Oral Investigations*. 2017; 21 (6): 1913-1927.
31. Wang X, Zhang Y, Choukroun J, Ghanaati S, Miron RJ. Effects of an injectable platelet-rich fibrin on osteoblast behavior and bone tissue formation in comparison to platelet-rich plasma. *Platelets*. January 02, 2018; 29 (1): 48-55.
32. Miron RJ, Fujioka-Kobayashi M, Hernandez M, Kandalam U, Zhang Y, Ghanaati S, et al. Injectable platelet-rich fibrin (i-PRF): opportunities in regenerative dentistry? *Clinical Oral Investigations*. 2017; 21 (8): 2619-2627.
33. Ghanaati S, Mourão C, Adam E, Sader R, Zadeh H, Al-Maawi S. The role of centrifugation process in the preparation of therapeutic blood concentrates: Standardization of the protocols to improve reproducibility. *Int J Growth Factors Stem Cells Dent*. 2019; 2 (3): 41.
34. Hisbergues M, Vendeville S, Vendeville P. Zirconia: Established facts and perspectives for a biomaterial in dental implantology. *Journal of biomedical materials research Part B, Applied biomaterials*. 2009; 88 (2): 519-529.
35. Fischer J, Benic G, Fischer Carolin. Zirkoniumdioxidimplantate - wieso, weshalb, warum [Internet]. ZMK Zahnheilkunde Management Kultur, editor. 2016. Available at: https://www.zmk-aktuell.de/fachgebiete/implantologie/story/Zirkoniumdioxidimplantate-wieso-weshalb-warum__4830.html
36. Sivaraman K, Chopra A, Narayan AI, Balakrishnan D. Is zirconia a viable alternative to titanium for oral implant? A critical review. *Journal of prosthodontic research*. 2018; 62 (2): 121-133.
37. Manzano G, Herrero LR, Montero J. Comparison of clinical performance of zirconia implants and titanium implants in animal models: a systematic review. *The International journal of oral & maxillofacial implants*. 2014; 29 (2): 311-320.
38. Özkurt Z, Kazazoğlu E. Zirconia dental implants: a literature review. *The Journal of oral implantology*. 2011; 37 (3): 367-376.
39. Payer M, Heschl A, Koller M, Arnetzl G, Lorenzoni M, Jakse N. All-ceramic restoration of zirconia two-piece implants—a randomized controlled clinical trial. *Clinical Oral Implants Research*. 2015; 26 (4): 371-376.
40. Möller B, Terheyden H, Açil Y, Purcz NM, Hertrampf K, Tabakov A, et al. A comparison of biocompatibility and osseointegration of ceramic and titanium implants: an in vivo and in vitro study. *International Journal of Oral and Maxillofacial Surgery*. 2012; 41 (5): 638-645.
41. Koch FP, Weng D, Krämer S, Biesterfeld S, Jahn-Eimermacher A, Wagner W. Osseointegration of one-piece zirconia implants compared with a titanium implant of identical design: a histomorphometric study in the dog. *Clinical Oral Implants Research*. 2010; 21 (3): 350-356.
42. Kohal RJ, Weng D, Bächle M, Strub JR. Loaded custom-made zirconia and titanium implants show similar osseointegration: an animal experiment. *Journal of periodontology*. 2004; 75 (9): 1262-1268.
43. Roehling S, Schlegel KA, Woelfler H, Gahlert M. Zirconia compared to titanium dental implants in preclinical studies—A systematic review and meta-analysis. *Clinical Oral Implants Research*. 2019; 30 (5): 365-395.

44. Bormann K-H, Gellrich N-C, Kniha H, Schild S, Weingart D, Gahlert M. A prospective clinical study to evaluate the performance of zirconium dioxide dental implants in single-tooth edentulous area: 3-year follow-up. *BMC Oral Health*. 2018; 18 (1): 181.
45. Hashim D, Cionca N, Courvoisier DS, Mombelli A. A systematic review of the clinical survival of zirconia implants. *Clinical Oral Investigations*. 2016; 20: 1403-1417.
46. Roehling S, Schlegel KA, Woelfler H, Gahlert M. Performance and outcome of zirconia dental implants in clinical studies: A meta-analysis. *Clinical Oral Implants Research*. 2018; 29 Suppl 16: 135-153.
47. Oliva J, Oliva X, Oliva JD. Five-year success rate of 831 consecutively placed Zirconia dental implants in humans: a comparison of three different rough surfaces. *The International journal of oral & maxillofacial implants*. 2010; 25 (2): 336-344.
48. Roehling S, Gahlert M, Janner S, Meng B, Woelfler H, Cochran DL. Ligature-Induced Peri-implant Bone Loss Around Loaded Zirconia and Titanium Implants. *The International journal of oral & maxillofacial implants*. 2019; 34 (2): 357-365.
49. Janner SFM, Gahlert M, Bosshardt DD, Roehling S, Milz S, Higginbottom F, et al. Bone response to functionally loaded, two-piece zirconia implants: A preclinical histometric study. *Clinical Oral Implants Research*. 2018; 29 (3): 277-289.
50. Mueller CK, Solcher P, Peisker A, Mtsariashvilli M, Schlegel KA, Hildebrand G, et al. Analysis of the influence of the macro- and microstructure of dental zirconium implants on osseointegration: a minipig study. *Oral Surgery, Oral Medicine, Oral Pathology and Oral Radiology*. 2013; 116 (1): e1-8.
51. Bormann K-H, Gellrich N-C, Kniha H, Dard M, Wieland M, Gahlert M. Biomechanical evaluation of a microstructured zirconia implant by a removal torque comparison with a standard Ti-SLA implant. *Clinical Oral Implants Research*. 2012; 23 (10): 1210-1216.
52. Mellinghoff. Qualität des periimplantären Weichgewebeattachments von Zirkondioxid-Implantaten (Abutments): Vergleich der Ergebnisse einer Literaturrecherche mit den Erfahrungen aus der eigenen Praxis. *Deutscher Ärzte Verlag zzi Z Zahnärztl Impl*. 2010(26 (1)): 8-17.
53. Roehling S, Astasov-Frauenhoffer M, Hauser-Gerspach I, Braissant O, Woelfler H, Waltimo T, et al. In Vitro Biofilm Formation on Titanium and Zirconia Implant Surfaces. *Journal of periodontology*. 2017; 88 (3): 298-307.
54. Holländer J, Lorenz J, Stübinger S, Hölscher W, Heidemann D, Ghanaati S, et al. Zirconia Dental Implants: Investigation of Clinical Parameters, Patient Satisfaction, and Microbial Contamination. *The International journal of oral & maxillofacial implants*. 2016; 31 (4): 855-864.
55. Cionca N, Hashim D, Mombelli A. Zirconia dental implants: where are we now, and where are we heading? *Periodontology 2000*. 2017; 73 (1): 241-258.
56. Kajiwara N, Masaki C, Mukaibo T, Kondo Y, Nakamoto T, Hosokawa R. Soft tissue biological response to zirconia and metal implant abutments compared with natural tooth: microcirculation monitoring as a novel bioindicator. *Implant Dentistry*. 2015; 24 (1): 37-41.
57. Rimondini L, Cerroni L, Carrassi A, Torricelli P. Bacterial colonization of zirconia ceramic surfaces: an in vitro and in vivo study. *The International journal of oral & maxillofacial implants*. 2002; 17 (6): 793-798.
58. Scarano A, Piattelli M, Caputi S, Favero GA, Piattelli A. Bacterial adhesion on commercially pure titanium and zirconium oxide disks: an in vivo human study. *Journal of periodontology*. 2004; 75 (2): 292-296.
59. Nascimento C do, Pita MS, Fernandes FHNC, Pedrazzi V, de Albuquerque Junior RF, Ribeiro RF. Bacterial adhesion on the titanium and zirconia abutment surfaces. *Clinical Oral Implants Research*. 2014; 25 (3): 337-343.
60. Schlömer GH, Volz U, Sidharta JS, Haase St.: Klinische Nachuntersuchung von Zirkondioxidkeramik-Implantaten - Funktion als Kalzium-Kathode. Dissertation, Ulm university;2006. 2006
61. Apratim A, Eachempati P, Krishnappa Salian KK, Singh V, Chhabra S, Shah S. Zirconia in dental implantology: A review. *Journal of International Society of Preventive & Community Dentistry*. 2015; 5 (3): 147-156.
62. chemie.de. Zirconiumdioxid [Internet]. Available at: <https://www.chemie.de/lexikon/Zirconiumdioxid.html>
63. Roos-Jansaker A-M, Lindahl C, Renvert H, Renvert S. Nine- to fourteen-year follow-up of implant treatment. Part II: presence of peri-implant lesions. *J Clin Periodontol*. April 2006; 33 (4): 290-5.
64. Lorenz J, Giuliani N, Hölscher W, Schwiertz A, Schwarz F, Sader R. Prospective controlled clinical study investigating long-term clinical parameters, patient satisfaction, and microbial contamination of zirconia implants. *Clin Implant Dent Relat Res*. April 2019; 21(2): 263-71.
65. Delgado-Ruiz R, Romanos G. Potential Causes of Titanium Particle and Ion Release in Implant Dentistry: A Systematic Review. *International Journal of Molecular Sciences*. 2018; 19 (11).
66. Safioti LM, Kotsakis GA, Pozhitkov AE, Chung WO, Daubert DM. Increased Levels of Dissolved Titanium Are Associated With Peri-Implantitis - A Cross-Sectional Study. *Journal of periodontology*. 2017; 88 (5): 436-442.
67. Apaza-Bedoya K, Tarce M, Benfatti CAM, Henriques B, Mathew MT, Teughels W, et al. Synergistic interactions between corrosion and wear at titanium-based dental

- implant connections: A scoping review. *Journal of periodontal research*. 2017; 52 (6): 946–954.
68. Lechner J, Noumbissi S, von Baehr V. Titanium implants and silent inflammation in jawbone—a critical interplay of dissolved titanium particles and cytokines TNF- α and RANTES/CCL5 on overall health? *The EPMA Journal*. 2018; 9 (3): 331–343.
 69. Berryman Z, Bridger L, Hussaini HM, Rich AM, Atieh M, Tawse-Smith A. Titanium particles: An emerging risk factor for peri-implant bone loss. *The Saudi Dental Journal*. 2019.
 70. Mombelli A, Hashim D, Cionca N. What is the impact of titanium particles and biocorrosion on implant survival and complications? A critical review. *Clinical Oral Implants Research*. 2018; 29 Suppl 18:37–53.
 71. Barão VAR, Yoon CJ, Mathew MT, Yuan JC-C, Wu CD, Sukotjo C. Attachment of *Porphyromonas gingivalis* to corroded commercially pure titanium and titanium-aluminum-vanadium alloy. *Journal of periodontology*. 2014; 85 (9): 1275–1282.
 72. Degidi M, Artese L, Scarano A, Perrotti V, Gehrke P, Piattelli A. Inflammatory infiltrate, microvessel density, nitric oxide synthase expression, vascular endothelial growth factor expression, and proliferative activity in peri-implant soft tissues around titanium and zirconium oxide healing caps. *Journal of periodontology*. 2006; 77 (1): 73–80.
 73. Cosgarea R, Gasparik C, Dudea D, Culic B, Dannewitz B, Sculean A. Peri-implant soft tissue colour around titanium and zirconia abutments: a prospective randomized controlled clinical study. *Clinical Oral Implants Research*. 2015; 26 (5): 537–544.
 74. Beekmans DG. The pink and white aesthetics of a new zirconia implant. *Nederlands Tijdschrift voor Tandheelkunde*. 2018; 125: 389–395.
 75. Jum'ah A, Beekmans B, Wood D, Maghaireh H. Zirconia Implants: The New Arrival in the Armoury of Successful Aesthetic Implant Dentistry. *Smile Dental Journal*. 2012; 7: 12–26.
 76. Hempel U, Hefti T, Kalbacova M, Wolf-Brandstetter C, Dieter P, Schlottig F. Response of osteoblast-like SAOS-2 cells to zirconia ceramics with different surface topographies. *Clinical Oral Implants Research*. 2010; 21 (2): 174–181.
 77. Kniha H, Kniha K, Milz S, Hicklin S, Brägger U, Gahler M. Full ceramic monotype implants: papilla formation and retrospective clinical and radiographic 1-year results in the aesthetic zone. *Clinical Oral Implants Research*. 2014 (25 (Suppl.10)).
 78. Schwenzer N. *Zahnärztliche Chirurgie*. Fourth fully revised and enlarged edition, Stuttgart: Thieme; 2009. (Zahn-Mund-Kiefer-Heilkunde).
 79. Thoma DS, Lim H-C, Paeng K-W, Jung U-W, Hämmerle CHF, Jung RE. Tissue integration of zirconia and titanium implants with and without buccal dehiscence defects—A histologic and radiographic preclinical study. *Clinical Oral Implants Research*. 2019; 30 (7): 660–669.
 80. Giulini, Nino; Hölscher, Werner; Schwiertz, Andreas; Schwarz, Frank; Lorenz, Jonas; Sader, Robert. Studie zum Langzeitverhalten von Keramik-Implantaten. February 19, 2020; Available at: <https://www.zwp-online.info/fachgebiete/implantologie/Keramik-Implantate/prospektive-studie-zum-langzeitverhalten-von-Keramik-Implantaten>
 81. Neuhöffer, Leon; Smeets, Ralf: Erfolg von dentalen Keramik-Implantaten und Patientenzufriedenheit nach Sofortimplantation. Hamburg University Dissertation [Internet]. 2017. Available at: <https://ediss.sub.uni-hamburg.de/bitstream/ediss/7379/1/Dissertation.pdf>
 82. Cardaropoli G, Araújo M, Lindhe J. Dynamics of bone tissue formation in tooth extraction sites: An experimental study in dogs. *Journal of Clinical Periodontology*. September 2003;30 (9): 809–18.
 83. Stocchero M, Jinno Y, Toia M, Ahmad M, Papia E, Yamaguchi S, et al. Intraosseous Temperature Change during Installation of Dental Implants with Two Different Surfaces and Different Drilling Protocols: An In Vivo Study in Sheep. *Journal of Clinical Medicine*. 2019; 8 (8).
 84. Berglundh T, Abrahamsson I, Lang NP, Lindhe J. De novo alveolar bone formation adjacent to endosseous implants. *Clinical Oral Implants Research*. 2003; 14 (3): 251–262.
 85. Coelho PG, Suzuki M, Marin C, Granato R, Gil LF, Tovar N, et al. Osseointegration of Plateau Root Form Implants: Unique Healing Pathway Leading to Haversian-Like Long-Term Morphology. *Advances in Experimental Medicine and Biology*. 2015; 881: 111–128.
 86. Leonard G, Coelho P, Polyzois I, Stassen L, Claffey N. A study of the bone healing kinetics of plateau versus screw root design titanium dental implants. *Clinical Oral Implants Research*. 2009; 20 (3): 232–239.
 87. Lemons JE. Biomaterials, biomechanics, tissue healing, and immediate-function dental implants. *The Journal of oral implantology*. 2004; 30 (5): 318–324.
 88. Lemons JE. Biocompatibility of implant materials. Proceedings of the 3rd Annual Indiana Conference, Indiana School of Dentistry, Medical Education Resource Program, Indianapolis, IN79–89. 2002.
 89. Komet. Angle Modulation System. zur minimalinvasiven Verbreiterung des Alveolarkamms nach Dr. Ernst Fuchs Schaller [Internet]. 2014. Available at: https://www.zwp-online.info/files/32520/410092v1_bro_de_angle-modulation.pdf
 90. Pommer B, Unger E, Sütö D, Hack N, Watzek G. Mechanical properties of the Schneiderian membrane in vitro. *Clinical Oral Implants Research*. 2009; 20 (6):

- 633-637.
91. Pérez-Martínez S, Martorell-Calatayud L, Peñarrocha-Oltra D, García-Mira B, Peñarrocha-Diago M. Indirect sinus lift without bone graft material: Systematic review and meta-analysis. *Journal of Clinical and Experimental Dentistry*. 2015; 7 (2): e316-9.
 92. Cricchio G, Palma VC, Faria PEP, de Olivera JA, Lundgren S, Sennerby L, et al. Histological outcomes on the development of new space-making devices for maxillary sinus floor augmentation. *Clinical implant dentistry and related research*. 2011; 13 (3): 224-230.
 93. Mammoto A, Connor KM, Mammoto T, Yung CW, Huh D, Aderman CM, et al. A mechanosensitive transcriptional mechanism that controls angiogenesis. *Nature*. 2009; 457 (7233): 1103-1108.
 94. Palma VC, Magro-Filho O, de Oliveria JA, Lundgren S, Salata LA, Sennerby L. Bone reformation and implant integration following maxillary sinus membrane elevation: an experimental study in primates. *Clinical implant dentistry and related research*. 2006; 8 (1): 11-24.
 95. Srouji S, Ben-David D, Lotan R, Riminucci M, Livne E, Bianco P. The innate osteogenic potential of the maxillary sinus (Schneiderian) membrane: an ectopic tissue transplant model simulating sinus lifting. *International Journal of Oral and Maxillofacial Surgery*. 2010; 39 (8): 793-801.
 96. Srouji S, Kizhner T, Ben David D, Riminucci M, Bianco P, Livne E. The Schneiderian membrane contains osteoprogenitor cells: in vivo and in vitro study. *Calcified Tissue International*. 2009; 84 (2): 138-145.
 97. Al-Maawi S, Herrera-Vizcaíno C, Orłowska A, Willershausen I, Sader R, Miron RJ, et al. Biologization of Collagen-Based Biomaterials Using Liquid-Platelet-Rich Fibrin: New Insights into Clinically Applicable Tissue Engineering. *Materials (Basel)*. December 02, 2019; 12(23): E3993.
 98. Al-Maawi S, Dohle E, Lim J, Weigl P, Teoh SH, Sader R, et al. Biologization of Pcl-Mesh Using Platelet Rich Fibrin (Prf) Enhances Its Regenerative Potential In Vitro. *Int J Mol Sci*. February 22, 2021; 22 (4): 2159.
 99. ADA American Dental Association. Floss and peri-implantitis risk [Internet]. 2017. Available at: https://www.ada.org/en/publications/jada/jada-specialty-scans/prosthodontics/prosthodontics_042817
 100. Woelber JP, Bremer K, Vach K, König D, Hellwig E, Ratka-Krüger P, et al. An oral health optimized diet can reduce gingival and periodontal inflammation in humans - a randomized controlled pilot study. *BMC Oral Health*. 2016; 17 (1): 28.
 101. Miyamoto I, Yoshida K, Tsuboi Y, Iizuka T. Rehabilitation with dental prosthesis can increase cerebral regional blood volume. *Clinical Oral Implants Research*. 2005; 16 (6): 723-727.
 102. Hasegawa Y, Ono T, Hori K, Nokubi T. Influence of human jaw movement on cerebral blood flow. *Journal of Dental Research*. 2007; 86 (1): 64-68.

SWISS BIOHEALTH

©SWISS BIOHEALTH AG
Brückenstrasse 15 | 8280 Kreuzlingen | Switzerland

Hotline +41 71 678 2000
reception@swiss-biohealth.com
www.swiss-biohealth.com

Third Edition

Copyright:
Any copying or reproduction of THE SWISS BIOHEALTH CONCEPT—even in part—without the explicit and prior written permission of SWISS BIOHEALTH AG is prohibited.